

THE ADVERSE EFFECTS OF ORTHODONTIC TREATMENT

By

William F. Holt and Judith B. Rose

From

Riolo, M. and Avery, J. Eds., *Essentials for Orthodontic Practice*,
EFOP Press of EFOP, LLC, Ann Arbor and Grand Haven,
Michigan, U.S.A., 2003.

CHAPTER 22
Pages 617-632

The Adverse Effects of Orthodontic Treatment

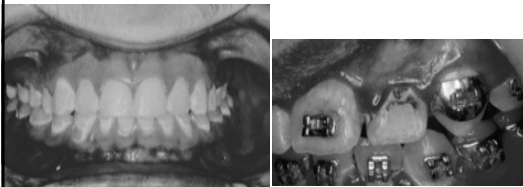
Introduction

The Adverse Effects of Orthodontic Treatment

- Tooth Decay and Enamel Decalcification
- Periodontal Disease
- External Apical Root Resorption (EARR)
- Patient Injuries from Orthodontic Appliances
- Length of Treatment may vary from Estimate
- Temporomandibular Joint Disorders may Occur
- Aspiration or Ingestion of Orthodontic Appliances
- Injury from Dental Instruments
- Abnormal Wear of Tooth Structure and Debonding Fractures
- Nickel Allergy
- Bacteremia after Orthodontic Banding
- Pain and Discomfort
- Impacted Teeth 3rd Molars may Still Occur
- Tooth Mass Discrepancies may not be Resolved
- Extraction of Teeth and Supplemental Orthognathic Surgery may be Necessary
- Abnormal Growth Patterns of the Jaws
- Teeth with Questionable Vitality may be Adversely Affected
- Post Treatment Changes in Alignment

The Adverse Effects of Orthodontic Treatment

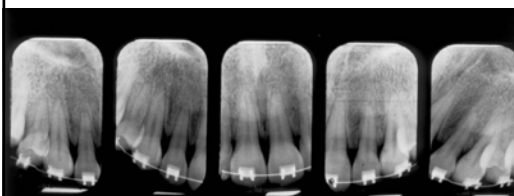
Tooth Decay and Enamel Decalcification



Decalcification and tooth decay associated with poor oral hygiene during orthodontic treatment

The Adverse Effects of Orthodontic Treatment

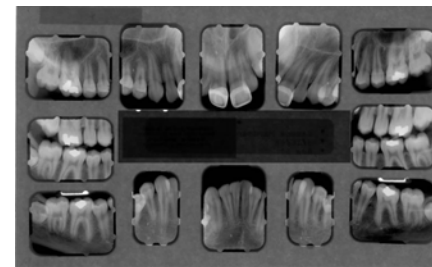
Periodontal Disease



Crestal bone loss occurring with orthodontic treatment associated with poor oral hygiene

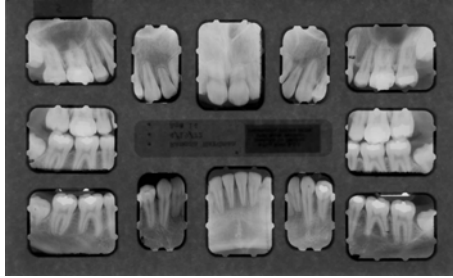
The Adverse Effects of Orthodontic Treatment

External Apical Root Resorption (EARR)



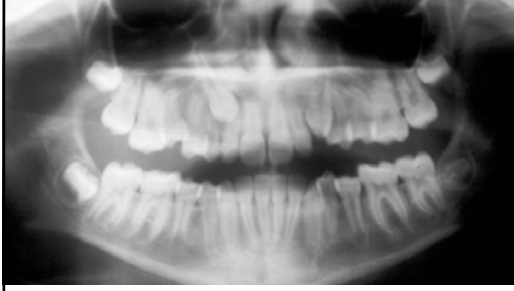Pre-orthodontic treatment full-mouth radiographs

The Adverse Effects of Orthodontic Treatment
External Apical Root Resorption (EARR)



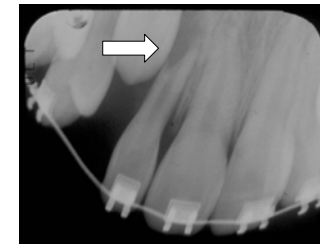
Post-orthodontic treatment full-mouth radiographs demonstrating EARR of incisors

The Adverse Effects of Orthodontic Treatment
External Apical Root Resorption (EARR)




Impacted maxillary canine in close proximity to lateral incisor apex

The Adverse Effects of Orthodontic Treatment
External Apical Root Resorption (EARR)



Resorption of the lateral incisor apex by the impacted maxillary canine

The Adverse Effects of Orthodontic Treatment
Patient Injuries from Orthodontic Appliances



Safety release mechanisms on head gear attachment

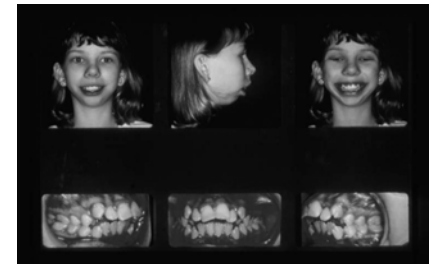J-hook headgear

The Adverse Effects of Orthodontic Treatment

- Length of Treatment may vary from Estimate
- Temporomandibular Joint Disorders may Occur
- Aspiration or Ingestion of Orthodontic Appliances
- Injury from Dental Instruments
- Abnormal Wear of Tooth Structure and Debonding Fractures
- Nickel Allergy
- Bacteremia after Orthodontic Banding
- Pain and Discomfort
- Impacted Teeth 3rd Molars may Still Occur
- Tooth Mass Discrepancies may not be Resolved

The Adverse Effects of Orthodontic Treatment

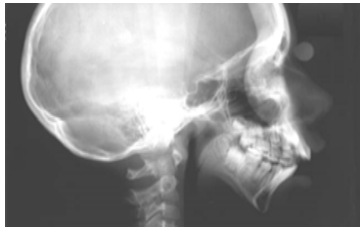
Extraction of Teeth and Supplemental Orthognathic Surgery



Pre-surgical correction of severe Class II malocclusion

The Adverse Effects of Orthodontic Treatment

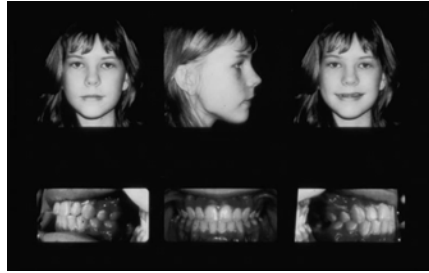
Extraction of Teeth and Supplemental Orthognathic Surgery



Pre-surgical correction of severe Class II malocclusion

The Adverse Effects of Orthodontic Treatment

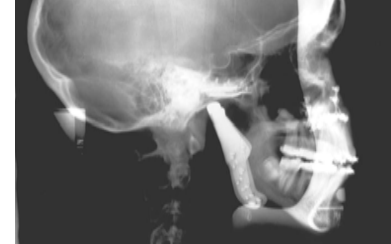Extraction of Teeth and Supplemental Orthognathic Surgery



Post-surgical correction of severe Class II malocclusion

The Adverse Effects of Orthodontic Treatment

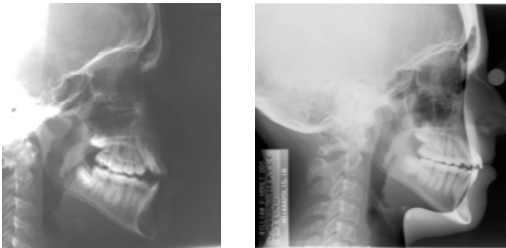Extraction of Teeth and Supplemental Orthognathic Surgery



Post-surgical correction of severe Class II malocclusion

The Adverse Effects of Orthodontic Treatment

Abnormal Growth Patterns of the Jaws

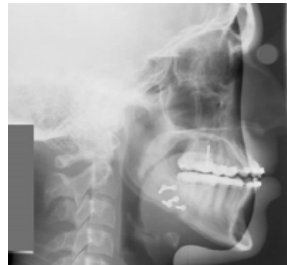

Pre-orthodontic treatment headplate demonstrating anterior open bite

Post orthodontic treatment demonstrating relapse of open bite treatment

The Adverse Effects of Orthodontic Treatment

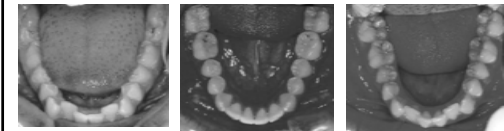
Abnormal Growth Patterns of the Jaws



Final surgical correction due to abnormal mandibular growth

The Adverse Effects of Orthodontic Treatment

Post Treatment Changes in Alignment



Pre-orthodontic treatment

Completion of orthodontic treatment

Post-orthodontic treatment relapse