

# Headgear Appliances

**Natalie A. Capan, D.M.D.**

580 Sylvan Avenue, Suite 1M  
Englewood Cliffs, New Jersey 07632

(201)569-9055

[www.CapanOrthodontics.com](http://www.CapanOrthodontics.com)

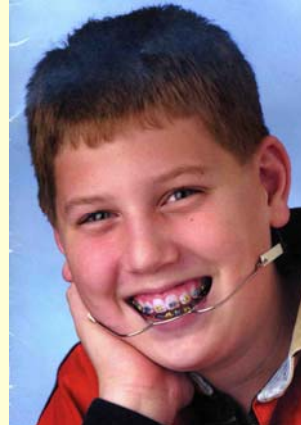CapanOrtho@nj.rr.com

A Common Misconception

Dentofacial Orthopedics  
*and* Orthodontics

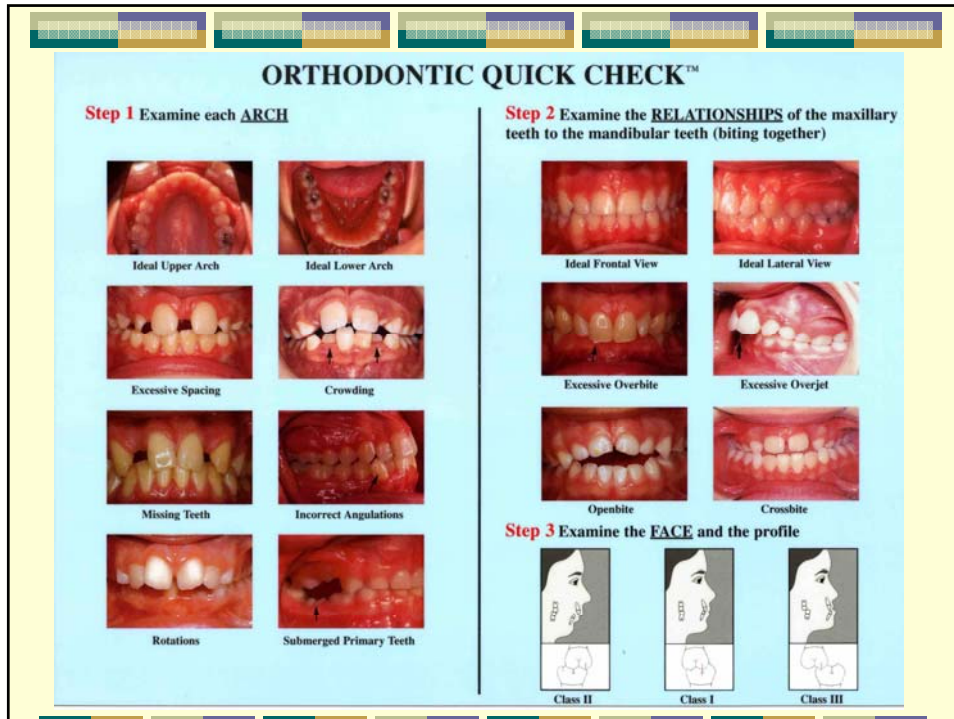
## What is Headgear?

- Orthopedic appliance that allows orthodontists to control growth of facial structures
- Various designs
- Used with growing patients



## Ideal Orthodontic Treatment Sequence

- All patients should be referred no later than age 7 for an orthodontic consult
- At that visit, orthodontist assesses if there are any issues that must be addressed prior to eruption of all of the adult dentition
- If so, patient is receives comprehensive orthodontic treatment
  - Phase I – Typically between ages 7-11
  - Phase II – Begins after eruption of most of adult dentition



## Importance of Proper Planning of Phased Treatment

- Phase I and Phase II are planned together to work in accordance with each other
- Patient's case must be treatment planned and diagnosed completely before the start of Phase I to ensure proper design of any Phase I appliance
- Just like headgear, all of the phase I appliances require proper design in order to be beneficial to the patient
- Proper diagnosis requires
  - Panoramic Radiograph
  - Cephalometric Radiograph
  - Models
  - Photos
  - Full orthodontic examination

## Typical Phase I Treatments

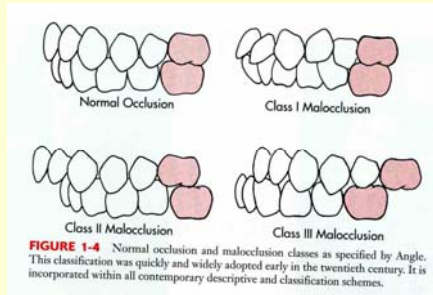
- Sagittal Corrections (Anteroposterior)
  - Headgear
  - Functional appliances
  - Active retainers
- Transverse Corrections
  - Expanders
- Vertical Corrections
  - Bite plane retainers
- Spacing Corrections
  - Space maintainers
  - Nance appliances

## Phase II Treatment

- Fixed bracketed appliances on maxillary and mandibular teeth
- If phase I is conducted properly, phase II treatment can often minimize need for premolar extractions and excessively long treatment times

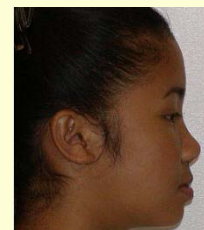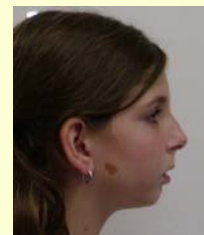
## Angle's Classification of Malocclusions - Review

- Class I – Normal molar relationship (neutroclusion)
  - The mesiobuccal cusp of maxillary molar in line with the buccal groove of the mandibular molar
- Class II – Lower molar distal to upper molar (distocclusion)
- Class III – Lower molar mesial to upper molar (mesioclusion)



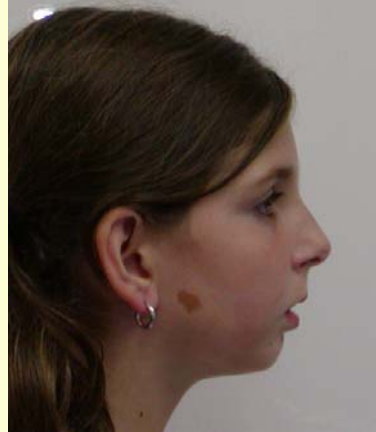## Types of Headgear

- Class II Correction (excess growth of maxilla/deficient growth of mandible)
  - Cervical Headgear
  - High Pull Headgear
  - Combination
- Class III Correction (deficient growth of maxilla/excess growth of maxilla)
  - Reverse Pull Headgear
  - Chin Cup



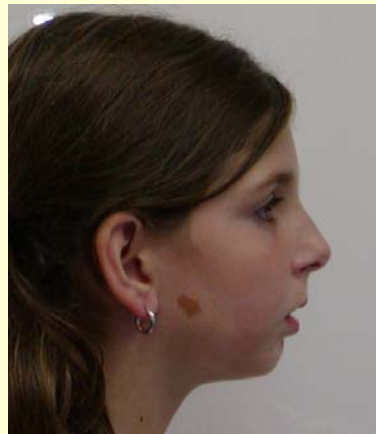## Differential Diagnosis of Class II Skeletal Pattern

- Anteroposterior
  - Prognathic maxilla/retrognathic mandible/combination of both
  - Superimposed on the skeletal problems are the maxillary and mandibular dentition which may be protrusive or retrusive and proclined or retroclined
- Vertical
  - facial excess or deficiency must be considered
- Transverse
  - Maxillary or mandibular constriction



## Treatment Options for Class II Correction

- Restrict maxillary growth
  - Headgear
  - Must be in growing patient
- Retract maxillary dentition
  - Limited potential
- Camouflage by extraction of upper premolars
- Advance the Mandible
  - Alter growth with a functional appliance
  - Surgery
- Advance Mandibular Dentition



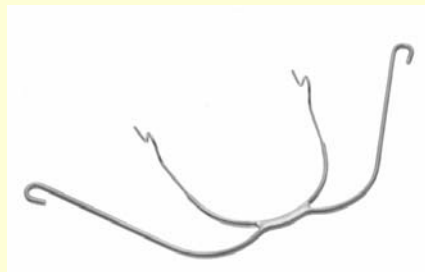
## Headgear Components

- Force applied to first molars that are banded via a facebow with a headcap or a neckstrap for anchorage



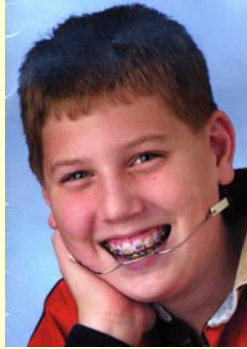## Facebow

- Outer bow – different lengths
- Inner bow – sized, connects to the maxillary molars



## Headstraps

Cervical Type



High Pull Headgear



## Cervical Headgear

- Extraoral anchorage is at the back of the neck
- Advantages
  - Easy to wear
  - Not as visually apparent
- Disadvantages
  - Causes extrusion of the upper first molars which can cause an open bite





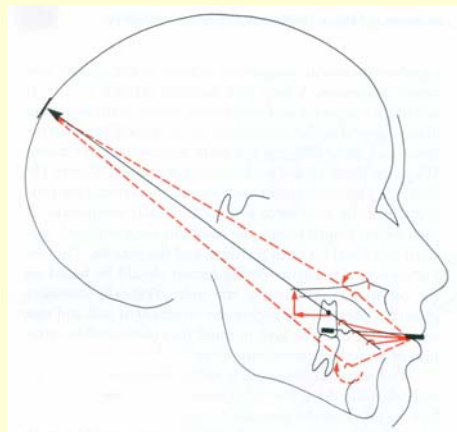
## High Pull Headgear

- Anchorage at the back of the head
- Advantages
  - Will not extrude upper molars
- Disadvantages
  - More hardware for patients
  - More difficult to achieve posterior forces on the maxilla



## High Pull Headgear

- To produce no tipping of the molar, the force of the headgear should go through the root trifurcation



## Optimal Usage of Headgear

- Worn regularly for 10-12 hours per day
- Normally, orthodontists suggest 14 hours/day
- Growth hormone released in the early evening
- Ideal to place headgear after dinner not before bedtime



## Magnitude of Force

- Ideal amount of force is 350-450 gm per side (12 to 16 ounces)
- Most movement through intermittent forces
- Hyalinized bone around molars
- Mobility of Molars normal



## Effects of Excessive Force

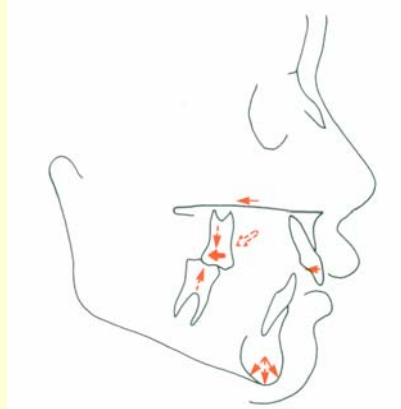
- Greater than 1000 gm total
- Traumatic to the teeth and supporting structures

## Effects of Less Force

- May produce dental changes and not skeletal changes

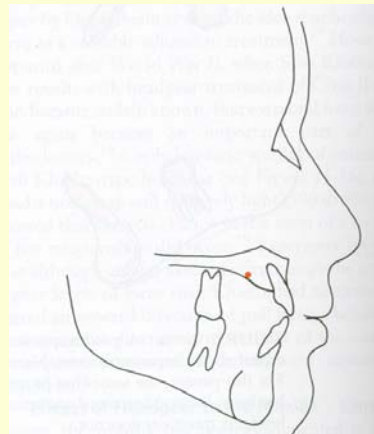
## Side Effects of Headgear

- Unwanted extrusion forces on maxillary molars (typically found with cervical headgear) will cause the mandible to move inferiorly and posteriorly
- Negates Class II correction
- Can also be caused with distal tipping of molars



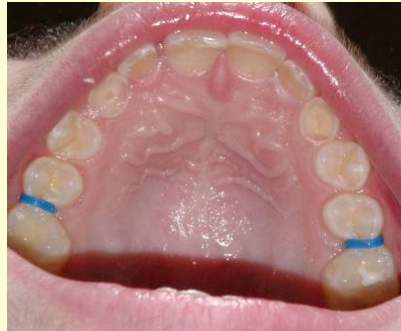## Center of Resistance

- Studies show that the center of resistance of the maxilla is above the roots of the premolar teeth
- Forces must be directed perfectly through this point to effectively restrain maxilla without tipping it



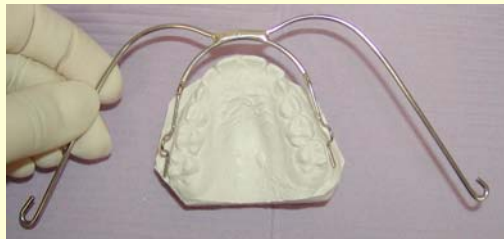## Clinical Procedures in Headgear Placement

- Separators make room for band placement
- Molar bands placed on maxillary first molars fit with buccal tubes
- Bands are fitted and cemented



## Facebow Fitting

- Preformed facebows selected and modified to fit the arch form of the patient
- Inner bow should fit closely to the arch form
- Omega loops/stops should allow the anterior portion to be about 4-5 mm away from maxillary incisors
- Anterior portion should fit comfortably between the lips when in place



## Facebow Expansion

- As the Class II relationship corrects, crossbite will occur if the facebow is not adequately expanded
- 2 mm expansion is sufficient
- Patient will need to squeeze inner bow to place it in the tubes

## The Outer Bow adjustment

- The outer bow should rest several millimeters from the cheeks
- The bow should be cut to proper length and inclination

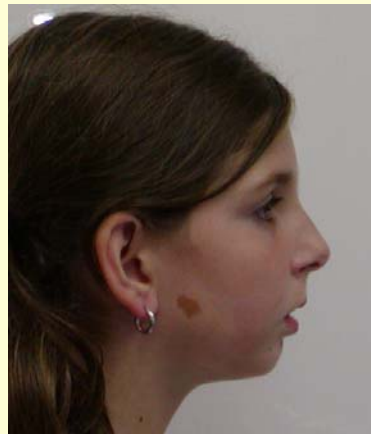## Class II Presentation – Frontal View

- Protrusion of the upper incisors
- Possible incompetent lips

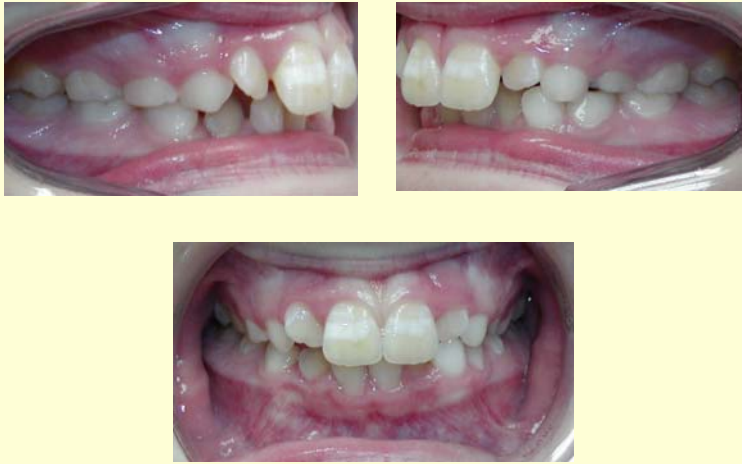

## Class II Soft Tissue Findings – Profile View

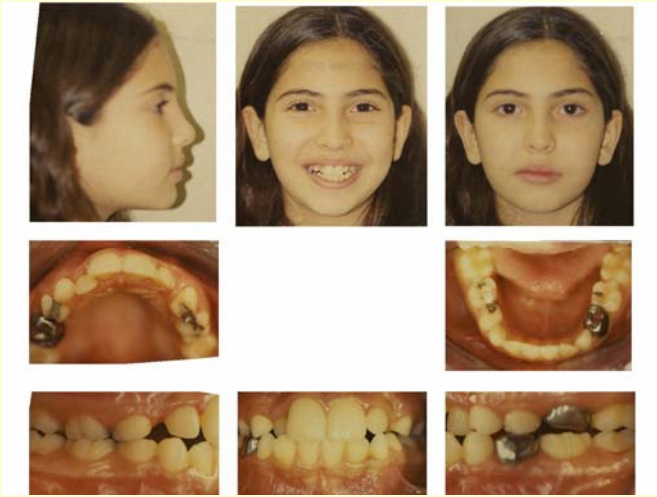- Prognathic maxilla
- Retrognathic mandible
- Incompetent lips
- Strained facial musculature



# Dental Findings

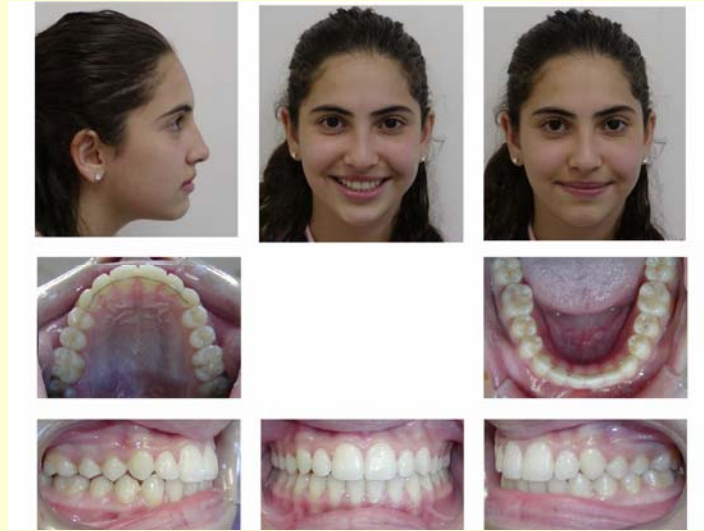


# Class II Case - Initial





## Class II Case - Final



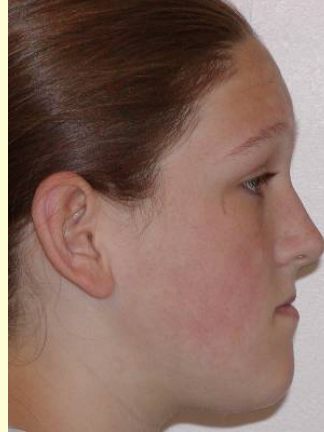## Frequent Soft Tissue Findings – Frontal View Class III Patient

- Narrow alar base
- Deficient zygomatic, paranasal, infraorbital areas
- Margin of sclera showing below pupils
- Midface deficiency
- Thin vermilion border
- Decreased maxillary incisor exposure at rest
- Reduced upper lip length



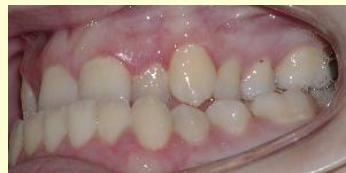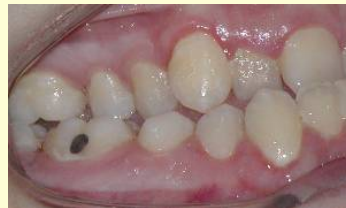## Frequent Soft Tissue Findings – Profile View

- Mandibular prognathism
- Well defined mandibular border
- Normal neck-chin angle of 120 degrees
- Midface deficiency



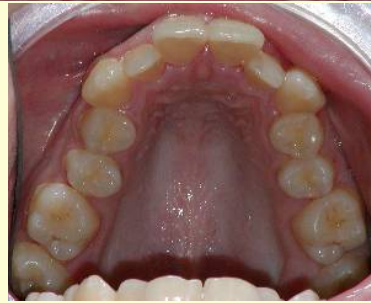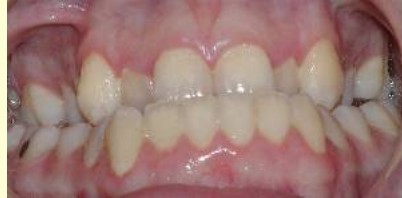## Frequent Dental/Intraoral Findings

- Mesiocclusion of molars and canines
- Crossbite tendency
- Buccal crown tipping of maxillary molars

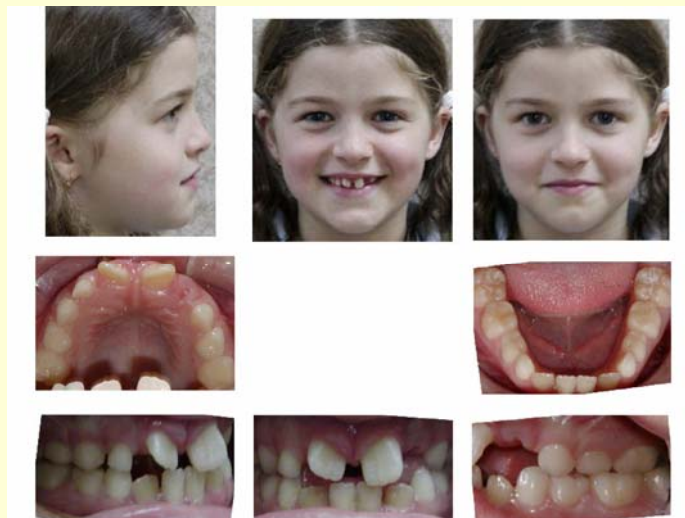

## Frequent Dental/Intraoral Findings

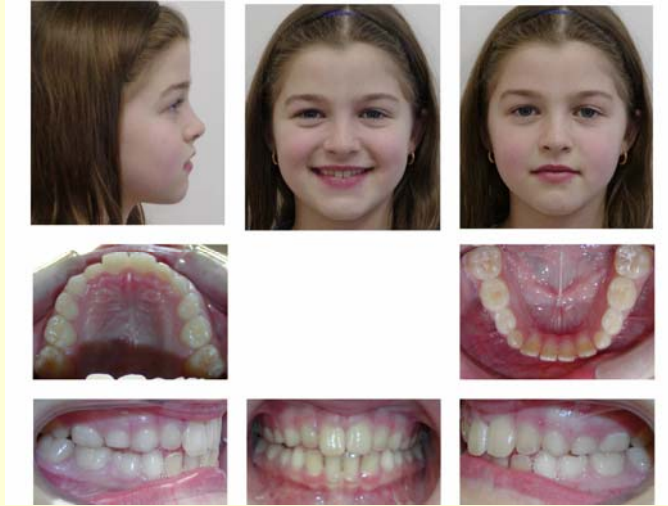
- Decreased attached gingiva for mandibular anterior dentition
- Maxillary retrognathism
  - Often absent or undersized maxillary lateral incisors
  - Maxillary dental crowding in canine/premolar area
- Mandibular Prognathism
  - Large tongue with crenations, interdental spacing, generalized open bite



## Class III Skeletal Patient

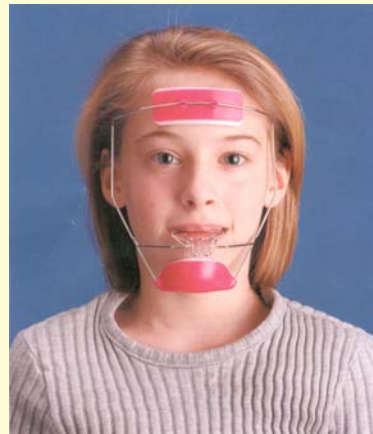


## Progress (Between Phase I and Phase II)



## Reverse Pull Headgear

- Forward traction on the maxilla
- Facemask attached to banded maxillary molars by elastics
- Side effects include downward and backward rotation of the mandible
- Lingual tipping of the mandibular incisors

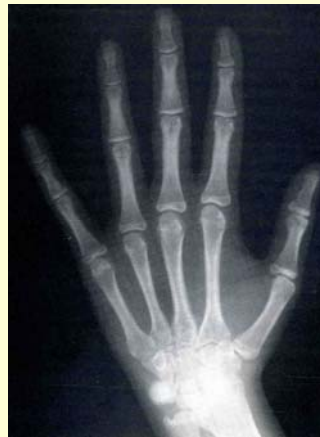


## Timing of Any Headgear Treatment

- Females
  - 8.5-10.5 years old
  - In general, if menses have occurred, most of the rapid growth has already occurred and headgear will not be very helpful
- Males
  - 9.5-11.5 years old

## More Technical Timing of Treatment

- Hand-Wrist Radiographs can be taken with the cephalometric units in orthodontic offices
- The ossification of various bones at the cartilaginous plates can be compared to an atlas
- A more scientific guide of actual degree of growth remaining





Why Didn't the Headgear  
Work?



The Most Important Element

**COMPLIANCE!**



## Another Possible Factor

- No one can predict how much differential growth the patient will have during the treatment time
- Good late growth of the mandible is very beneficial in the Class II correction with headgear
- Can be checked by taking serial radiographs and determining growth of structures during treatment time