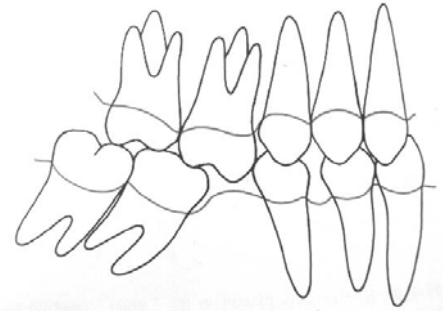
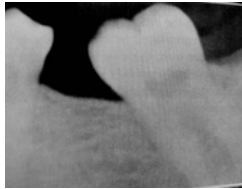


Molar Uprighting

Dr. Margherita Santoro
Division of Orthodontics
School of Dental and Oral surgery



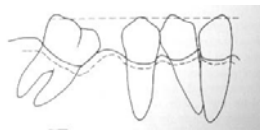
Definitions

Molars

The wide occlusal surface is designed for food grinding. The surface needs to be aligned with the occlusal plane for maximum efficiency

Occlusal plane

Horizontal Plane connecting all teeth



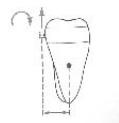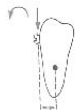Consequences of tooth loss

- Mesial tipping and rotations of distal molars
- Distal tipping and rotations of mesial teeth
- Eruption of opposing tooth in edentulous space
- Gingival tissues become folded, and pockets form in the area
- Accumulation of plaque in pockets leads to periodontal damage, with loss of gingival attachment and alveolar bone loss

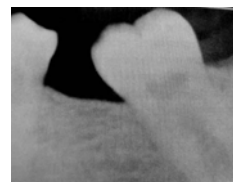
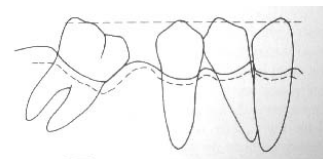
Causes of Molar tipping

Tipping

Rotation of a molar forward (mesially) or backward (distally) around its body mass axis called Center of Resistance



Missing teeth due to extensive decay or early loss of deciduous teeth causes a mesial drift of the remaining molars



Consequences of tooth loss

- Movement of adjacent teeth in open space generates open contacts with food impaction and plaque accumulation
- Occlusal stress is not directed through the tooth vertical axis = intermittent stress
- Presence of occlusal interferences during mandibular movements
- Difficult prosthetic restoration

Indications for space closure

- Young patients
- Absence of periodontal problems (inflammation, bone loss)
- Minimum tipping of the molars
- Adequate presence of dentoalveolar bone mesially to the roots



Objectives

- Restore proper position = upright molars and drifted premolars
- Correct rotations
- Reopen the lost space for prosthetic restoration or close the space orthodontically

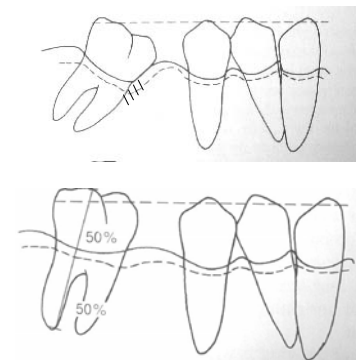
Indications for space regaining

- Adult patients
- The dentoalveolar ridge in the edentulous space is very narrow and would not allow movement of the root
- Bone loss and periodontal pockets on the mesial root of the molar to be uprighted (distal crown movement will usually generate extrusion of the molar with reduction of the depth of the periodontal pockets)



Closing –
mesial root
movement

Reopening-
Distal crown
movement



Indications for space regaining

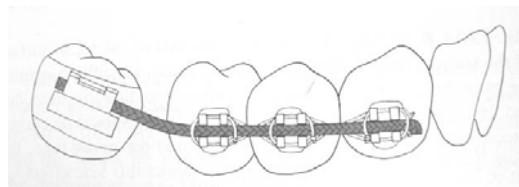
- Slight extrusion must be acceptable and minimized by proper mechanics
- Vertical reduction of the crown needs to be planned for in treatment planning
- Fixed appliances are necessary to control tooth movement
- Anchorage is necessary to provide proper control and reduce side effects

Appliance design

- **Anchorage:** full arch bonding or bonded lingual arch from canine to canine to avoid unwanted tooth movement
- Bands on molars to be uprighted
- Brackets on premolars and canines
- Wires:
 - Alignment with braided wires or Nickel-Titanium
 - Anchorage with rectangular Stainless Steel size .018 x .025
 - Helical uprighting spring size .018 x .025

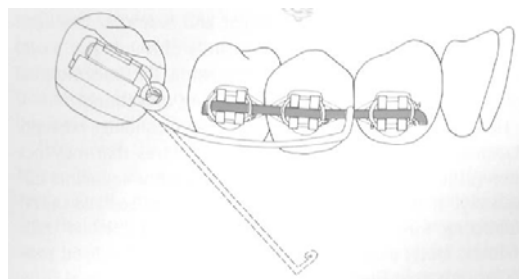
Indications for regaining space

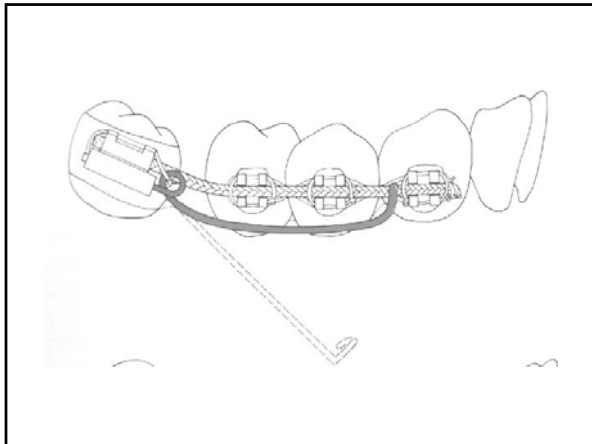
- Early loss of teeth in adult patients with loss of dentolaveolar bone
- Extensive alveolar ridge resorption with knife-shaped bone contours
- Severely tipped molars
- Periodontal involvement of the mesial root(s) of the molar to be uprighted



Procedures for molar uprighting

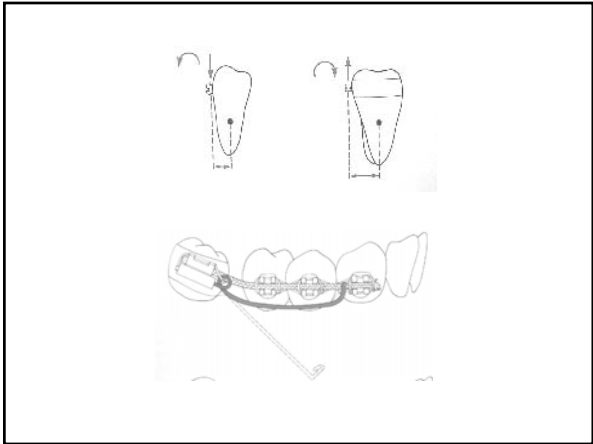
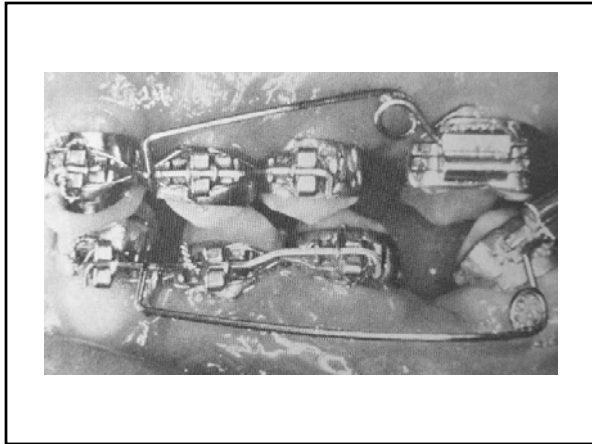
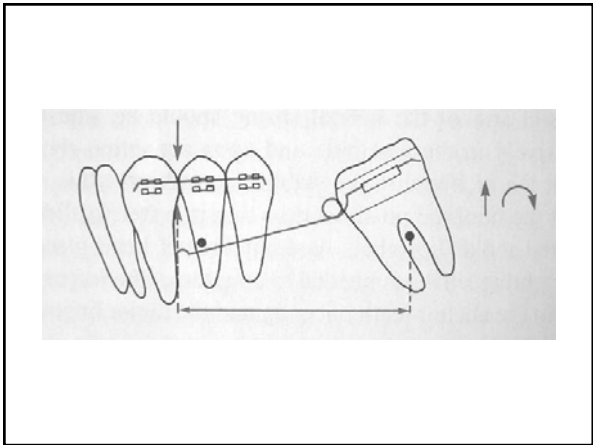
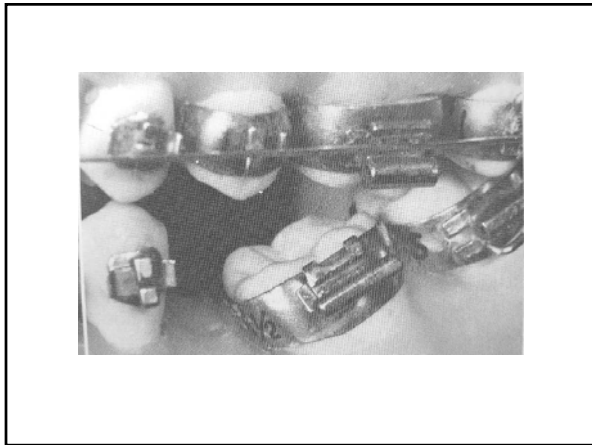
- Plan for necessary space for prosthetic replacement
- Plan for slight extrusion
- Plan for final stable occlusion
- Plan for necessary space distal to the molar to be tipped distally: extraction of third molars may be necessary
- Plan for ANCHORAGE (support and prevention of side effects from surrounding teeth)
- Design appliances
- Plan for duration of treatment
- Plan for final restorations and/or RETENTION

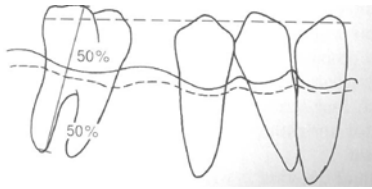




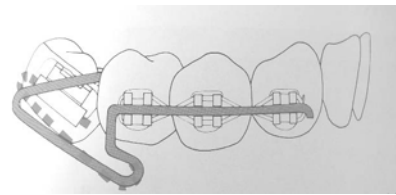
Biomechanics

- **When the auxiliary uprighting helix wire is engaged, several forces are released to the teeth**
 - The molar will receive an extrusive force tipping the molar lingually
 - The anchorage unit will receive an intrusive force tipping the teeth buccally





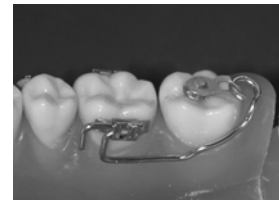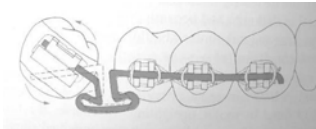
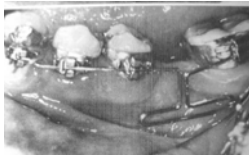
At the end of the uprighting process, the molar will need occlusal adjustments and/or prosthetic therapy which usually function as permanent retention of the results



Reversed loops

Alternative methods

Loops



Lingual auxiliaries

Compressed coil springs

