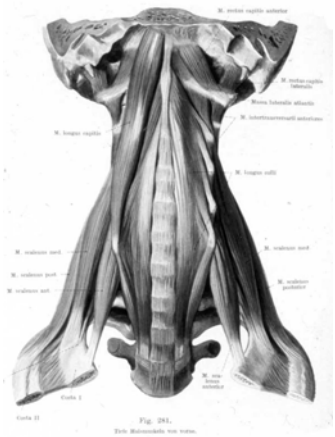

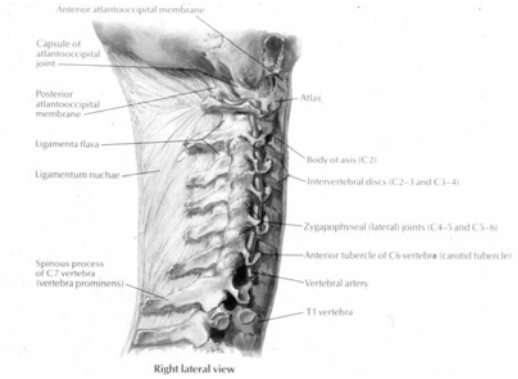

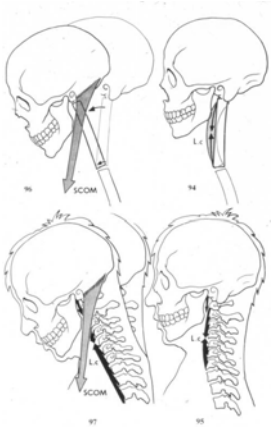

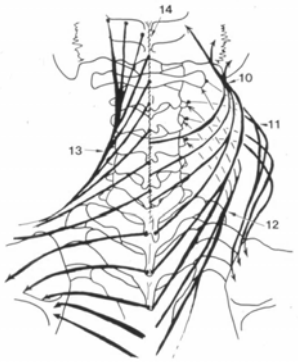

Fig. 1-21. Schema of the superficial muscles of posterior cervical region.
(*10*) Splenius capitis. (*11*) Levator scapulae. (*12*) Splenius cervicis. (*13*) Trapezius (cervical part).

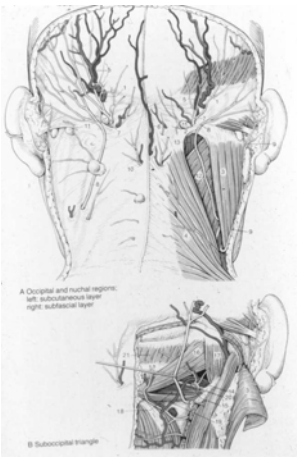
A Occipital and nuchal regions:
left: subcutaneous layer
right: subfascial layer
B Suboccipital triangle

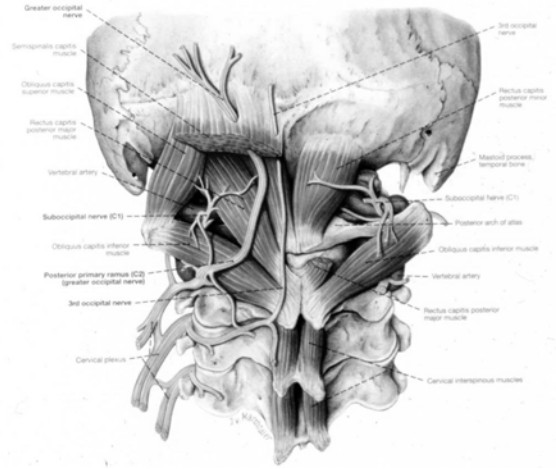
Greater occipital nerve
Semispinalis capitis muscle
Obliquus capitis superior muscle
Rectus capitis posterior major muscle
Vertebral artery
Suboccipital nerve (C1)
Obliquus capitis inferior muscle
Posterior primary ramus (C2) (greater occipital nerve)
3rd occipital nerve
Cervical plexus
3rd occipital nerve
Rectus capitis posterior minor muscle
Mastoid process, temporal bone
Suboccipital nerve (C1)
Posterior arch of atlas
Obliquus capitis inferior muscle
Vertebral artery
Rectus capitis posterior major muscle
Cervical interspinous muscles

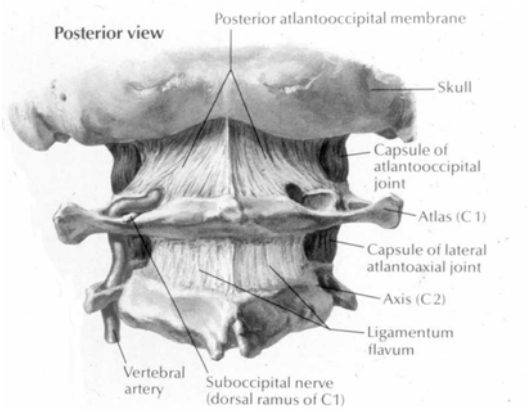
Posterior view
Posterior atlantooccipital membrane
Skull
Capsule of atlantooccipital joint
Atlas (C 1)
Capsule of lateral atlantoaxial joint
Axis (C 2)
Ligamentum flavum
Vertebral artery
Suboccipital nerve (dorsal ramus of C1)

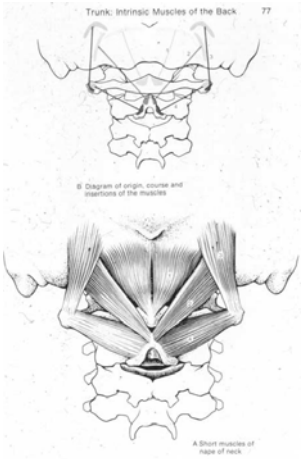
Trunk: Intrinsic Muscles of the Back 77
B Diagram of origin, course and insertions of the muscles
A Short muscles of nape of neck

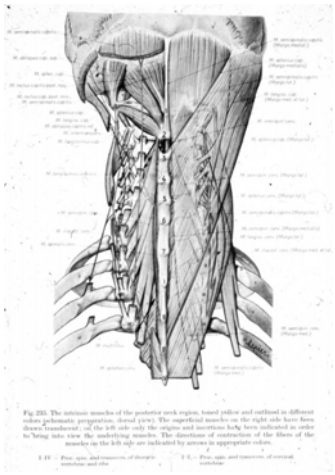
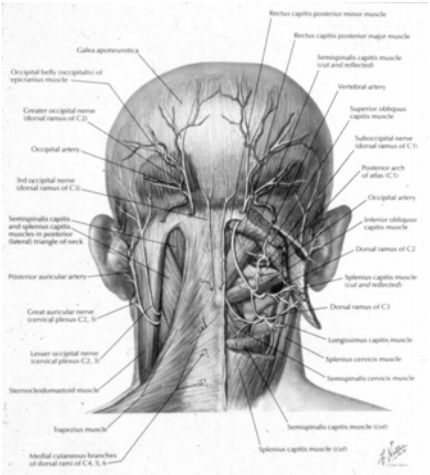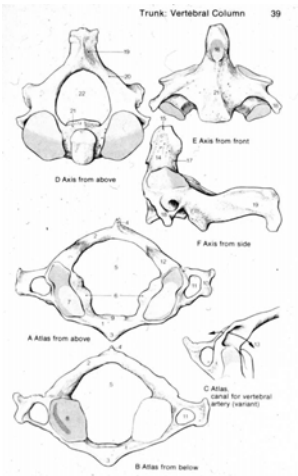
Fig. 235. The intrinsic muscles of the posterior neck region, toned yellow and outlined in different colors (schematic preparation, dorsal view). The superficial muscles on the right side have been drawn translucent; on the left side only the origins and insertions have been indicated in order to bring into view the underlying muscles. The directions of contraction of the fibers of the muscles on the left side are indicated by arrows in appropriate colors.