


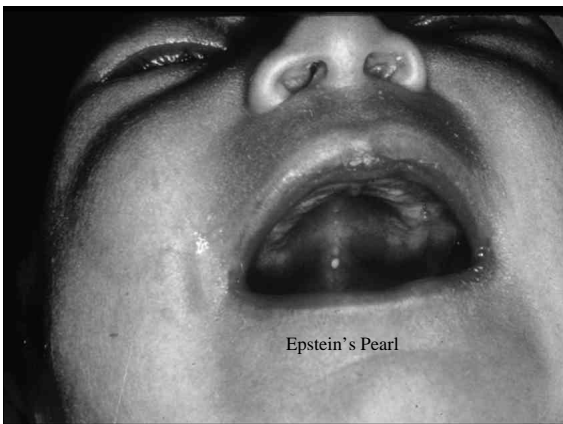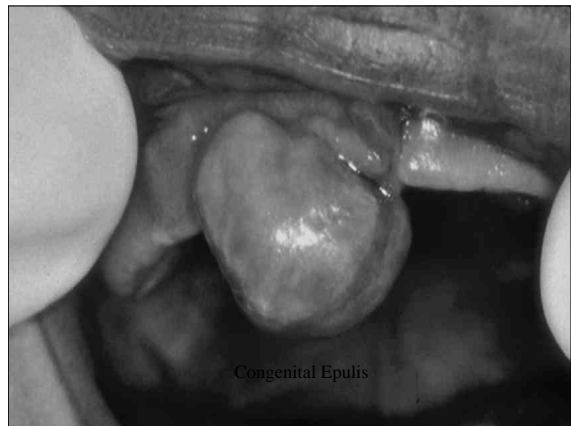
# Pediatric Oral Pathology

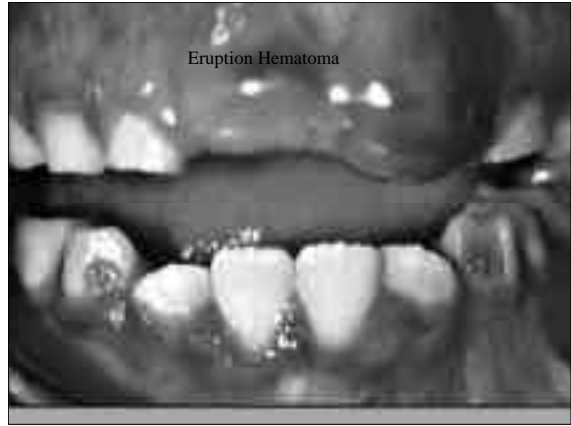


Martin J. Davis

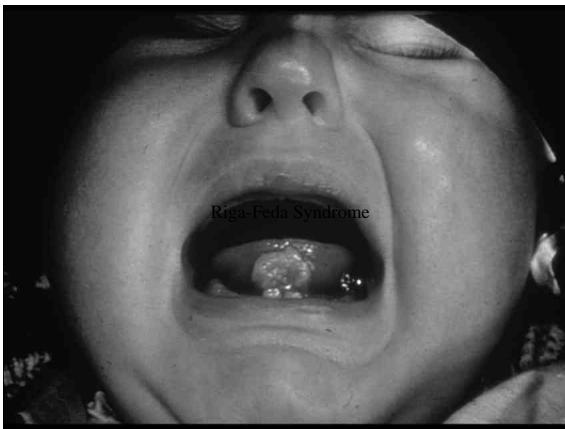
“When you Hear  
Hoofbeats, Think  
Horses NOT  
Zebras”

## Neonate and Infant

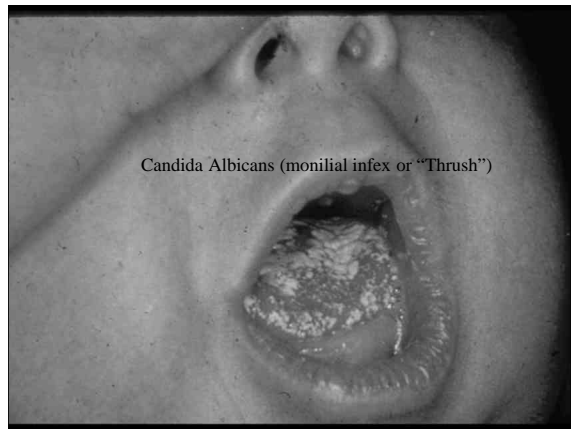



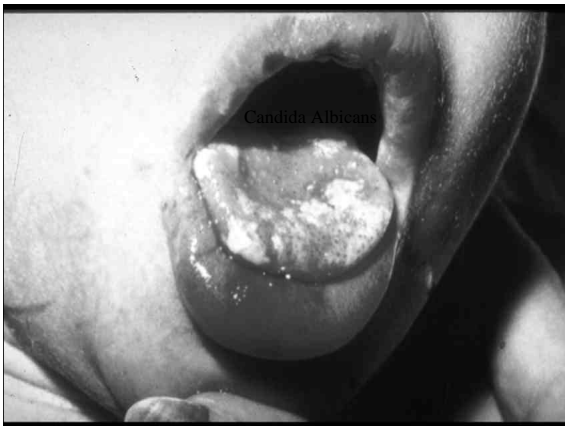Eruption Hematoma



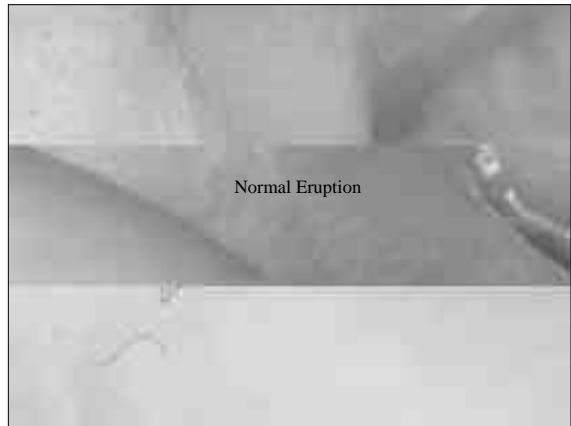
Riga-Pedia Syndrome



Candida Albicans (monilial infex or "Thrush")

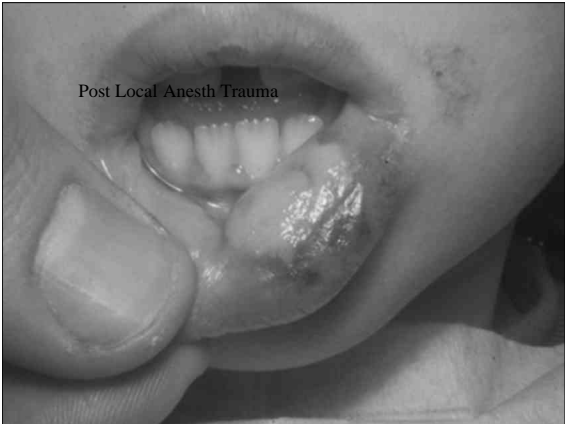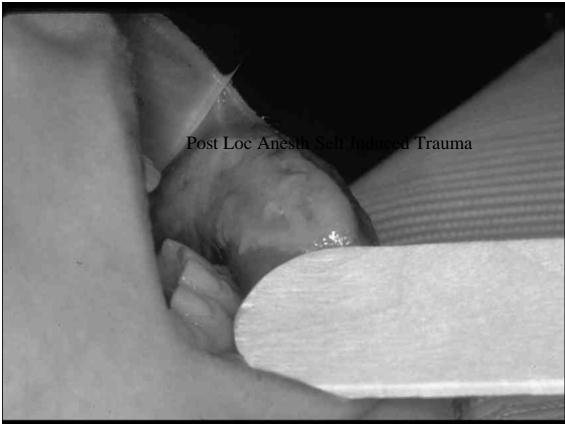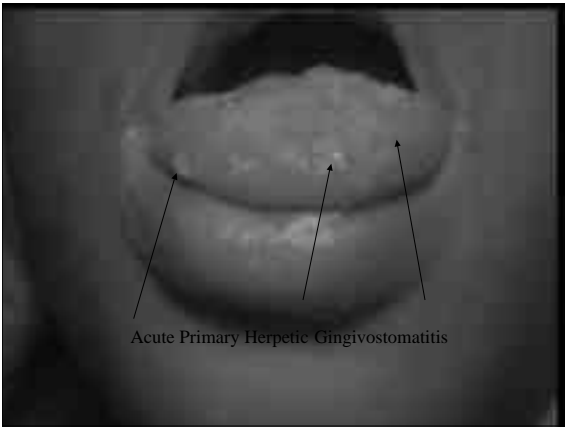
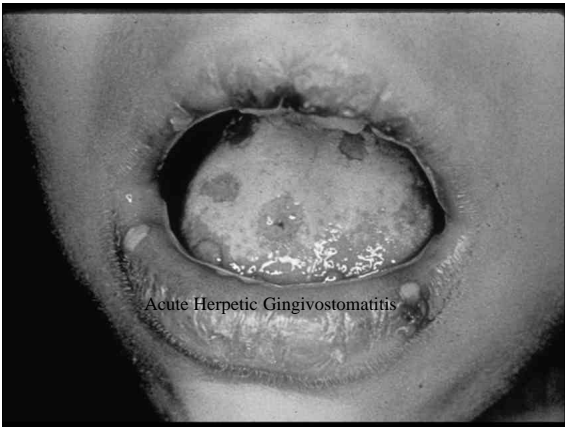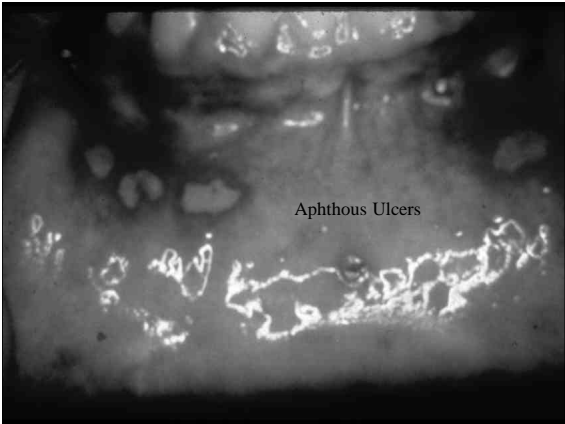


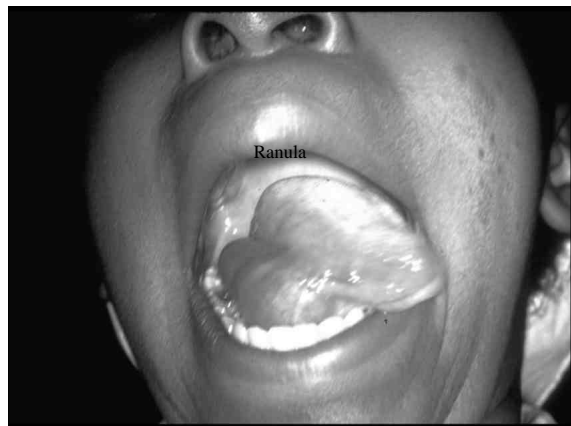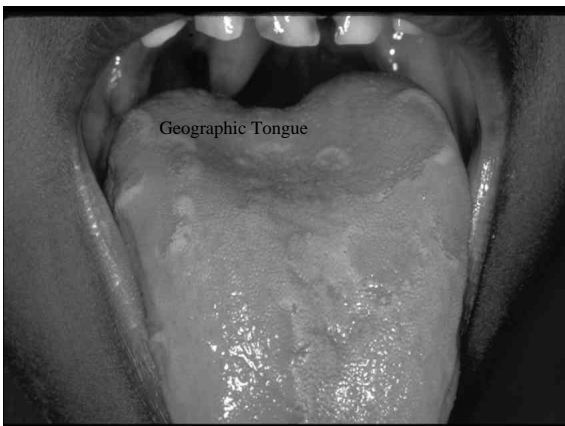
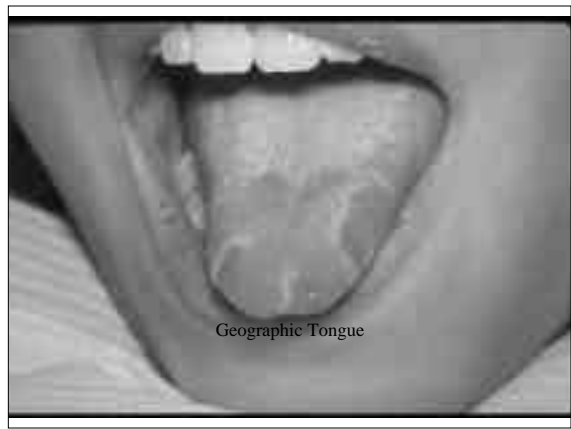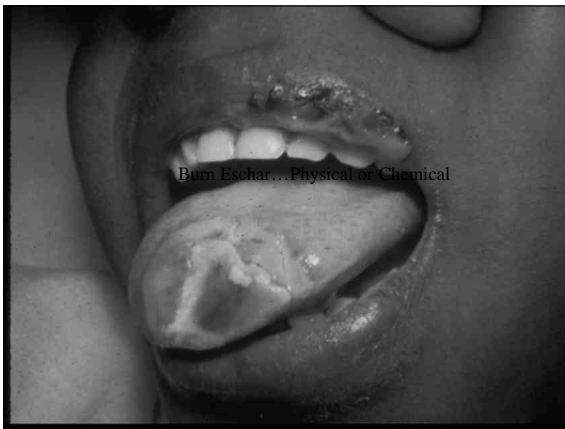
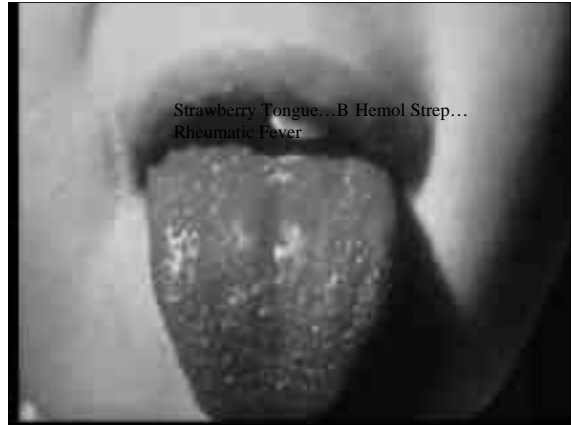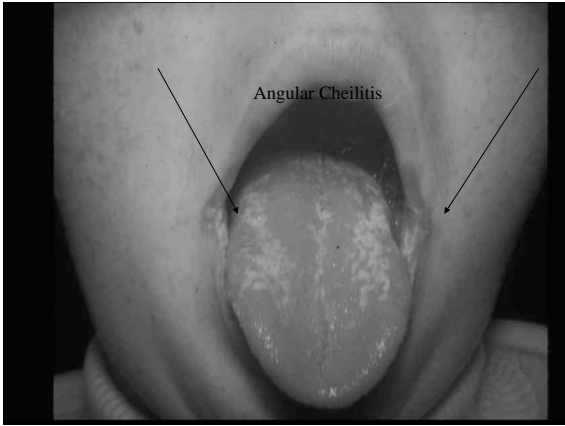
Candida Albicans

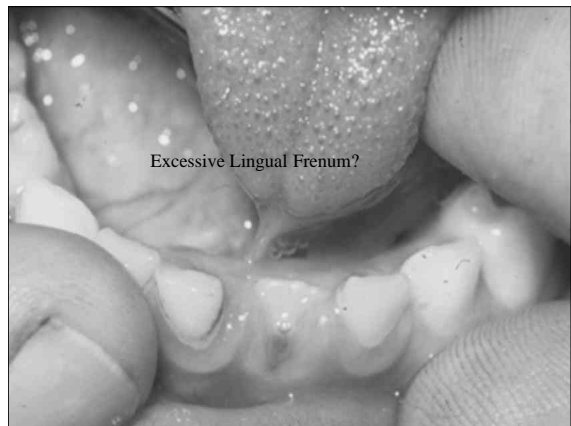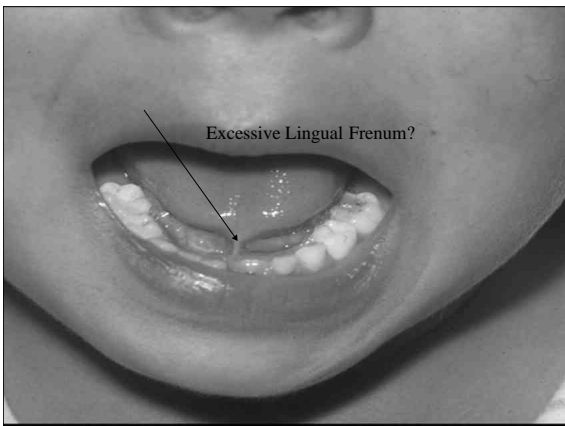
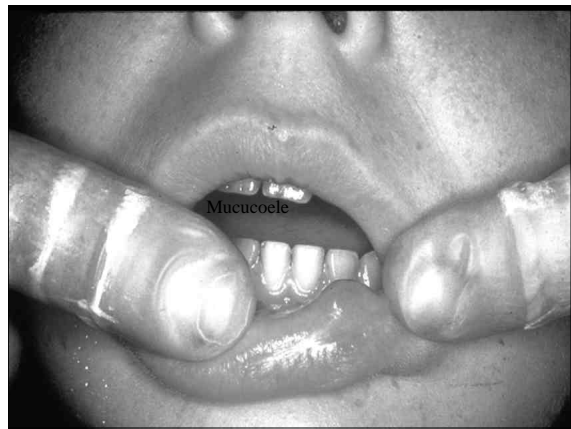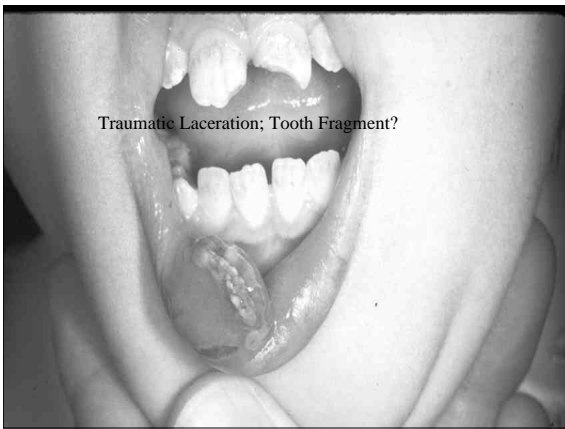


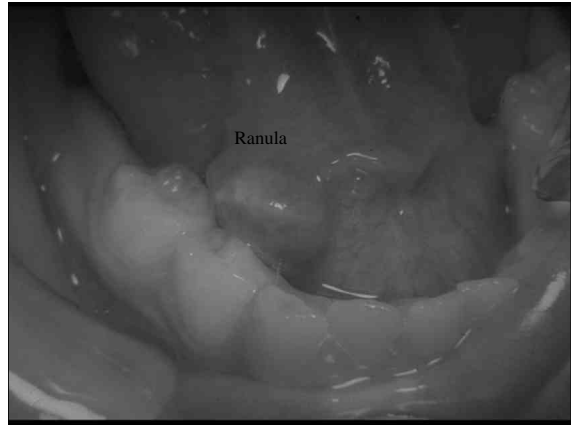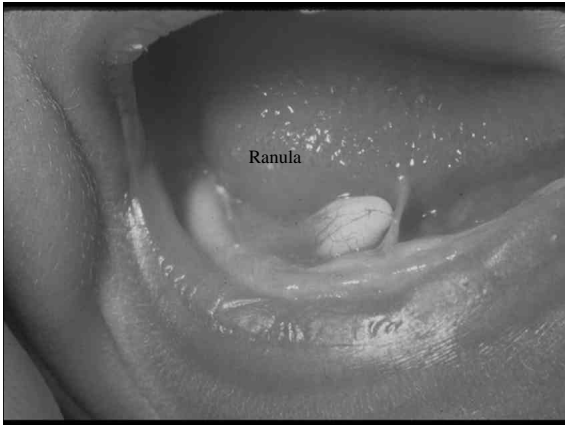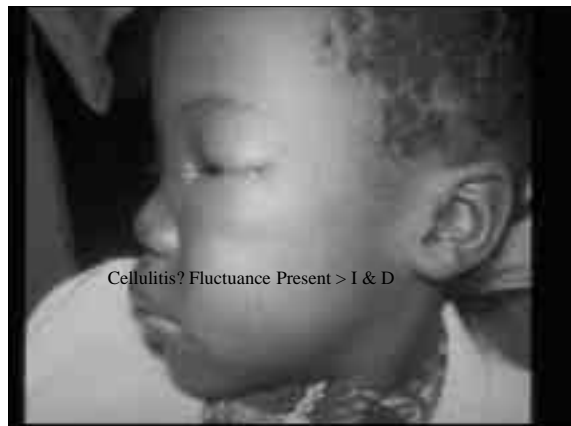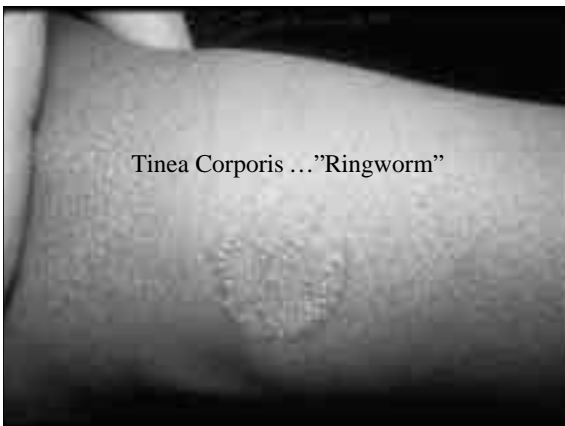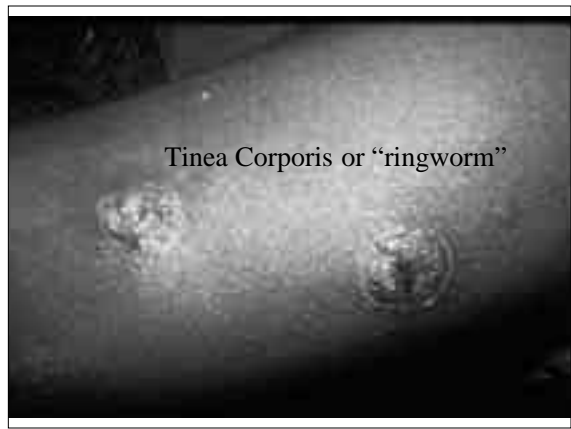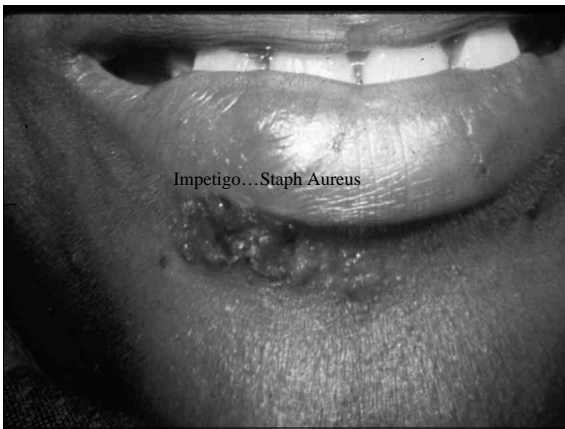
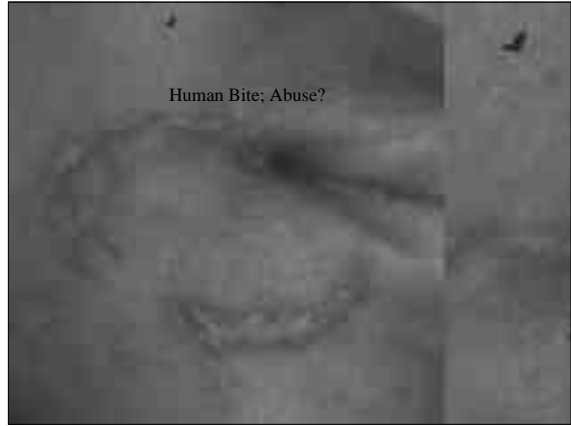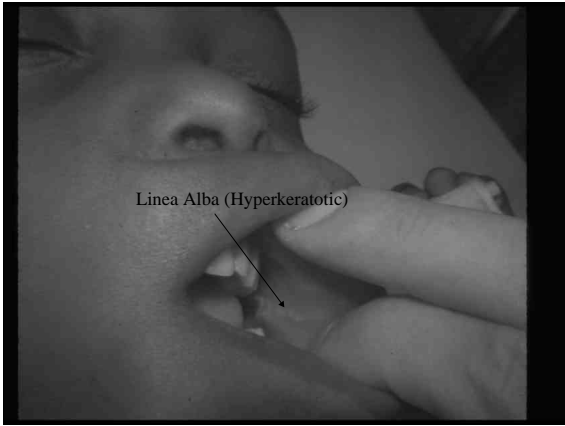Normal Eruption

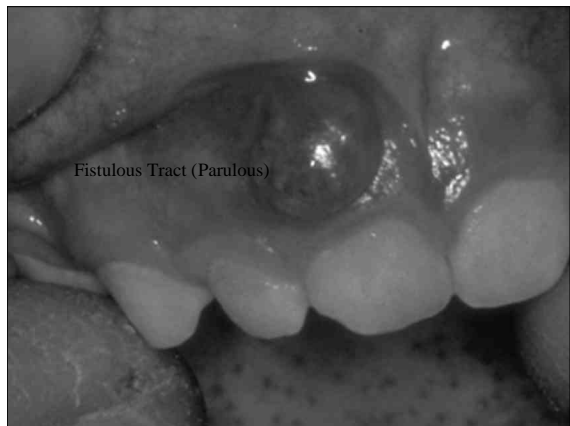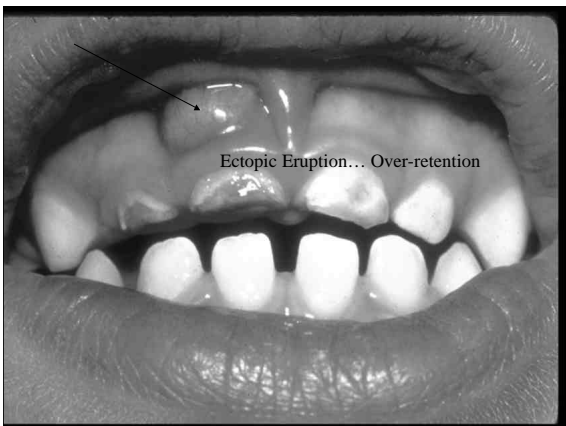
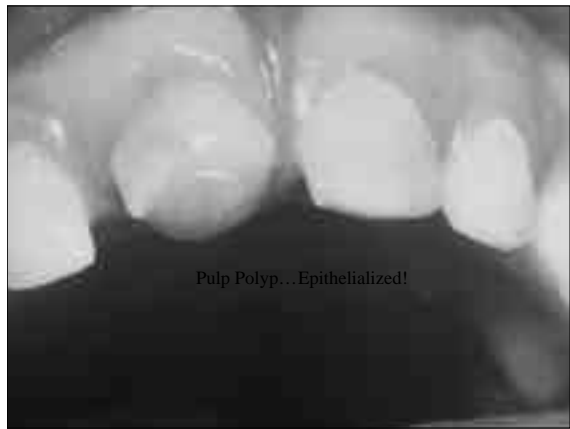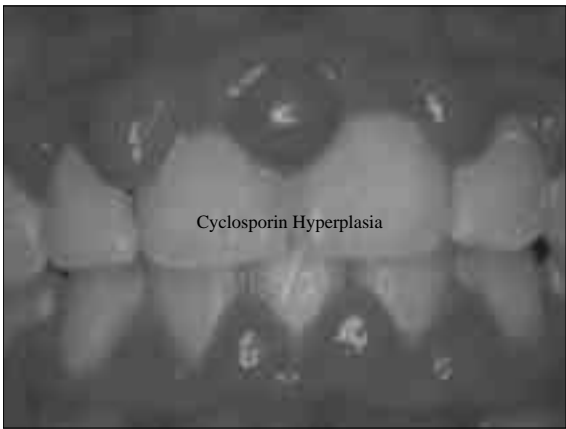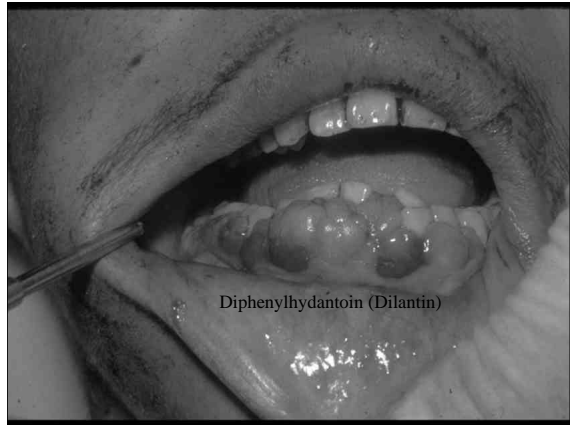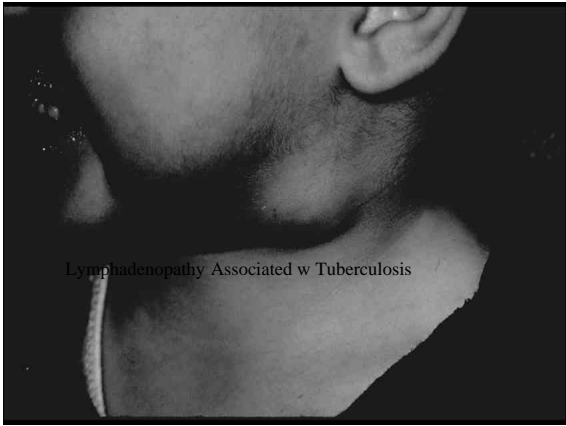
# Soft Tissue Pathology



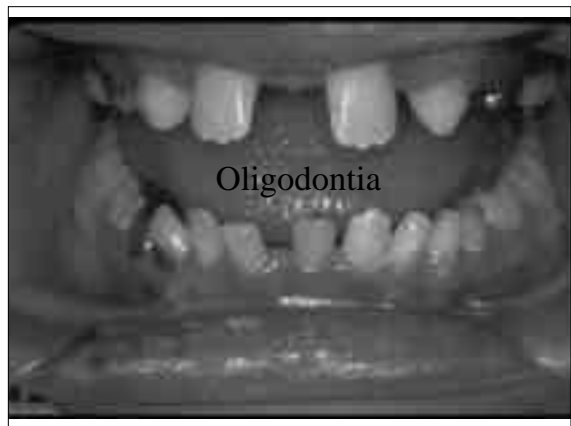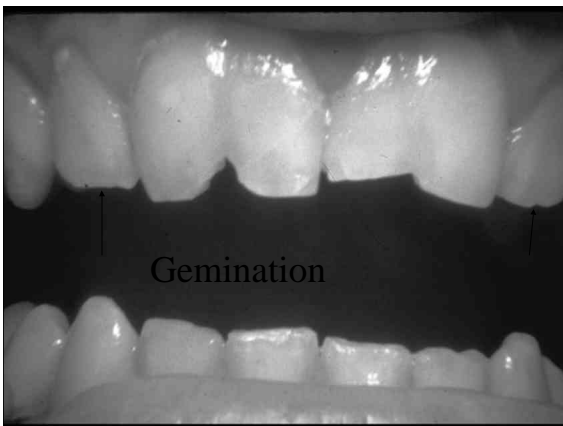
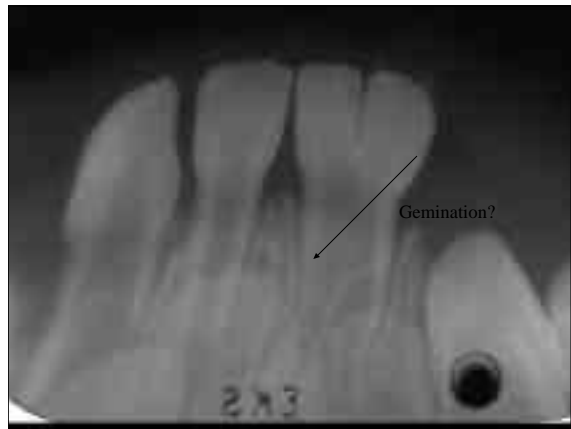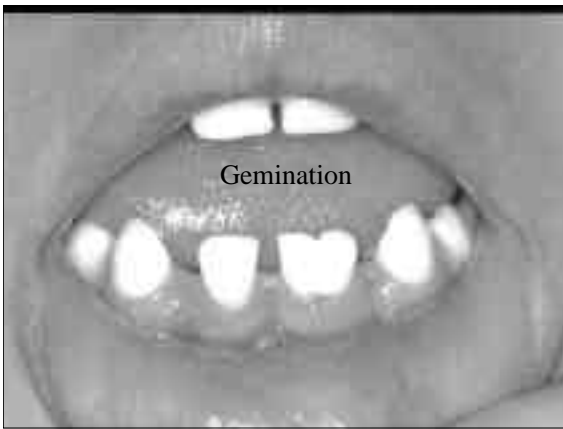


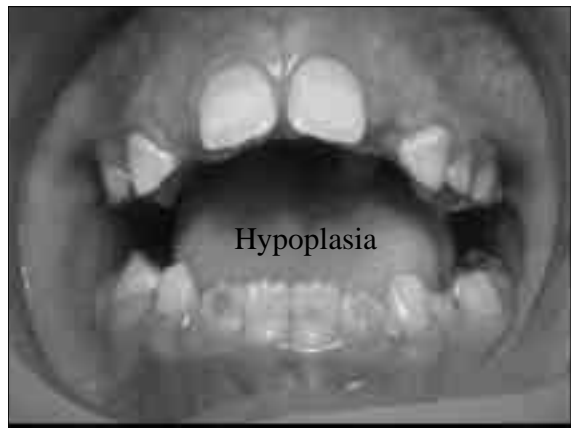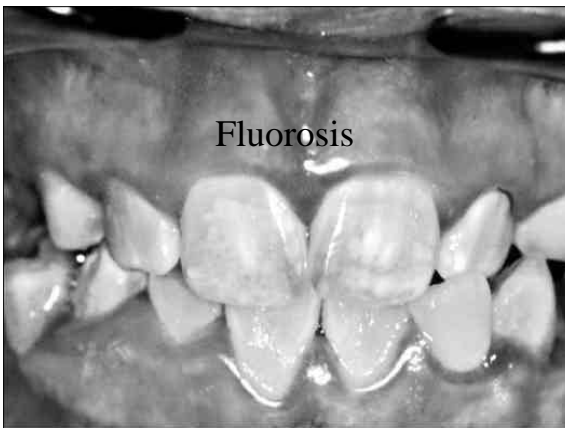
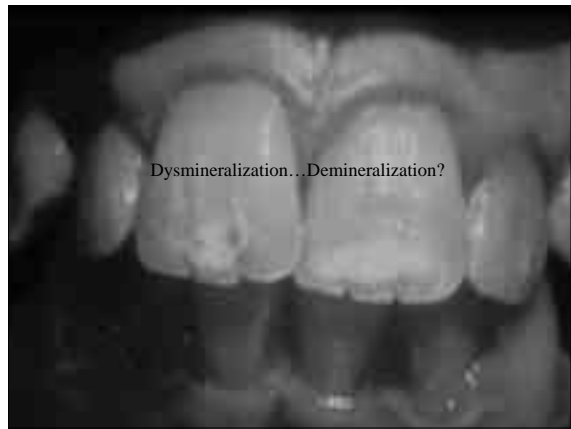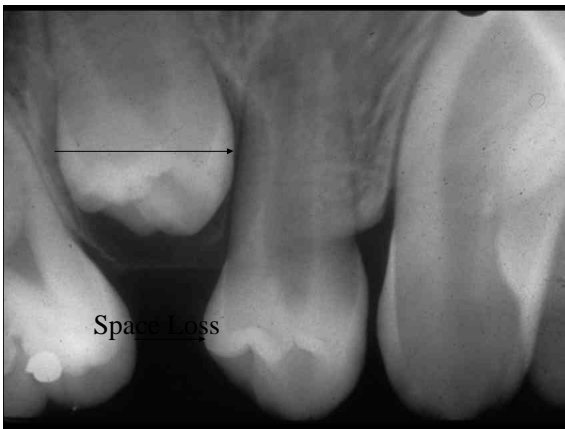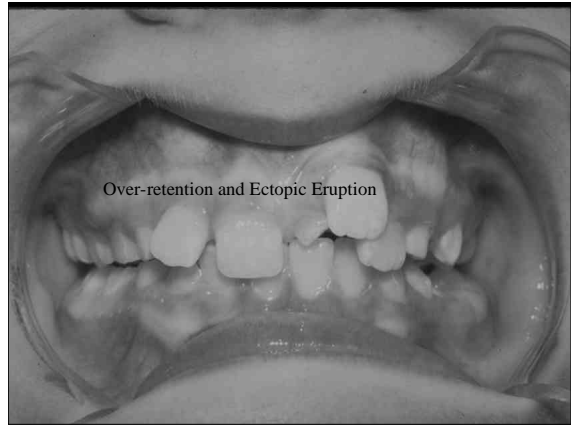


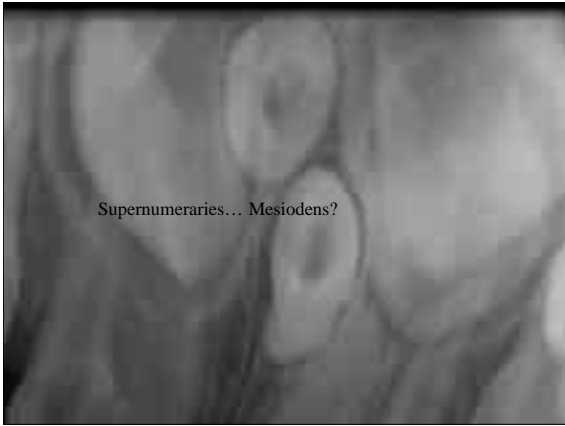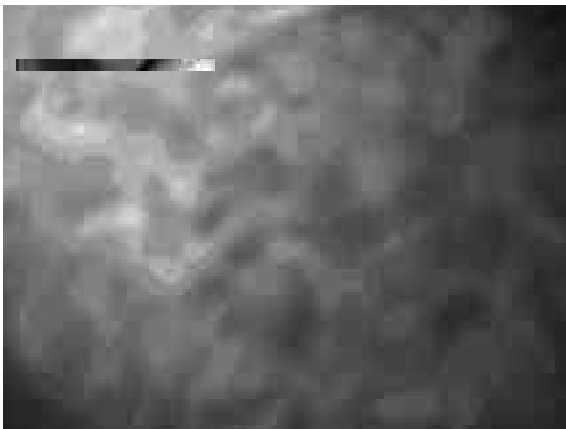
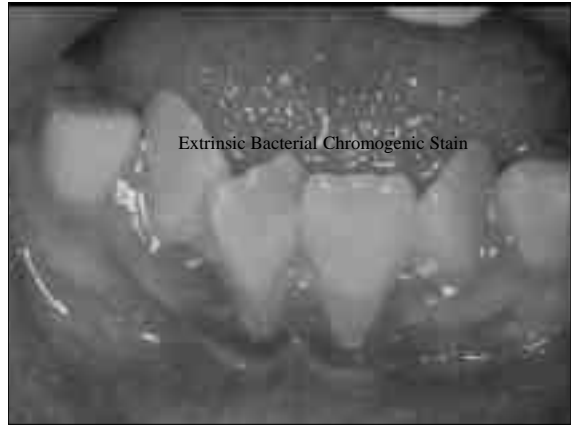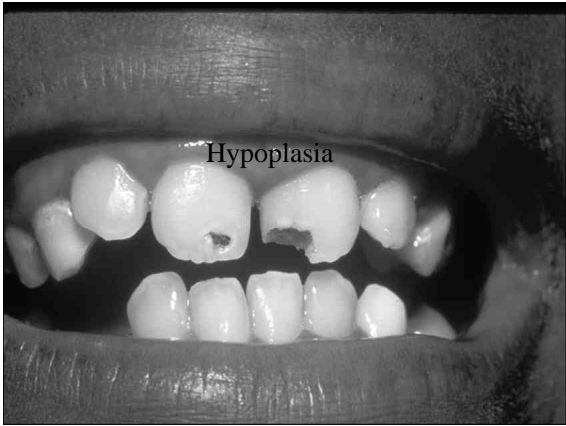




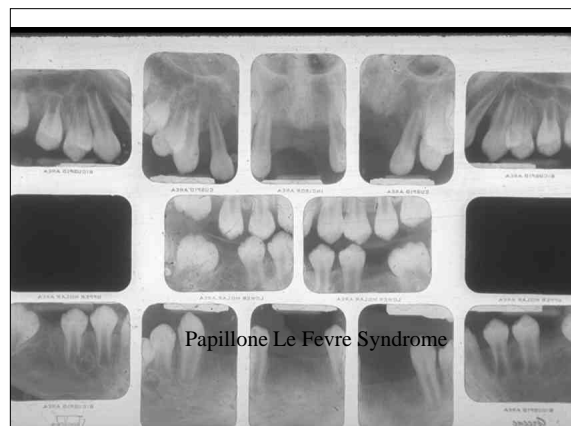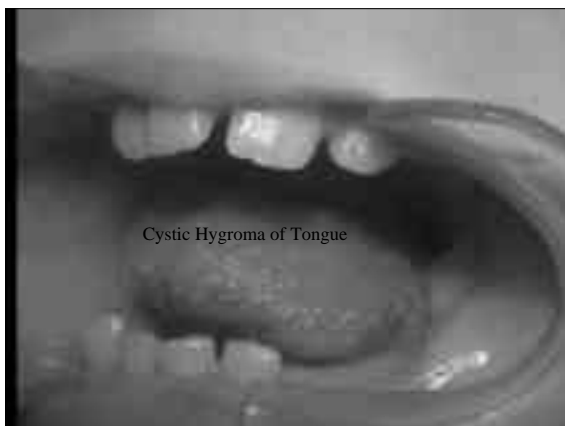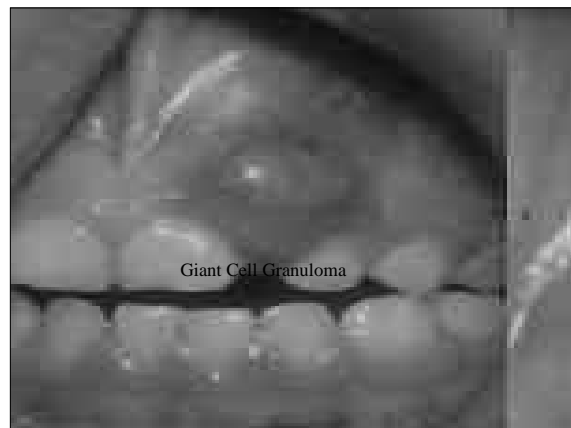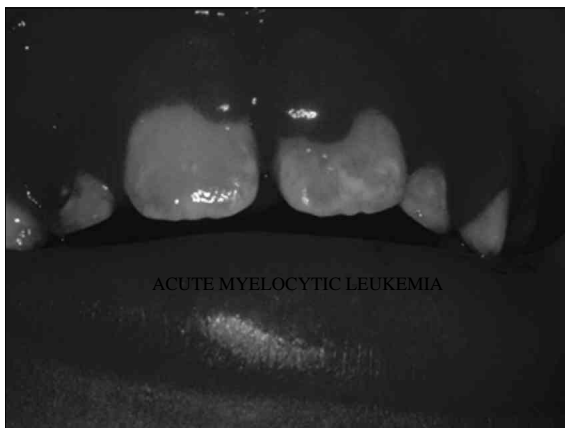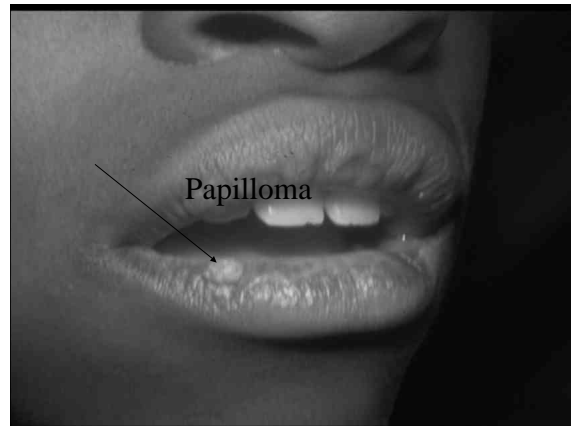
# Dental Anomalies

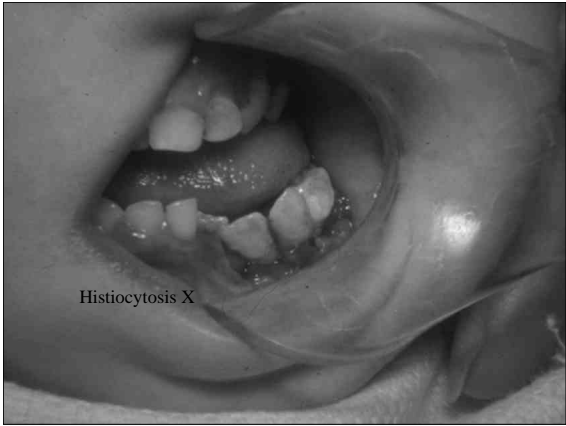




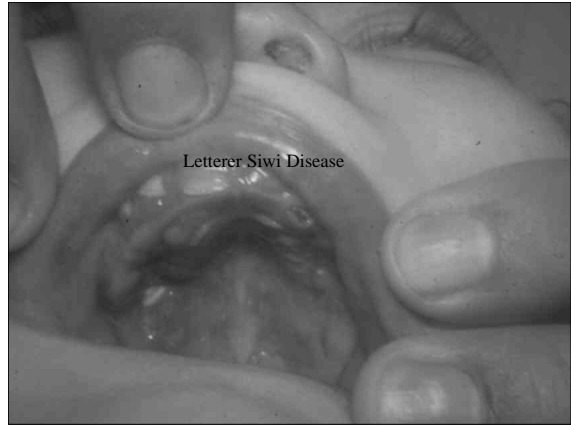
# Pediatric Oncology

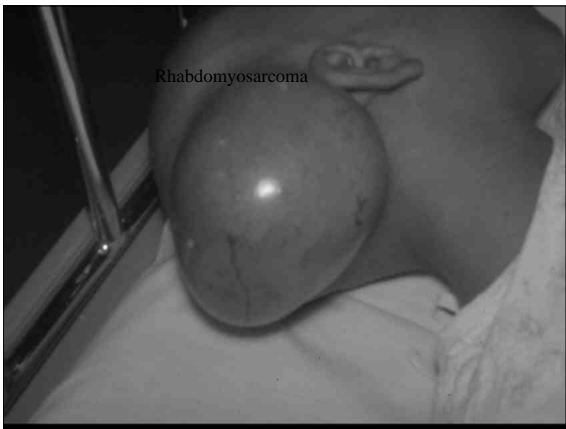



Histiocytosis X



Letterer-Siwi Disease



Rhabdomyosarcoma



Health is a gift from the gods...

