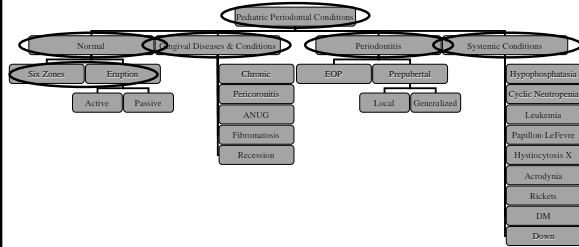


**PEDIATRIC PERIODONTAL CONDITIONS**  
 AT A GLANCE



RICHARD YOON

---

---

---

---

---

---

---

---

---

---

---

---

**PEDIATRIC PERIODONTAL CONDITIONS**  
 SIX COMPONENTS

- |                     |                        |
|---------------------|------------------------|
| Normal Findings     | ➤ Papillary Gingiva    |
| Gingivitis          | ➤ Marginal Gingiva     |
| Periodontitis       | ➤ Attached Gingiva     |
| Systemic Conditions | ➤ Alveolar Mucosa      |
|                     | ➤ Periodontal Ligament |
|                     | ➤ Alveolar Bone        |

RICHARD YOON

---

---

---

---

---

---

---

---

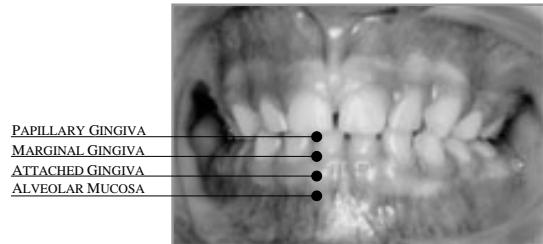
---

---

---

---

**PEDIATRIC PERIODONTAL CONDITIONS**  
 SIX COMPONENTS



RICHARD YOON

---

---

---

---

---

---

---

---

---

---

---

---

**PEDIATRIC PERIODONTAL CONDITIONS**  
SIX COMPONENTS

- Papillary Gingiva
- Marginal Gingiva
- Attached Gingiva
- Alveolar Mucosa
- PDL
- Alveolar Bone

- Interdental Col
- Interdental Saddle

RICHARD YOON

4

---

---

---

---

---

---

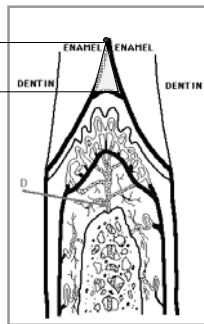
---

---

**PEDIATRIC PERIODONTAL CONDITIONS**  
INTERDENTAL COL

INTERPROXIMAL CONTACT

INTERDENTAL COL



RICHARD YOON

5

---

---

---

---

---

---

---


---

**PEDIATRIC PERIODONTAL CONDITIONS**  
INTERDENTAL SADDLE

SADDLE

INTERDENTAL COL

INTERPROXIMAL CONTACT



RICHARD YOON

6

---

---

---

---

---

---

---

---

**PEDIATRIC PERIODONTAL CONDITIONS**

SIX COMPONENTS

- Papillary Gingiva → Gingival sulcus + free gingival margin.
- Marginal Gingiva → Thicker and rounder.
- Attached Gingiva → Flaccid and retractable.
- Alveolar Mucosa
- PDL
- Alveolar Bone

RICHARD YOON

7

---

---

---

---

---

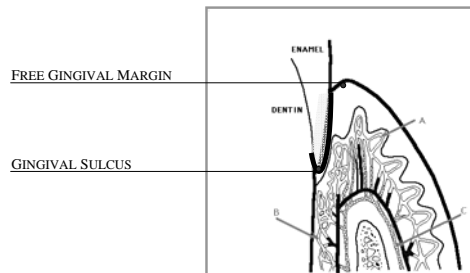
---

---

---

**PEDIATRIC PERIODONTAL CONDITIONS**

MARGINAL GINGIVA



RICHARD YOON

8

---

---

---

---

---


---

---

---

**PEDIATRIC PERIODONTAL CONDITIONS**

MARGINAL GINGIVA



RICHARD YOON

9

---

---

---

---

---

---

---

---

**PEDIATRIC PERIODONTAL CONDITIONS**  
SIX COMPONENTS

- Papillary Gingiva → Base of sulcus to the mucogingival line.
- Marginal Gingiva → Interdental cleft
- Attached Gingiva → Retrocuspid papilla
- Alveolar Mucosa
- PDL
- Alveolar Bone

RICHARD YOON 10

---

---

---

---


---

---

---

---

**PEDIATRIC PERIODONTAL CONDITIONS**  
INTERDENTAL CLEFT



RICHARD YOON 11

---

---

---

---

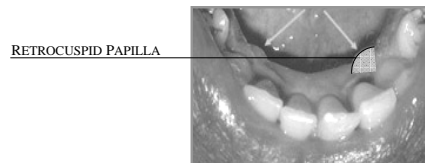
---

---

---

---

**PEDIATRIC PERIODONTAL CONDITIONS**  
RETROCUSPID PAPILLA



RICHARD YOON 12

---

---

---

---

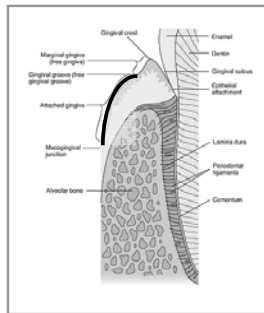
---

---

---

---

**PEDIATRIC PERIODONTAL CONDITIONS**  
**ATTACHED GINGIVA**



RICHARD YOON

13

---

---

---

---

---

---

---

---

---

---

**PEDIATRIC PERIODONTAL CONDITIONS**  
**SIX COMPONENTS**

- Papillary Gingiva
- Marginal Gingiva
- Attached Gingiva
- Alveolar Mucosa
- PDL
- Alveolar Bone

- ↳ Keratin
- ↳ Thin epithelium
- ↳ Width ↑'s

RICHARD YOON

14

---

---

---

---

---

---

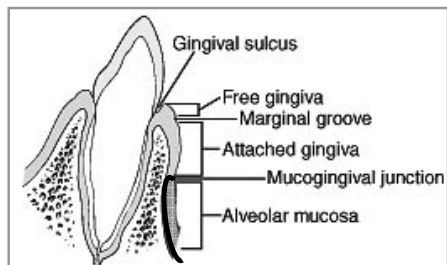
---

---

---

---

**PEDIATRIC PERIODONTAL CONDITIONS**  
**ALVEOLAR MUCOSA**



RICHARD YOON

15

---

---

---

---

---

---

---

---

---

---

**PEDIATRIC PERIODONTAL CONDITIONS** ◦  
SIX COMPONENTS

- Papillary Gingiva
- Marginal Gingiva
- Attached Gingiva
- Alveolar Mucosa
- PDL
- Alveolar Bone

- ▼ Wider
- ▼ Less dense
- ▼ Less calcified
- ▼ Larger marrow spaces

RICHARD YOON

16

---

---

---

---

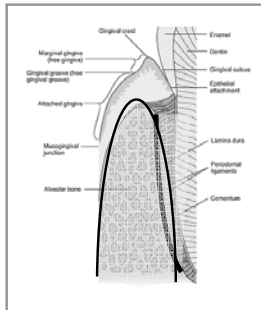
---

---

---

---

**PEDIATRIC PERIODONTAL CONDITIONS** ◦  
PERIODONTAL LIGAMENT



RICHARD YOON

17

---

---

---

---

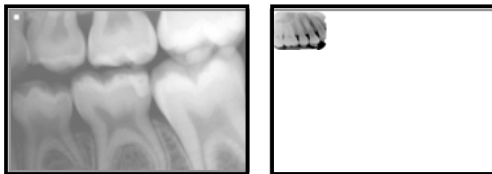
---

---

---

---

**PEDIATRIC PERIODONTAL CONDITIONS** ◦  
PERIODONTAL LIGAMENT



RICHARD YOON

18

---

---

---

---

---

---

---

---

PEDIATRIC PERIODONTAL CONDITIONS ◦  
INFLUENCE OF TOOTH ERUPTION

- ✦ Active
- ✦ Passive

RICHARD YOON

19

---

---

---

---

---

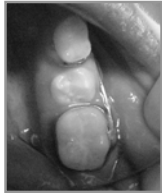---

---

---

PEDIATRIC PERIODONTAL CONDITIONS ◦  
ACTIVE ERUPTION

- ✦ Contact with functional antagonist.



RICHARD YOON

20

---

---

---

---

---

---

---

---

PEDIATRIC PERIODONTAL CONDITIONS ◦  
PASSIVE ERUPTION

- ✦ Sulcular epithelium Δ's in position.

RICHARD YOON

21

---

---

---

---

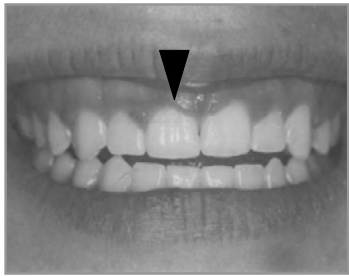
---

---

---

---

**PEDIATRIC PERIODONTAL CONDITIONS**  
 PASSIVE ERUPTION



RICHARD YOON

22

---

---

---

---

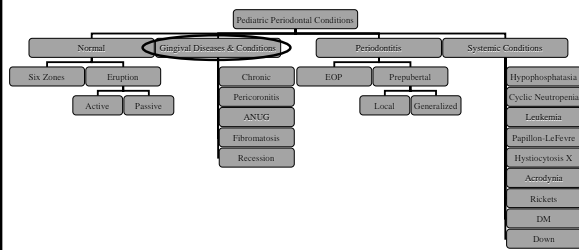
---

---

---

---

**PEDIATRIC PERIODONTAL CONDITIONS**  
 AT A GLANCE



RICHARD YOON

23

---

---

---

---

---

---

---

---

**PEDIATRIC PERIODONTAL CONDITIONS**  
 CLASSIFICATION

- Normal Findings
  - Gingivitis
  - Periodontitis
  - Systemic Conditions
- Chronic
  - Pericoronitis
  - ANUG
  - Fibromatosis & Hyperplasia
  - Recession

RICHARD YOON

24

---

---

---

---

---

---

---

---

**PEDIATRIC PERIODONTAL CONDITIONS**

FEATURES

- Normal Findings
  - Gingivitis
  - Periodontitis
  - Systemic Conditions
- Inflammation
  - Loss of Attachment
  - Bone Loss
  - Reversible
  - Prevalence

RICHARD YOON

25

---

---

---

---

---

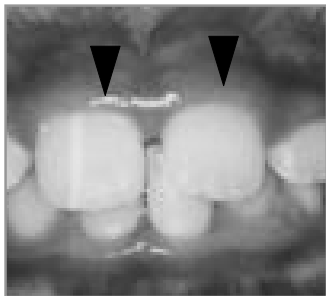
---

---

---

**PEDIATRIC PERIODONTAL CONDITIONS**

ERUPTION GINGIVITIS



RICHARD YOON

26

---

---

---

---

---

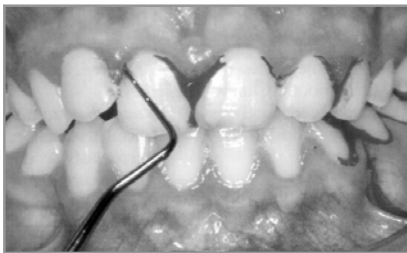
---

---

---

**PEDIATRIC PERIODONTAL CONDITIONS**

PUBERTY GINGIVITIS



RICHARD YOON

27

---

---

---

---

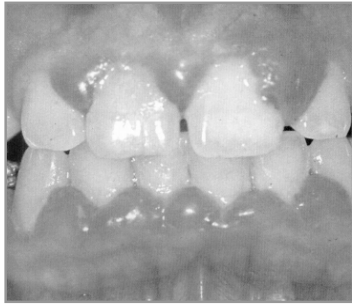
---

---

---

---

**PEDIATRIC PERIODONTAL CONDITIONS** ◦  
**PREGNANCY GINGIVITIS**



RICHARD YOON

28

---

---

---

---

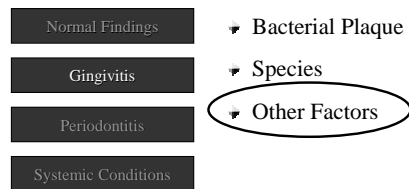
---

---

---

---

**PEDIATRIC PERIODONTAL CONDITIONS** ◦  
**ETIOLOGY**



RICHARD YOON

29

---

---

---

---

---

---

---

---

**PEDIATRIC PERIODONTAL CONDITIONS** ◦  
**ETIOLOGY: OTHER FACTORS**

Factors	Intrinsic	Extrinsic
Local	<u>Eruption/Exfoliation</u> <u>Malocclusion</u> Caries	<u>Calculus</u> <u>Appliances</u> <u>Oral Habits</u> Mouthbreathing
Systemic	Endocrine Hereditary Chronic Illness	Bacterial Viral Fungal Diet, Nutrition Medications

RICHARD YOON

30

---

---

---

---

---

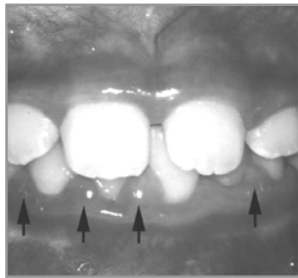
---

---

---

**PEDIATRIC PERIODONTAL CONDITIONS** ◦  
GINGIVITIS

Chronic
Pericoronitis
Acute Necrotizing Ulcerative
Fibromatosis & Hyperplasia
Recession



RICHARD YOON 31

---

---

---

---

---

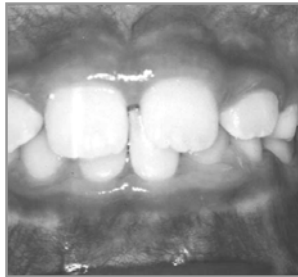---

---

---

**PEDIATRIC PERIODONTAL CONDITIONS** ◦  
GINGIVITIS

Chronic
Pericoronitis
Acute Necrotizing Ulcerative
Fibromatosis & Hyperplasia
Recession



RICHARD YOON 32

---

---

---

---

---

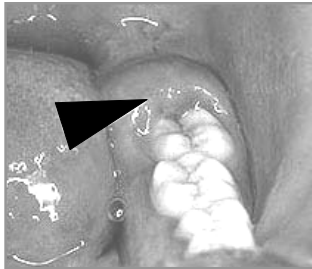
---

---

---

**PEDIATRIC PERIODONTAL CONDITIONS** ◦  
GINGIVITIS

Chronic
Pericoronitis
Acute Necrotizing Ulcerative
Fibromatosis & Hyperplasia
Recession



RICHARD YOON 33

---

---

---

---

---

---

---

---

**PEDIATRIC PERIODONTAL CONDITIONS** ◦  
GINGIVITIS

Chronic
Pericoronitis
Acute Necrotizing Ulcerative
Fibromatosis & Hyperplasia
Recession

RICHARD YOON

34

---

---

---

---

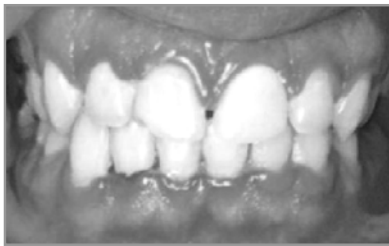---

---

---

---

**PEDIATRIC PERIODONTAL CONDITIONS** ◦  
ANUG



RICHARD YOON

35

---

---

---

---

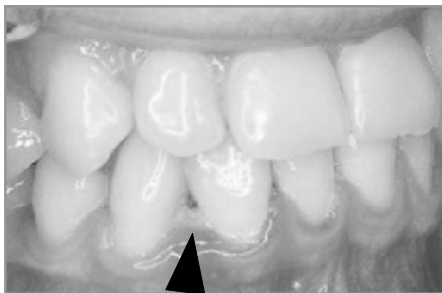
---

---

---

---

**PEDIATRIC PERIODONTAL CONDITIONS** ◦  
ANUG



RICHARD YOON

36

---

---

---

---

---

---

---

---

**PEDIATRIC PERIODONTAL CONDITIONS** ◦  
GINGIVITIS

Chronic
Pericoronitis
Acute Necrotizing Ulcerative
Fibromatosis & Hyperplasia
Recession

RICHARD YOON

37

---

---

---

---

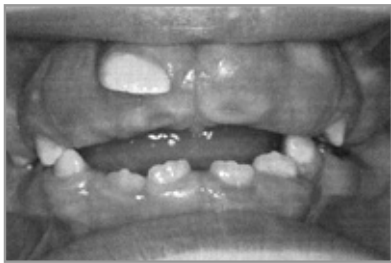---

---

---

---

**PEDIATRIC PERIODONTAL CONDITIONS** ◦  
GINGIVAL FIBROMATOSIS



RICHARD YOON

38

---

---

---

---

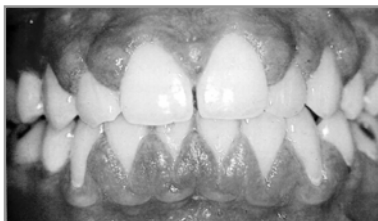---

---

---

---

**PEDIATRIC PERIODONTAL CONDITIONS** ◦  
PHENYTOIN



RICHARD YOON

39

---

---

---

---

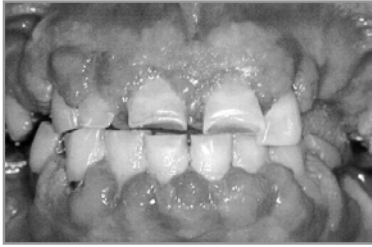---

---

---

---

**PEDIATRIC PERIODONTAL CONDITIONS** ◦  
CYCLOSPORIN



RICHARD YOON

40

---

---

---

---

---

---

---

---

**PEDIATRIC PERIODONTAL CONDITIONS** ◦  
GINGIVITIS

Chronic
Pericoronitis
Acute Necrotizing Ulcerative
Fibromatosis & Hyperplasia
Recession

RICHARD YOON

41

---

---

---

---

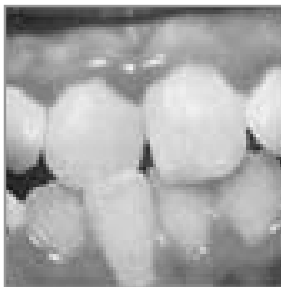---

---

---

---

**PEDIATRIC PERIODONTAL CONDITIONS** ◦  
CROSSBITE



RICHARD YOON

42

---

---

---

---

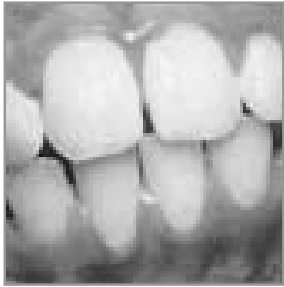
---

---

---

---

PEDIATRIC PERIODONTAL CONDITIONS  
CROSSBITE



RICHARD YOON

43

---

---

---

---

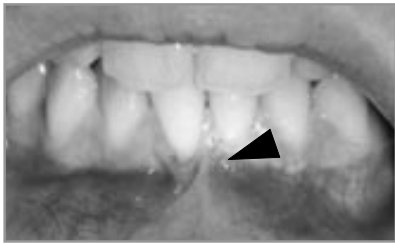
---

---

---

---

PEDIATRIC PERIODONTAL CONDITIONS  
HIGH FRENUM



RICHARD YOON

44

---

---

---

---

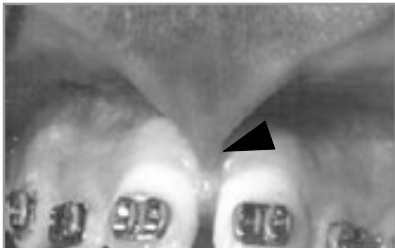---

---

---

---

PEDIATRIC PERIODONTAL CONDITIONS  
HIGH FRENUM



RICHARD YOON

45

---

---

---

---

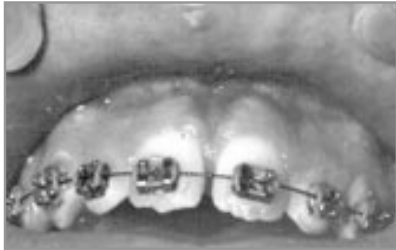---

---

---

---

**PEDIATRIC PERIODONTAL CONDITIONS**  
HIGH FRENUM



RICHARD YOON

46

---

---

---

---

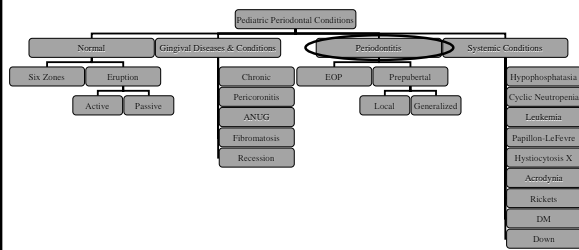
---

---

---

---

**PEDIATRIC PERIODONTAL CONDITIONS**  
AT A GLANCE



RICHARD YOON

47

---

---

---

---

---

---

---

---

**PEDIATRIC PERIODONTAL CONDITIONS**  
CLASSIFICATION

- Normal Findings      ➤ Prepubertal
- Gingivitis            ➤ Early Onset
- Periodontitis
- Systemic Conditions

RICHARD YOON

48

---

---

---

---

---

---

---

---

**PEDIATRIC PERIODONTAL CONDITIONS**

FEATURES

Normal Findings

↳ Loss of Gingival Attachment

Gingivitis

↳ Loss of Bony Support

Periodontitis

Systemic Conditions

RICHARD YOON

49

---

---

---

---

---

---

---

---

**PEDIATRIC PERIODONTAL CONDITIONS**

PREPUBERTAL PERIODONTITIS

↳ Localized

↳ Generalized

RICHARD YOON

50

---

---

---

---

---

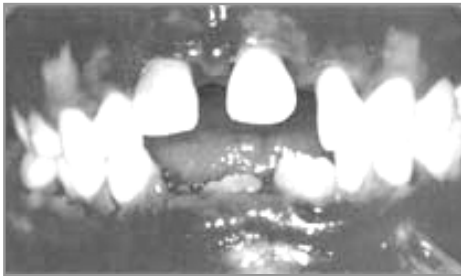
---

---

---

**PEDIATRIC PERIODONTAL CONDITIONS**

PREPUBERTAL PERIODONTITIS



RICHARD YOON

51

---

---

---

---

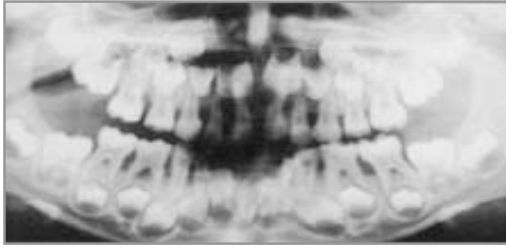
---

---

---

---

**PEDIATRIC PERIODONTAL CONDITIONS** ◦  
PREPUBERTAL PERIODONTITIS



RICHARD YOON

52

---

---

---

---

---

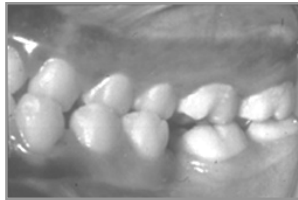---

---

---

**PEDIATRIC PERIODONTAL CONDITIONS** ◦  
EARLY ONSET PERIODONTITIS

- Localized Juvenile Periodontitis
- Generalized Juvenile Periodontitis
- Incidental Juvenile Periodontitis



RICHARD YOON

53

---

---

---

---

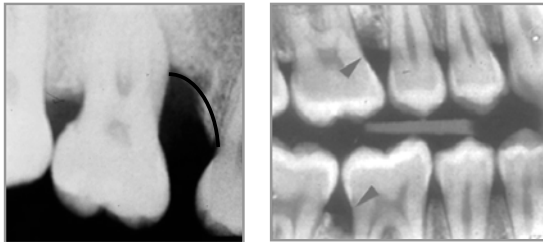
---

---

---

---

**PEDIATRIC PERIODONTAL CONDITIONS** ◦  
EARLY ONSET PERIODONTITIS



RICHARD YOON

54

---

---

---

---

---

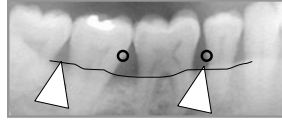
---

---

---

**PEDIATRIC PERIODONTAL CONDITIONS**  
EARLY ONSET PERIODONTITIS

- Localized Juvenile Periodontitis
- Generalized Juvenile Periodontitis
- Incidental Juvenile Periodontitis



RICHARD YOON

55

---

---

---

---

---

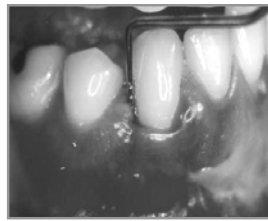
---

---

---

**PEDIATRIC PERIODONTAL CONDITIONS**  
EARLY ONSET PERIODONTITIS

- Localized Juvenile Periodontitis
- Generalized Juvenile Periodontitis
- Incidental Juvenile Periodontitis



RICHARD YOON

56

---

---

---

---

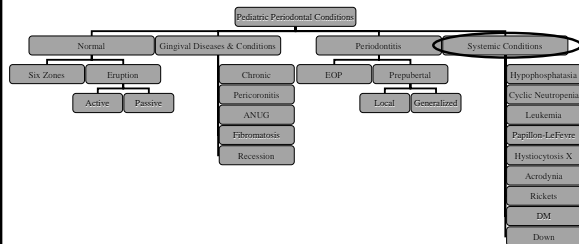
---

---

---

---

**PEDIATRIC PERIODONTAL CONDITIONS**  
AT A GLANCE



RICHARD YOON

57

---

---

---

---

---

---

---

---

**PEDIATRIC PERIODONTAL CONDITIONS**

- Normal Findings
- Gingivitis
- Periodontitis
- Systemic Conditions

- ↳ Hypophosphatasia
- ↳ Cyclic Neutropenia
- ↳ Leukemia
- ↳ Papillon-LeFèvre
- ↳ Histiocytosis X
- ↳ Down

---

---

---

---

---

---

---

---

**PEDIATRIC PERIODONTAL CONDITIONS**  
SYSTEMIC CONDITIONS

- Hypophosphatasia
- Cyclic Neutropenia
- Leukemia
- Papillon-LeFèvre
- Histiocytosis X
- Down

- ↳ Genetic Disorder
- ↳ Premature Loss
- ↳ Deficient Alkaline Phosphatase
- ↳ Permanent Dentition

---

---

---

---

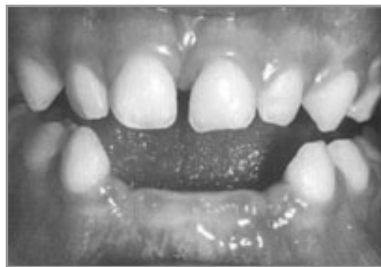---

---

---

---

**PEDIATRIC PERIODONTAL CONDITIONS**  
HYPOPHOSPHATASIA



---

---

---

---

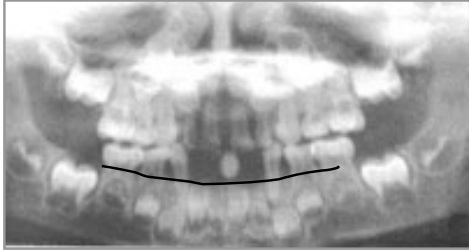---

---

---

---

**PEDIATRIC PERIODONTAL CONDITIONS** ◦  
HYPOPHOSPHATASIA



RICHARD YOON 61

---

---

---

---

---

---

---

---

**PEDIATRIC PERIODONTAL CONDITIONS** ◦  
SYSTEMIC CONDITIONS

Hypophosphatasia
Cyclic Neutropenia
Leukemia
Papillon-LeFèvre
Histiocytosis X
Down

- Rhythmic reduction
- 21 day cycles

RICHARD YOON 62

---

---

---

---

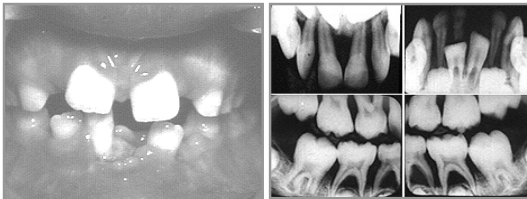
---

---

---

---

**PEDIATRIC PERIODONTAL CONDITIONS** ◦  
CYCLIC NEUTROPENIA



RICHARD YOON 63

---

---

---

---

---

---

---

---

**PEDIATRIC PERIODONTAL CONDITIONS** ◦  
SYSTEMIC CONDITIONS

Hypophosphatasia
Cyclic Neutropenia
Leukemia
Papillon-LeFèvre
Histiocytosis X
Down

✦ Gingival enlargement

RICHARD YOON

64

---

---

---

---

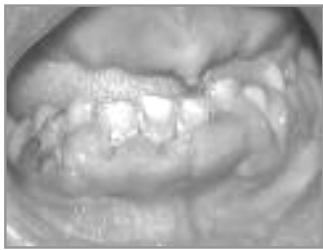
---

---

---

---

**PEDIATRIC PERIODONTAL CONDITIONS** ◦  
LEUKEMIA



RICHARD YOON

65

---

---

---

---

---

---

---

---

**PEDIATRIC PERIODONTAL CONDITIONS** ◦  
SYSTEMIC CONDITIONS

Hypophosphatasia
Cyclic Neutropenia
Leukemia
Papillon-LeFèvre
Histiocytosis X
Down

✦ Hyperkeratosis

✦ Premature loss of 1° & 2°

✦ A.A.

RICHARD YOON

66

---

---

---

---

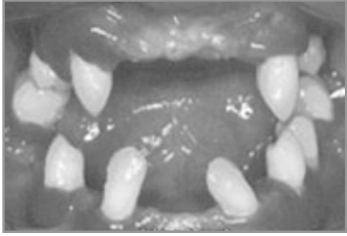---

---

---

---

**PEDIATRIC PERIODONTAL CONDITIONS** ◦  
PAPILLON-LEFÈVRE



RICHARD YOON

67

---

---

---

---

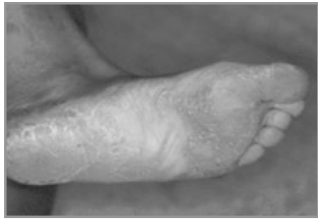---

---

---

---

**PEDIATRIC PERIODONTAL CONDITIONS** ◦  
PAPILLON-LEFÈVRE



RICHARD YOON

68

---

---

---

---

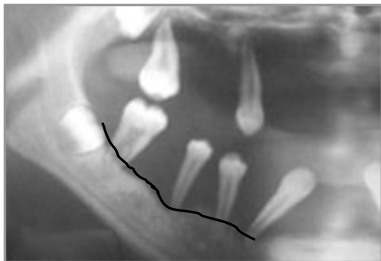---

---

---

---

**PEDIATRIC PERIODONTAL CONDITIONS** ◦  
PAPILLON-LEFÈVRE



RICHARD YOON

69

---

---

---

---

---

---

---

---

**PEDIATRIC PERIODONTAL CONDITIONS** ◦  
SYSTEMIC CONDITIONS

Hypophosphatasia
Cyclic Neutropenia
Leukemia
Papillon-LeFèvre
Histiocytosis X
Down

- Necrotic gingivitis
- Bony loss of the molars
- Radiolucent lesions

RICHARD YOON

70

---

---

---

---

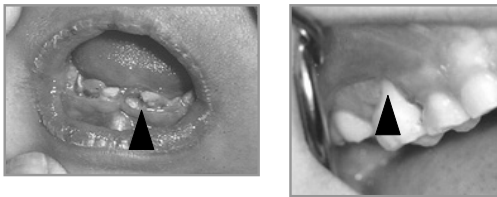
---

---

---

---

**PEDIATRIC PERIODONTAL CONDITIONS** ◦  
HYSTIOCYTOSIS X



RICHARD YOON

71

---

---

---

---

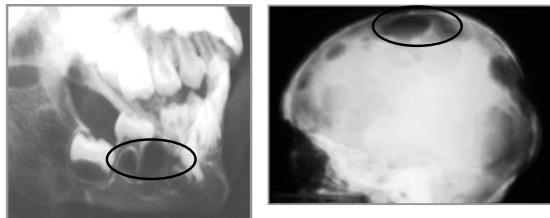
---

---

---

---

**PEDIATRIC PERIODONTAL CONDITIONS** ◦  
HYSTIOCYTOSIS X



RICHARD YOON

72

---

---

---

---

---

---

---

---

**PEDIATRIC PERIODONTAL CONDITIONS** ◦  
SYSTEMIC CONDITIONS

Hypophosphatasia
Cyclic Neutropenia
Leukemia
Papillon-LeFèvre
Histiocytosis X
Down

✦ Trisomy 21

RICHARD YOON

73

---

---

---

---

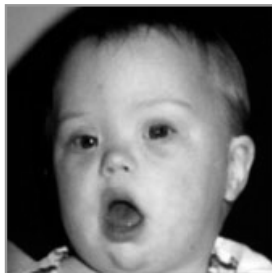---

---

---

---

**PEDIATRIC PERIODONTAL CONDITIONS** ◦  
TRISOMY 21



RICHARD YOON

74

---

---

---

---

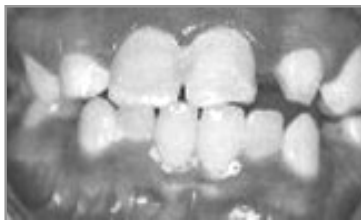
---

---

---

---

**PEDIATRIC PERIODONTAL CONDITIONS** ◦  
TRISOMY 21



RICHARD YOON

75

---

---

---

---

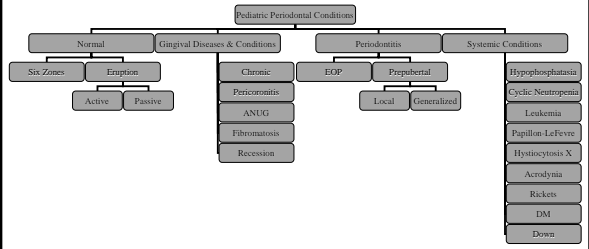
---

---

---

---

**PEDIATRIC PERIODONTAL CONDITIONS**  
 AT A GLANCE



RICHARD YOON

76

---



---



---



---



---



---



---



---