

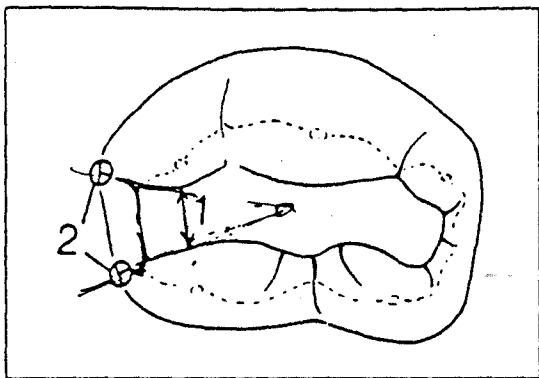Fig 15-14 External view of a Class II amalgam preparation. (The numbers correspond to the numbers in the technique description in the text.)

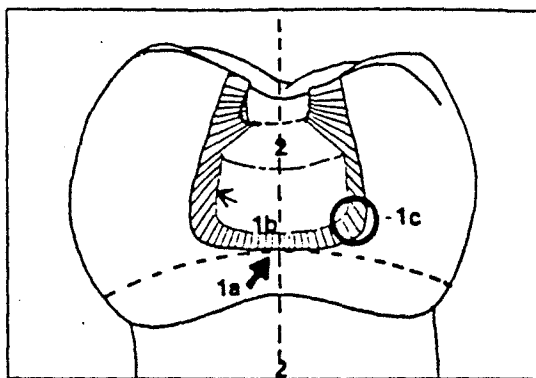


Fig 15-15 Cross-sectional view of a Class II amalgam preparation. (The numbers correspond to the numbers in the technique description in the text.)

than at the occlusal opening. This convergence aids in retention of the restorative material.

3. Slightly round the pulpal floor. All internal line angles should be rounded.
4. Establish a sharp cavosurface angle in the lateral walls with the No. 169L bur. The walls are parallel or slightly undercut to the external surfaces of the tooth. A word of caution: Watch the tip of the No. 169L bur to prevent scoring the floor of the preparation. The sharp cavosurface angle is an asset to improve carving and polishing, and reduce marginal failure (Mathewson, 1972). If the active caries has not been removed during cavity preparation, do so now. Use a No. 4 or 6 round bur in a slow-speed handpiece. A large spoon excavator works as well. Rinse the preparation with water. Inspect for caries removal, sharp cavosurface margins, and retention.

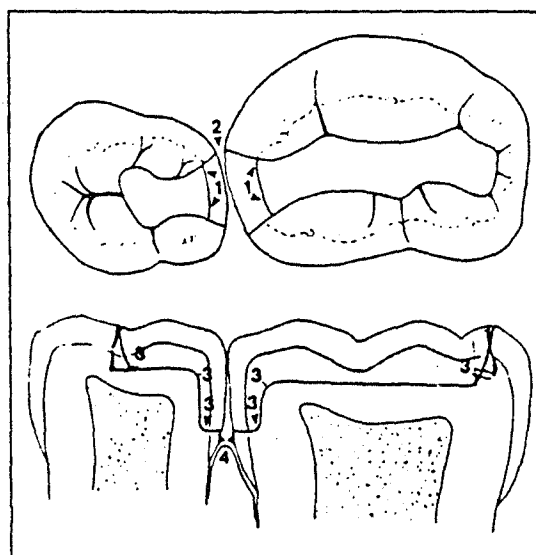


Fig 15-16 Internal and external views of two Class II primary molar restorations. (The numbers correspond to the numbers in the technique description in the text.)

Class II cavity preparation

1. Complete a Class I cavity outline as described.
2. Use a No. 330 bur to extend the occlusal outline through the marginal ridge. If two primary molars are being done together back to back, extend the proximal box into self-cleaning areas. Attempt to leave 90° cavosurface margins. The isthmus (narrowest part of the occlusal outline near the proximal box) is approximately one half to one third the width of the occlusal surface.
3. Extend the No. 330 bur into the proximal surfaces. Keep the bur parallel to the long axis of the tooth. Move the bur in a pendulating motion from lingual to buccal.
4. Extend the proximal box gingivally beneath the contact area to the interproximal area. This area is determined by the clearance of an explorer tip.
5. The axial wall, as determined by carious lesion depth, should follow the contour of the tooth.
6. Use the enamel hatchet to remove any overhanging

enamel in the proximal box. Overuse of hand instruments is not indicated. Effective use of the bur can accomplish the same end result much faster. Rinse the debris from the cavity preparation. Check the following items:

Occlusal view (Fig 15-14)

1. Form the isthmus (most narrow portion of the occlusal outline nearest the proximal surface) so that it is one half the width of the occlusal table and connects the proximal with the occlusal dovetail.
2. Curve the proximal wall gently, creating an angle 90° to the axial surface of the tooth, if possible. The proximal extensions are governed by the adjacent tooth and determined by the clearance of an explorer tip.

Table 15-1 Comparison of effectiveness of pulpal protection materials

	Cavity varnishes	Cavity liners	
		Ca(OH) ₂ [*]	ZOE [†]
Sealing of margins	Yes, 48 hours	Not known	Yes
Sealing of dentinal tubules ^c	Some	Yes	Yes
Prevention of dentin discoloration	Not known	Yes	Yes
Prevention of thermal sensitivity	No	Some	Yes
Biologic response in dentin (sclerosis)	No	Yes	Some
Hardening of surface layer	No	Yes	Yes
Visibility of material on enamel margins	Poor	Good	Good
Principle in action	Mechanical	Biologic	Biologic

^{*}Calcium hydroxide.

[†]Zinc oxide-eugenol.

Cross-section proximal box area (Fig 15-15)

1. In establishing the gingival floor, keep in mind that (a) it is even with or slightly below the gingiva, as determined by the carious lesions; (b) it is perpendicular to the long axis of the tooth; and (c) it has rounded line angles.
2. Keep the proximal box in an occlusogingival direction roughly parallel to the long axis of the tooth.

Occlusal and internal views (Fig 15-16)

The proximal box area:

1. Gently curves buccolingually to follow the contour of the proximal surface.
2. Extends so an explorer tip can pass through the embrasure.
3. Has gently rounded axiopulpal line angles, as do all line angles.
4. Has no bevel at the gingival margin.

Proximal retentive grooves are not indicated. There is the possibility of a pulpal exposure. Studies have shown that, in primary teeth, retentive grooves do not reduce the incidence of marginal failure or gross fracture (Mathewson and Lu, 1975).

Failures of amalgam restorations

Marginal failure of amalgam restorations in primary posterior teeth is often blamed on the restorative material. However, amalgam has been placed in primary teeth where cavity preparations have been overextended. The amalgam is expected to perform beyond its physical limitations. A number of studies have demonstrated that if excessive tooth structure is removed, marginal failure increases (Birtcil et al, 1981; Larson et al, 1980; Mahler and Marantz, 1980; Blaser, 1985). Dawson et al (1981), reviewing 280 restorations in primary teeth, concluded that nearly 70% of the multisurface amalgam restorations needed replacement. These studies support the philosophy that amalgam should not be placed in primary teeth with more than two surfaces of dental caries.

Materials used with amalgam restorations

Reviewing the physical properties and uses of dental restorative materials here is an necessary evil. Admittedly a dry subject, it is the basis of success in restorative dentistry, and dentistry for children is no exception. The following section is a brief review of the pertinent information with the emphasis on the clinical applications (Table 15-1).

Cavity varnishes

A cavity varnish is a solution of one of several resins in an organic solvent. Copal or nitrated cellulose are dissolved in organic solvents such as alcohol, benzene acetone, or chloroform.

When carious lesions are removed from a tooth, there is a histologic response in the pulp as a result of the carious process and the trauma of cavity preparation. Dentin should be considered a vital extension of the pulpal tissue. The primary use of cavity varnishes is to minimize this insult and assist the vital pulpal tissue in the recovery process. A varnish or resin layer is formed on the dentin and tooth by evaporation of the solvent, leaving a thin, semipermeable membrane. The intent of this membrane is to seal the exposed dentinal tubules, protecting the underlying pulp from further irritation.

Cavity varnish is used to reduce marginal leakage on the cavosurface margins of amalgam restorations (Andrews and Hembree 1975; Yates et al, 1980). A thin film is placed on the margins before the insertion of the restoration. This varnish layer seems to serve as a wedge between the amalgam and cavity wall. Therefore, it is easy to leave an excess of amalgam on the margins after carving, with the amalgam sticking to the varnish material.

If a cavity liner containing calcium hydroxide, zinc oxide-eugenol, or polycarboxylate is used, a cavity varnish is placed afterward.

Placement of a cavity varnish beneath a composite resin is contraindicated unless recommended by the

T BAND MATRIX BAND

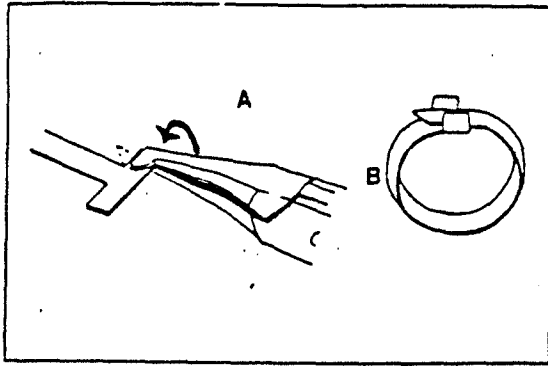


Fig 15-26 (A) Bend the T of the band (B) to form a clasp to assist in the band's formation.

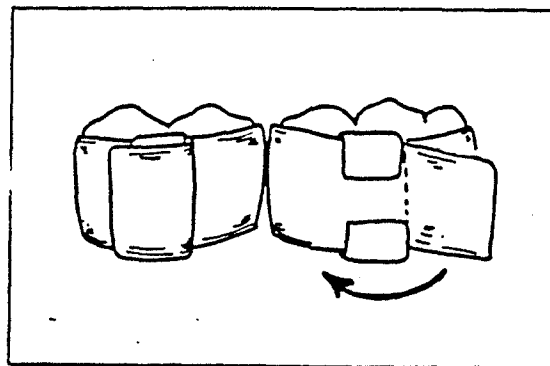


Fig 15-27 Fold the tab over to form the band.

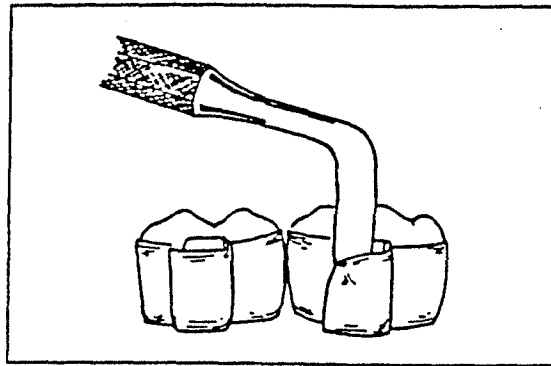


Fig 15-28 Remove the T-band by loosening the tab.

Use of the T Matrix Band

1. With the No. 110 pliers, bend the flanges of the "T" upward (Fig. 15-26, A). Use a mirror handle or the handle of the pliers to form a circle.
2. Fold the T-wings over the circle formed. The wings should be loose enough for a sliding joint. Adjust the band so it is approximately smaller than the tooth to be restored (Fig. 15-26B). Place the matrix on the tooth with the folded joint on the buccal side of the tooth.
3. Hold the band with one finger. Pull the tab tight with No. 110 pliers or your finger. Fold the tab back over the joint (Fig. 15-27).
4. Remove the band. Flatten the joint with No.110 pliers. Replace the band on the tooth. Wedge tightly.
5. When the restorative procedure is finished, remove the band by raising the tab over the joint and loosening the T part of the bands (Fig. 15-28). Remove the wedge. Slide the band occlusally through the contact.