

# Orofacial Trauma Management

## PATIENT ASSESSMENT AND DOCUMENTATION

Martin J. Davis, D.D.S.

**I**t is estimated that 30 percent of all children in the United States will at some time experience orofacial trauma.<sup>1</sup> A related statistic shows that about 25,000 children die in the United States each year as a direct result of head injury. Other sequelae, such as developmental delays, seizure disorders and physical disabilities, are the result of head trauma.<sup>2</sup>

When a child with dental trauma and related orofacial injuries presents on an acute emergency basis to a doctor's office, it is hoped the doctor is prepared to address the luxation, avulsion, suturing or other emergent problems. But in today's high-speed and litigious society, the increased incidence of related neurological sequelae also demands appropriate, detailed documentation—which has added new dimensions to the doctor's professional obligations.

There have been incidents in which a child presents first to a dental office for care after a traumatic incident. Appropriate and excellent oral health emergency care is initiated to repair the fractured tooth or to replant the avulsed permanent tooth. But the acute medical needs of the child, such as emergency medical intervention for a subdural hematoma, are not assessed or attended, and a true medical crisis ensues.

Recently, a child went to her dentist's office subsequent to high-force orofacial trauma. The doctor accurately assessed the trauma treatment needs of the patient and began to provide meticulous dental care, but he failed to keep in perspective the total systemic status of the patient. The child was experiencing a subdural hematoma and soon lost consciousness. Fortunately, she was treated and resuscitated at the local emergency room.

Our literature, especially in

### ■ ABSTRACT ■

*New technologies and treatments for managing children with orofacial trauma are constantly updated and available to the practitioner through current literature. What often fails to be appreciated, however, is that orofacial injury is a subset of head trauma and may have systemic emergent considerations that supersede the oral conditions being addressed. The complexity of a thorough assessment of the child from both medical and dental standpoints requires a systematic approach, which in turn can be guided by an appropriate document for inclusion in the chart. Further, such a document will serve as an important record should future civil litigation ensue from the traumatic incident.*

**The medical maxim  
"never treat a stranger"  
certainly applies in the case  
of orofacial trauma.**

pediatric dentistry, oral and maxillofacial surgery, and endodontics, is replete with current diagnostic approaches and treatment modalities for trauma. The best approaches to addressing the avulsed permanent tooth or the best materials for repair of the fractured incisal angle are frequently updated in the literature and in continuing education courses. And the latest techniques are readily available. What is not so available is guidance on evaluating the whole child with orofacial and, therefore, head trauma, and assistance with constructing appropriate records.

**There's Value in Records**

Carefully structured and detailed records guide practitioners in caring for the individual patient from assessment and diagnosis to the best treatment, accurate prognosis and future care. They serve also in structuring future trauma care for other patients, reflecting what has been learned from previous cases—if records are carefully maintained and reviewed regularly in the context of treatment outcomes over time. Whether a particular material

used in an emergency to protect a fractured incisal angle is retained well until the restorative appointment and is the most suitable material depends on a review of previous records of the use of the material.

Adequate records can also serve as a basis for contributions to critically needed clinical dental literature. With carefully constructed records, the clinician moves from the "in my hands it works," non-scientific approach to well documented treatment modalities.

Finally, a discomforting reality of the current state of health care is litigation. It is hoped that in the case of treatment of a child who has had orofacial trauma, the practitioner is not facing professional liability or malpractice litigation, but rather is being called to testify as the primary care provider with the best overview of the injuries sustained. It's possible that practitioners may be called years after the accident to provide expert testimony on the extent of the injuries, necessary treatment, cost, suffering and inconvenience experienced by the patient and family, and prognos-

is for the patient. If their records are not complete, it is impossible to provide useful information in this usually combative setting. When the case finally comes to trial, memory can not be relied upon to provide information that professionals are obligated to have available.

**Know Your Patient**

To address the first issue, the medical well-being of the patient, it is necessary to be prepared to assess the patient's status in an orderly fashion. The medical maxim "never treat a stranger" certainly applies in the case of orofacial trauma.

Obtaining a detailed and accurate medical history during what is often an emotionally difficult moment for the child and parents is a must. Considerations such as current medications, systemic disease, tetanus immunity status, indications for antibiotic coverage, and other medical concerns must be noted and carefully documented in the treatment record. Additionally, the immediate overall well-being of the child must be assessed, even though the child may be on the verge of hysteria because of discomfort, excitement or the fear of permanent disfiguration.

Determining the neurological status of the patient is critical; and it can be readily done by the practitioner who is prepared. To begin the repair of a fractured incisor of a child who is experiencing the onset of symptoms of neurological determination is inexcusable.

To understand the potential extent of injuries from the trauma

matic incident, a history of the incident is required. Amnesia of the event is often indicative of the severity of the blow and may reveal the loss of consciousness and, therefore, the possibility of brain contusion, subdural hematoma or other serious problems.

A patient who presents with nausea, vomiting, drowsiness or blurred vision calls attention to greater issues than the splinting of a luxated incisor. Although it may be difficult, it is essential to assess whether the child is oriented to person, place and time. The nose and the ears should be observed for any possible cerebrospinal fluid leakage, which would be indicative of skull fracture. Careful examination for extraoral or intraoral lacerations is mandatory; and if there are through-and-through lacerations, antibiotics should be prescribed.

Facial bone fractures need to be ruled out through careful palpation and inspection for symmetry and normal occlusion. Finally, baseline temperature, pulse, blood pressure and respiratory rate should be noted, again within the context of the child's emotional state at the time.

The final area for neurological assessment is a quick cranial nerve examination.

● Are the extra-ocular muscles intact and functioning appropriately (EOMI)? For instance, can the patient track a finger moved vertically and horizontally through the visual field with the eyes remaining in tandem?

● Are the pupils equal and round and do they react to light and accommodate (PERRLA)?

● Is sensory function normal? (This can be measured readily through light contact to various areas of the face, which indicates that Cranial Nerve V has not been damaged.)

Finally, symmetry of motor function, including that of the tongue, should be assessed by

having the patient attempt to frown, smile, extrude the tongue and perform similar voluntary muscular movements.

Though some practitioners might say these "medical" assessments are incidental and time-consuming and have the potential of annoying the patient or

Columbia University  
School of Dental & Oral Surgery  
**TRAUMA TREATMENT FORM**

Patient's Name \_\_\_\_\_ Date of Birth \_\_\_\_\_  
Date of Examination \_\_\_\_\_ Age \_\_\_\_\_  
Medical Alert \_\_\_\_\_  
History of Injury: \_\_\_\_\_

Date & Time of Injury \_\_\_\_\_ time elapsed since injury \_\_\_\_\_  
Place of Injury \_\_\_\_\_  
How injury occurred \_\_\_\_\_  
Previous history of injury: Yes \_\_\_\_ No \_\_\_\_

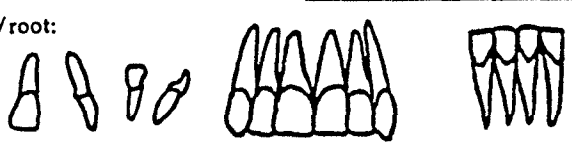
Describe: \_\_\_\_\_

Details of Examination:  
Soft Tissue Observation:  
Laceration: Lip \_\_\_\_\_ Gingivae \_\_\_\_\_ None \_\_\_\_\_  
Ecchymosis: Lip \_\_\_\_\_ Gingivae \_\_\_\_\_ None \_\_\_\_\_  
Swelling: Lip \_\_\_\_\_ Gingivae \_\_\_\_\_ None \_\_\_\_\_

Describe: \_\_\_\_\_

Occlusion (Angle classif.) \_\_\_\_\_ Overjet \_\_\_\_ mm Overbite \_\_\_\_ %  
Mobility/Avulsion \_\_\_\_\_ Displacement \_\_\_\_\_  
Fracture \_\_\_\_\_ Color \_\_\_\_\_

Draw injury on tooth/root:



Pulp exposed: Yes \_\_\_\_ No \_\_\_\_ Size of Exposure \_\_\_\_\_  
Adjacent and opposing teeth: (describe if injured) \_\_\_\_\_  
Radiographic Data:  
Pulp size: Large \_\_\_\_\_ Average \_\_\_\_\_ Small \_\_\_\_\_  
Evidence of calcific degeneration: Yes \_\_\_\_ No \_\_\_\_  
Root development: 1/3 \_\_\_\_ 1/2 \_\_\_\_ 2/3 \_\_\_\_ Complete \_\_\_\_\_  
Periapical pathology: Yes \_\_\_\_ No \_\_\_\_  
Internal/External Resorption: \_\_\_\_\_  
(over)

Figure 1. Front of Trauma Treatment Form

parents, the reality is that all parties involved will appreciate the professional ability and concern expressed by such thorough examination and caution.

**Multiple Injuries**

Intracranial injury is not the only possible untoward outcome of a high-speed bicycle or in-line skat-

ing accident. The patient should be carefully observed for other possible injuries, such as fractures or sprains throughout the body. Additionally, blood supply impaired by arterial tears, other internal bleeds, possible pneumothorax due to fractured ribs, or even delayed complications from fractures, and such injuries result-

ing in pulmonary emboli, fat emboli, or disseminated intravascular coagulation need to be considered. More simply stated, attention continually must be directed to the overall status of the child with a head injury.

Direct injuries to the respiratory system or to the brain area in the medulla responsible for driving respiration can lead to alterations in general body chemistry, such as ketoacidosis or other metabolic problems, which may manifest considerably later than acute hypoxia or hypocarbia. Tangentially, it is important to be aware that increased CO<sub>2</sub> elevates cerebral blood volume and therefore adds to intracranial pressure. This in turn causes a feedback effect that will further compromise respiration.

**Form Provides Guidance**

The second major issue in temporary trauma care, that of appropriate documentation, can be addressed by using a "trauma treatment form" (Figure 1). Such form is in use in both the predoctoral and postdoctoral pediatric settings of the Columbia University School of Dental and Oral Surgery. It can lead the clinician through the careful assessment of all relevant aspects of the injuries and the development of treatment and follow-up protocols. It helps prompt the clinician to remember to assess necessary areas, such as hard and soft tissue injury, appropriate radiographic needs, accurate descriptions of all injuries, a current and future endodontic considerations.

The appended trauma treatment form is recommended.

**TRAUMA TREATMENT FORM Page 2**

Root Fracture:  
None noted \_\_\_\_\_ Apical \_\_\_\_\_ Middle \_\_\_\_\_ Cervical 1/3 \_\_\_\_\_

Alveolar fracture: Yes \_\_\_\_\_ No \_\_\_\_\_ Where: \_\_\_\_\_

Describe: \_\_\_\_\_

Patient's Symptoms:

Pain on mastication: Yes \_\_\_\_\_ No \_\_\_\_\_ Reaction to light percussion: Yes \_\_\_\_\_ No \_\_\_\_\_

Reaction to thermal change: Yes \_\_\_\_\_ No \_\_\_\_\_ Describe: \_\_\_\_\_

Other: \_\_\_\_\_

Reaction to electric pulp test: Yes \_\_\_\_\_ No \_\_\_\_\_

**Readings**

7	8	9	10	7	8	9	10	7	8	9	10
26	25	24	23	26	25	24	23	26	25	24	23

\*Emergency appointment  
Date

Follow-up appointment  
Date

Recall appointment  
Date

Splint Indicated? \_\_\_\_\_ Type: \_\_\_\_\_

Emergency Treatment/Radiographs: \_\_\_\_\_

Follow-up Exam and Treatment: \_\_\_\_\_

\*N.B.: Neurogenic Shock in pulp may give unreliable readings during first 48 hours.

Figure 1. Back of Trauma Treatment Form

use as is or with modification in all dental offices; it is not copyrighted.

The practitioner's primary concern should be with preventing injury. In this regard, mouthguards are one of the most effective preventive devices. In addition to offering protection to the teeth, soft tissues and other intraoral structures, an appropriately fitted and regularly worn mouthguard helps cushion blows to the head, especially those directed to the lower face. This protection will reduce the incidence of intracranial and cervical injuries.

Clear evidence of the value of mouthguards was presented in a study by R.A. Flanders and M. Bhat.<sup>3</sup> The authors found that

male and female soccer players are more likely to sustain orofacial injuries than are football players, and that a basketball player's risk of orofacial injury is twice that of a football player.

This is a direct reflection of the mandatory use of mouthguards in football, seemingly a far more injury-prone sport. This requirement has resulted in the reduction of orofacial injuries in football from 50 percent of total sports-related injuries to less than one percent.

Another preventive measure is the pre-participation examination at the beginning of each season. It should be required or possibly provided by a "team" dentist. Such an examination can detect injury-prone children, es-

pecially those with protrusive maxillary anterior teeth or other predisposing factors for injuries. Additionally, a further service is provided in identifying children in need of other oral health care.

Further information about current trauma care and assessment of the child with traumatic orofacial injuries is available from Andreassen's third edition of the "Textbook and Color Atlas of Traumatic Injuries to the Teeth."<sup>1</sup> □

#### References

1. Andreassen JO, Andreassen FM. Textbook and Color Atlas of Traumatic Injuries to the Teeth, ed. 3. Copenhagen: Munksgaard;1991: 19-45.
2. Hunger JG. Pediatric maxillofacial trauma. Ped Emerg Med, Ped Clin NA. Oct. 1992;39:122-48.
3. Flanders RA, Bhat M. The incidence of orofacial injuries in sports. JADA 1995;126:491-96.

## Save \$\$\$ On MALPRACTICE INSURANCE!

- Low-Cost Coverage
- 10% Risk Management Credit
- Additional - Part-Time - New Dentist
  - Faculty Premium Credits
- No Consent Election — 5% Credit
- Choice of Limits From \$100,000 To \$1,000,000
- Occurrence & Claims-Made Policies
- Switch To NSDP Without Having To Purchase "Tail Coverage"
- Free Tail Age 55 Or Older & Insured In NSDP Program 5 Years
- OPD State Board License Protection
  - Do's & Don'ts Guide
  - Telephone Hotline Advisory Service
  - Free In-Office Legal Counseling
  - Free Representation At Interrogations
- Loss Prevention Support Services
  - Crisis Telephone Hotline
  - Loss Prevention Newsletter
  - Risk Management Manual
  - Seminars
  - Records Management
  - Individual Practice Risk Audit, and more!

**0%**  
INTEREST  
PREMIUM  
FINANCING

NATIONAL SOCIETY OF  
DENTAL PRACTITIONERS

**1-800-237-9429**

Dr. Davis is dean for student and alumni affairs, Columbia University School of Dental and Oral Surgery and past president of the American Academy of Pediatric Dentistry.

