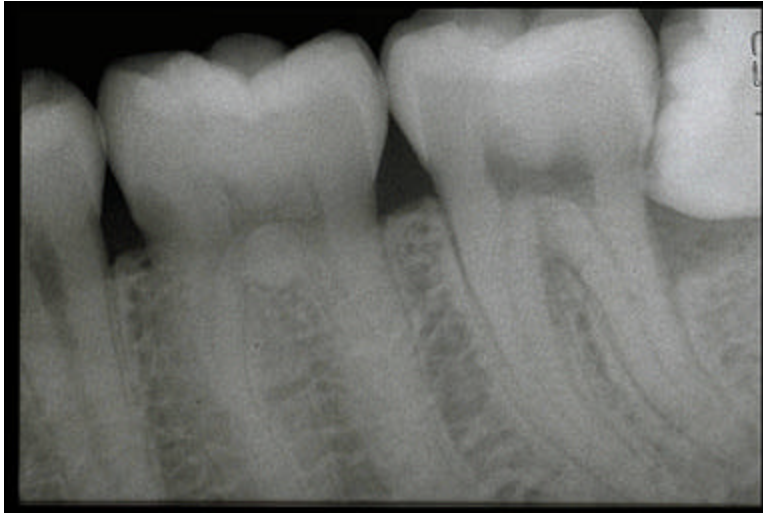


Circle ONLY the most appropriate answer

Course Director - Neill Serman



1. The anatomic anomaly noted in this periapical radiograph of the mandibular posterior region
  - a. pulp stone
  - b. taurodontia
  - c. impacted third molar
  - d. pericoronitis
  - e. enamel pearl \*

A pulp stone will be completely within the pulp chamber

Note - pericoronitis and an impacted tooth are NOT anatomic anomalies but pathology

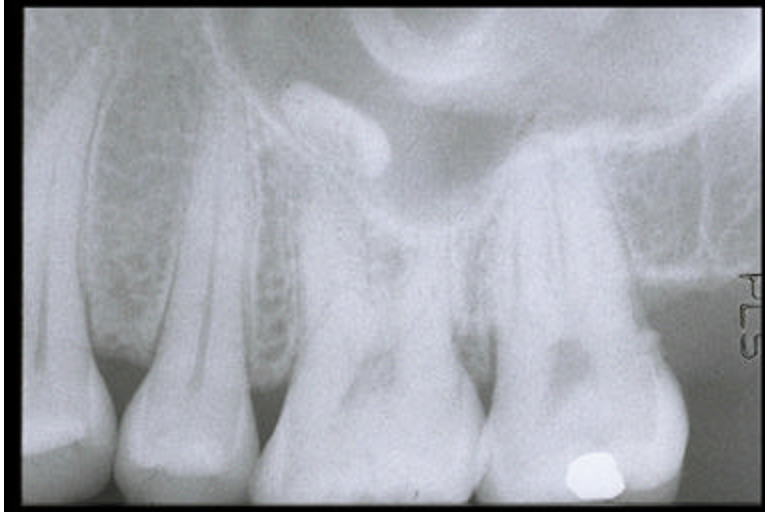
2. To obtain a better radiographic view of the third molar, what view would you take?
  - a. PA
  - b. OM
  - c. Submentovertex
  - d. lateral oblique \*
  - e. cross sectional

If the dentist has a pan machine, that view would be convenient but that is not one of the answers.

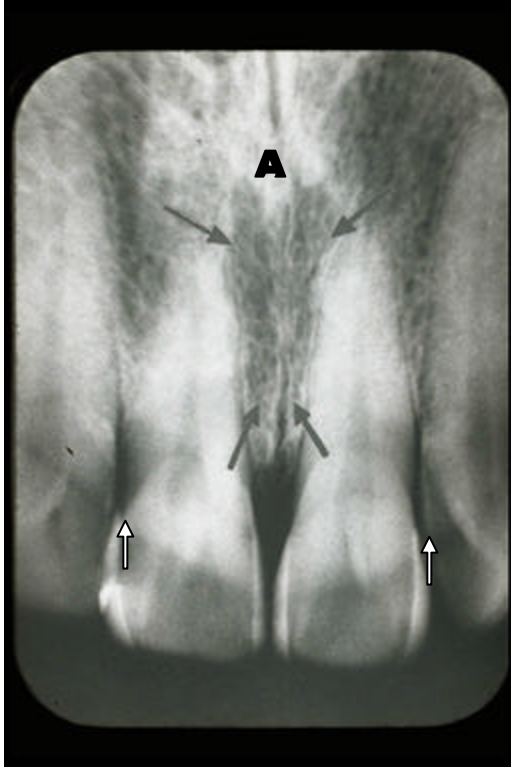
3. The first mandibular molar showing a lucency mesially should be -
  - a. extracted because the caries extends in the pulp
  - b. restored with an MO amalgam because of the interproximal caries
  - c. restored with an MO amalgam because of the root caries
  - d. should be observed because of the artifact \*
  - e. should be crowned.

Caries appears *immediately* apical to the contact point. Note this lucency is at the height of the alveolar bone, called cervical burn out.

4. How will you correct the technical error seen on this radiograph?
- increase vertical positive angulation
  - increase vertical negative angulation
  - decrease vertical negative angulation \*
  - decrease vertical positive angulation
  - change horizontal angulation



1. Identify the almost horizontal, linear opacity seen on the floor of the maxillary sinus in this periapical projection.
- supernumary tooth
  - root remnant
  - antrolith \*
  - odontoma
  - sialolith
2. Identify the opaque, inverted U structure diagonally above and posterior to that opacity
- torus palatinus
  - base of the zygoma \*
  - torus mandibularis
  - condensing osteitis
  - floor of the orbit
- A solid opacity could be a torus



1. In this periapical radiograph of the maxillary anterior region, the lower black arrows are indicating a linear lucency which is -

- a. fracture
- b. static electricity
- c. nutrient canal
- d. artifact
- e. suture \*

the mid palatal suture which is NOT a nutrient canal

2. The upper arrows are indicating a round lucency. Identify -

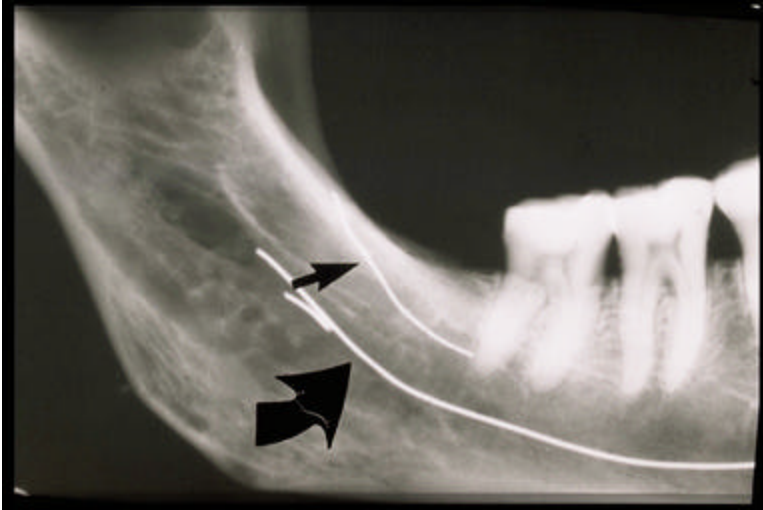
- a. radicular cyst
- b. globulomaxillary cyst
- c. artifact
- d. nutrient foramen \*
- e. suture

the incisive foramen

3. The open arrows are indicating

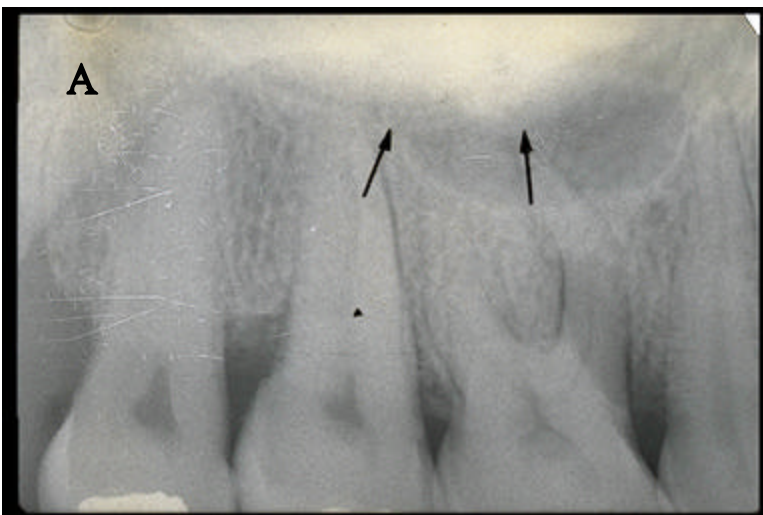
- a. outline of tongue
- b. outline of nose
- c. lip line \*
- d. fractures
- e. hypocalcifications

4. The opacity "A" should be recognized as
- anterior nasal spine
  - torus palatinus
  - inferior concha
  - nasal septum



- In relationship to the apex of the third mandibular molar tooth, the mandibular canal usually lies
  - directly inferior
  - inferior and buccally \*
  - inferior and lingually
  - any of the above
- The upper arrow is indicating
  - fracture
  - external oblique line
  - aberrant nerve canal \*
  - internal oblique line

A wire was placed in the canal found on a dry mandible

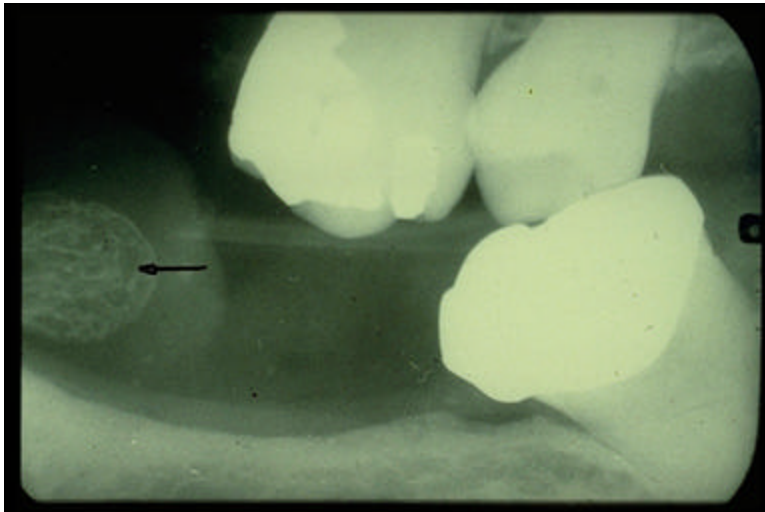


- Identify the opacity at the top of the radiograph to which the black arrows are pointing -

- a. torus palatinus \*
- b. base of the zygoma
- c. torus mandibularis
- d. condensing osteitis
- e. floor of the orbit

2. The anatomic structure indicated by the "A"

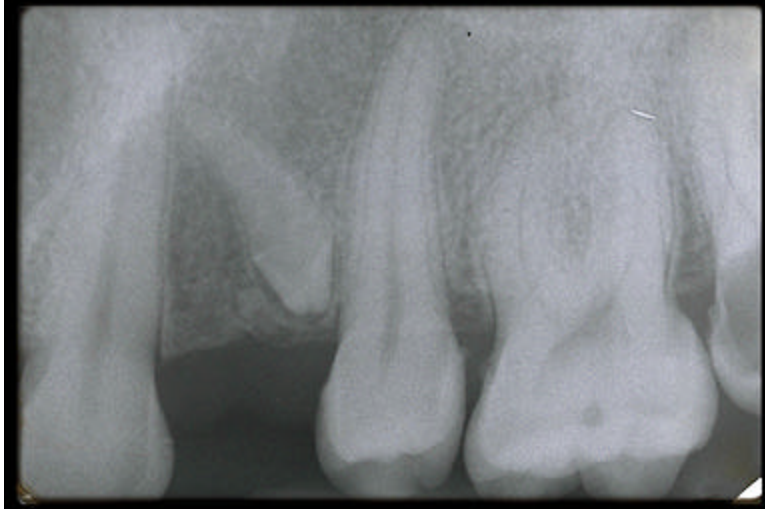
- a. condyle
- b. hamular process
- c. lateral pterygoid plate
- d. coronoid process \*



1. In this BW radiograph, the arrow is pointing to a(n)

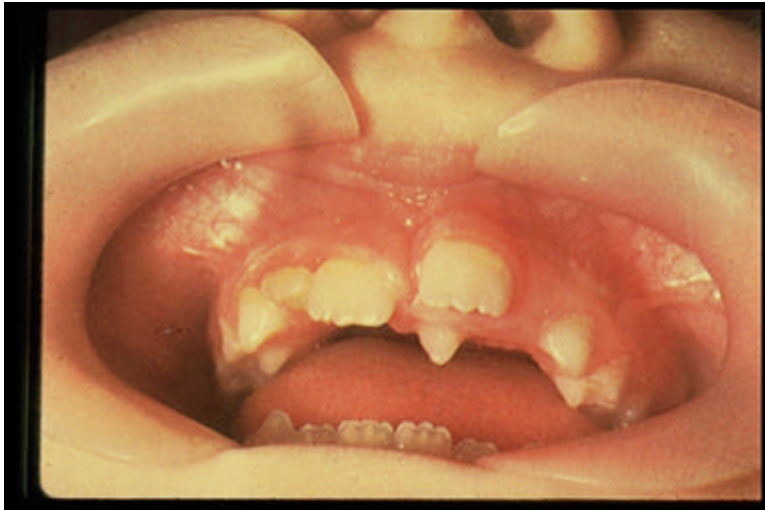- a. compound odontoma
- b. supernumary tooth
- c. complex odontoma
- d. finger \*
- e. sialolith

This happens when NOT using aligning instruments



11. Applying the basic principles you were taught, the impacted tooth most likely is
- first premolar
  - second premolar
  - supernumerary tooth \*
  - root remnant
  - odontoma

The **last** tooth in the series is the one that is missing or peg shaped. This is a diminutive tooth and not a root because the enamel can be seen. A root remnant can be eliminated from consideration.



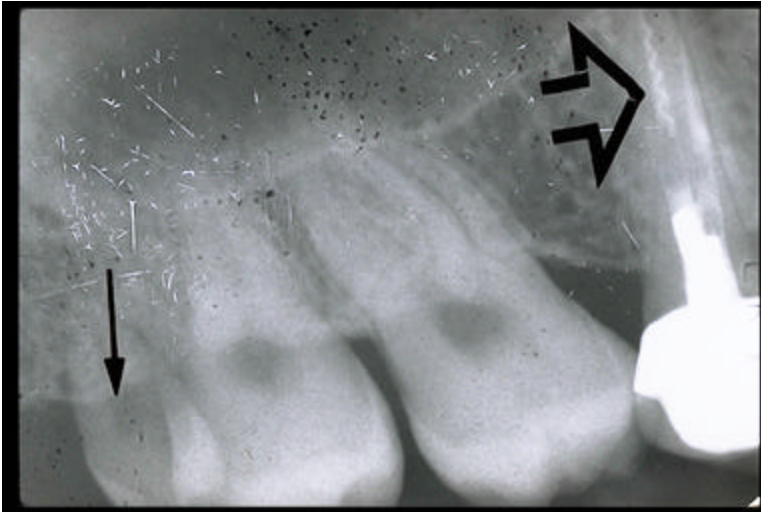1. The midline structure palatal to the alveolar ridge should be identified as a (n)
- mesiodens \*
  - Bohn's nodule
  - odontoma
  - torus palatinus
  - Epstein's pearl

The Bohn's nodule is a patch of keratin found on the alveolar ridge in the newborn.

The Epstein's pearl is a patch of keratin found on the mid palatal ridge of the newborn.

2. How will you treat this patient?
- leave alone
  - remove \*
  - wait to erupt fully and then extract

d. orthodontic treatment



1. In the second maxillary premolar, the open arrow is pointing to

- a. silver point
- b. GP point
- c. static electricity
- d. spiral lentulo filler \*

2. The other arrow is pointing to

- a. third molar
- b. second molar
- c. deciduous molar
- d. odontoma
- e. retromolar \*

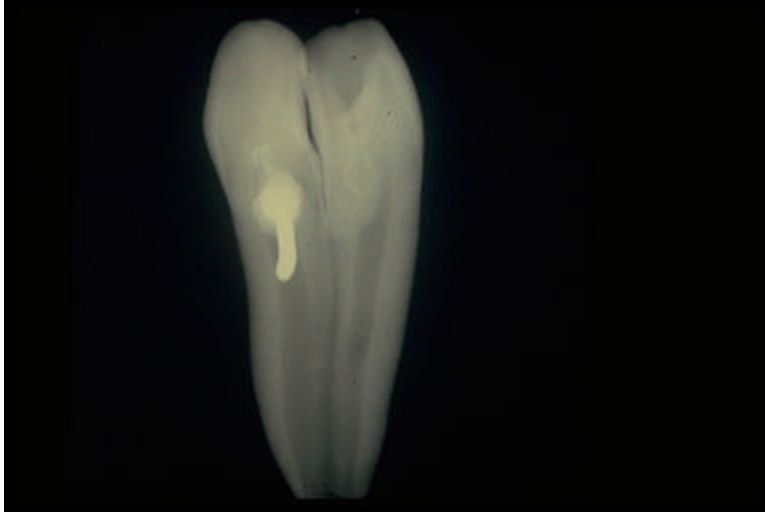
Also called a distodens

The first question informs you that the tooth is the second premolar. The apices of this tooth and the molar tooth are far enough apart to indicate that the first molar tooth is missing.

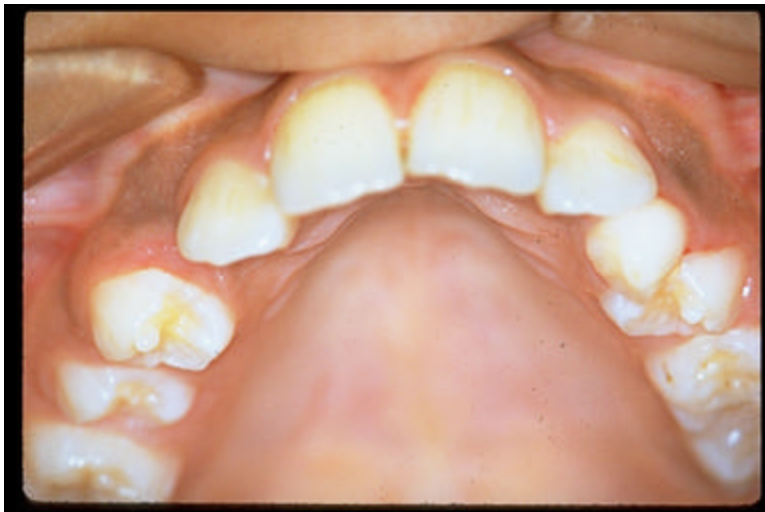3. The small black dots at the top of the radiograph is

- a. fluoride drops
- b. fixed drops
- c. static electricity
- d. dirt \*

When handling the surface of a radiograph, the oil from the operator's fingers collect dirt. Thus do not touch the surface of a radiograph.



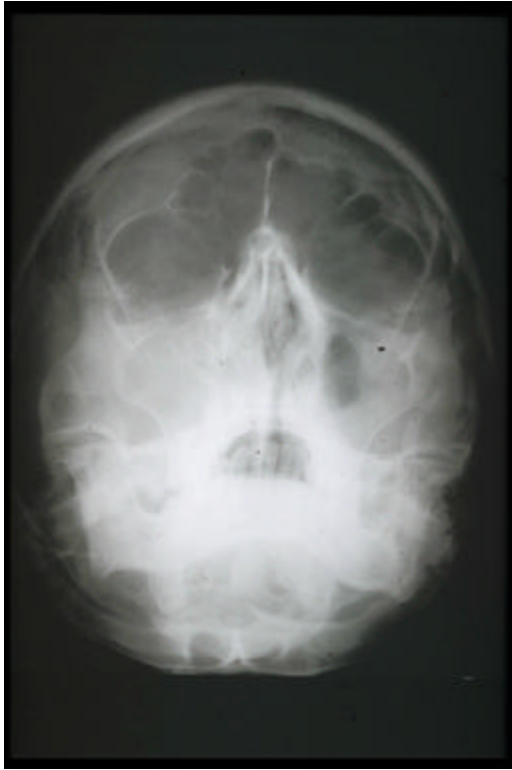
1. Anatomic anomalies noted in this radiograph
  - a. fusion and gemination
  - b. gemination and taurodontia
  - c. taurodontia and enamel pearl
  - d. enamel pearl and invagination
  - e. fusion and invagination \*



1. Anatomic anomaly noted here
  - a. dens invaginatus
  - b. taurodontia
  - c. dens evaginatus \*
  - d. enamel pearl
  - e. impacted canine

Note the tubercle on the first premolar bilaterally. An impacted canine is not an anomaly. Dens invaginatus will be seen radiographically. See previous slide.



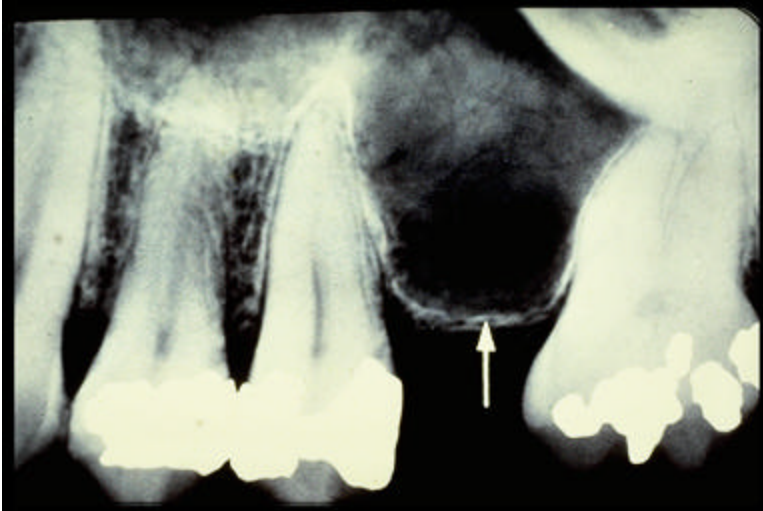


1. Identify this radiographic view
  - a. Submento-vertex
  - b. OM \*
  - c. PA
  - d. tomograph
  - e. none of the above

Note the ascending ramus can NOT be seen. Also called Waters view

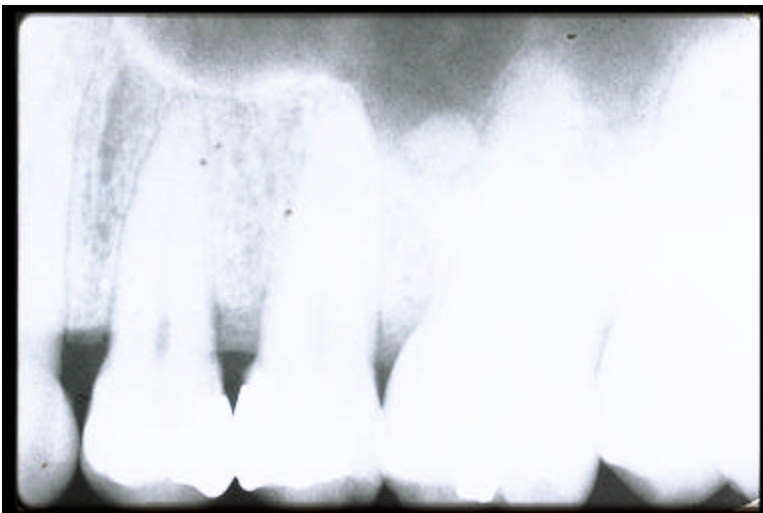
2. This view is used to examine the
  - a. zygomatic arch
  - b. maxillary sinuses \*
  - c. body and ascending ramus of the mandible
  - d. sections of fractures
  - e. none of the above
3. The most important finding here
  - a. osteopetrosis
  - b. osteoporosis
  - c. fracture of the mandible
  - d. sinusitis \*

The patient's right sinus is cloudy.



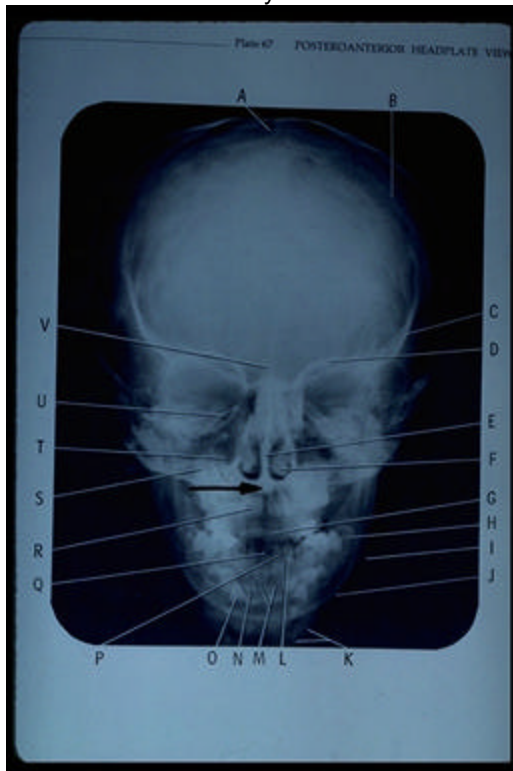1. In this periapical radiograph of the maxillary posterior region, the white arrow is indicating -
- a. alveolar ridge and floor of the sinus \*
  - b. floor of the sinus and zygomatic arch
  - c. zygomatic arch and alveolar ridge
  - d. pneumatization and fracture
  - e. infra orbita and pneumatization

2. The dark linear lucencies seen in the maxillary antrum are
- a. static electricity
  - b. nerve canals
  - c. nutrient canals \*
  - d. fractures
  - e. artifacts



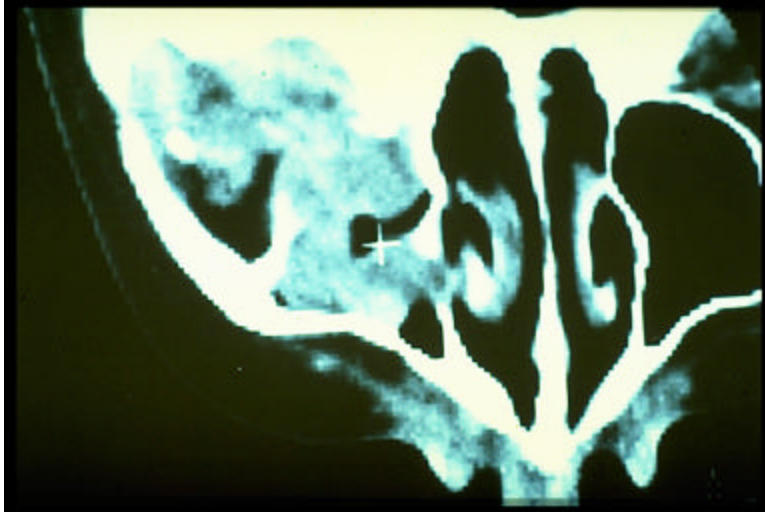
1. In this periapical radiograph of the maxillary posterior region, the opacity seen in the maxillary sinus is
- a. sialolith
  - b. antrolith \*
  - c. root remnant
  - d. odontoma
  - e. pulp stone

Odontomas are virtually never seen in the sinus



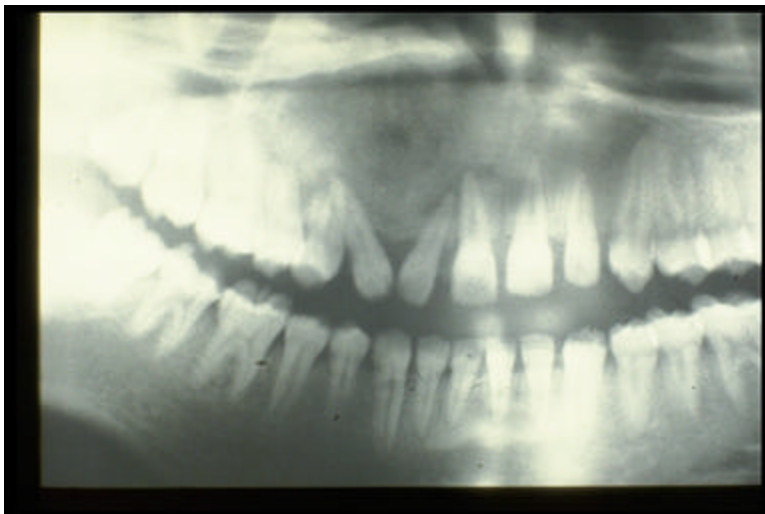
1. Identify this radiographic projection
  - a. PA \*
  - b. Lateral ceph
  - c. OM
  - d. Tomograph
  - e. CT
  
2. This projection is taken primarily to view the
  - a. TMJ
  - b. sinuses
  - c. ascending ramus \*
  - d. zygomatic arch
  - f. nasal septum

Note- the ascending ramus is visible



1. Identify this modality
  - a. submentovertex
  - b. MRI
  - c. CT \*
  - d. MRI
  - e. anterior oblique

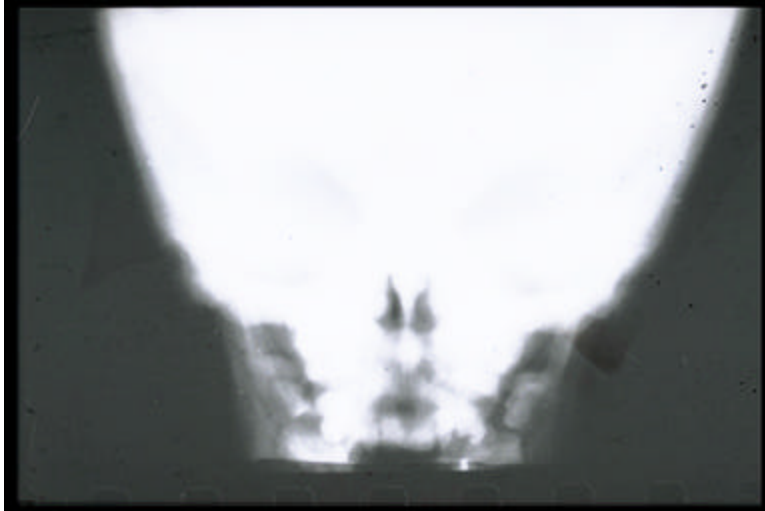
CT showing a malignancy that has destroyed the posterior wall of the maxillary sinus



1. The ground glass appearance seen in the maxillary anterior region is indicative of -
  - a. osteitis deformans
  - b. osteosarcoma
  - c. multiple myeloma
  - d. fibrous dysplasia \*
  - e. osteopetrosis

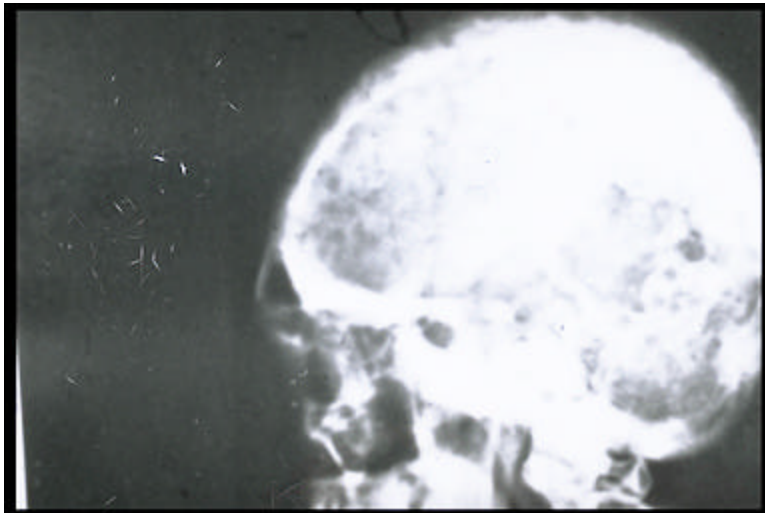
The outline of fibrous dysplasia is poorly demarcated. If it were well demarcated think of a fibro-osseous [cemento-osseous] lesion.

Osteitis deformans- cotton wool appearance  
 Osteosarcoma- sunray/sunburst appearance



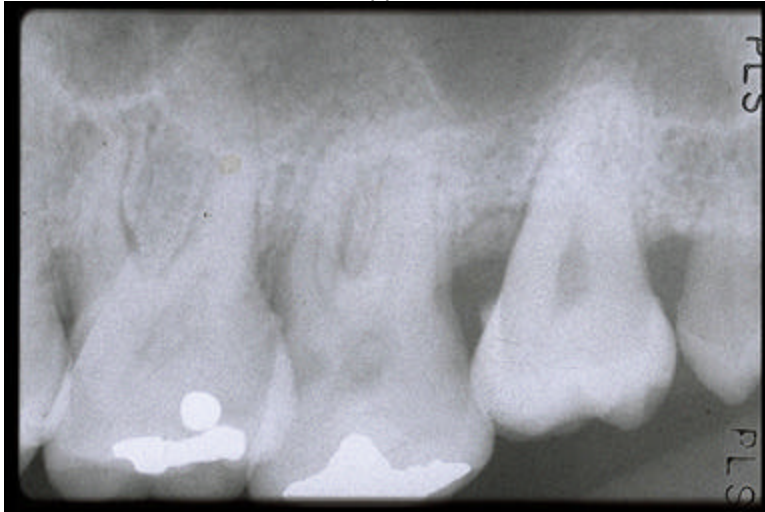
1. The uniform opacity of the skull seen in this Postero Anterior radiograph is indicative of
  - a. osteitis deformans
  - b. osteosarcoma
  - c. multiple myeloma
  - d. fibrous dysplasia
  - e. osteopetrosis \*

Osteitis deformans [ Paget,s] would be cotton wool appearance; osteosarcoma will have a sun ray appearance. Multiple myeloma- punched out lucencies



1. Identify this projection -
  - a. PA
  - b. Lateral ceph OR lateral skull \*
  - c. OM
  - d. Tomograph
  - e. CT
  
2. The cotton wool appearance seen in this radiograph is strongly suggestive of -
  - a. osteitis deformans \*
  - b. osteosarcoma
  - c. multiple myeloma
  - d. fibrous dysplasia
  - e. osteopetrosis

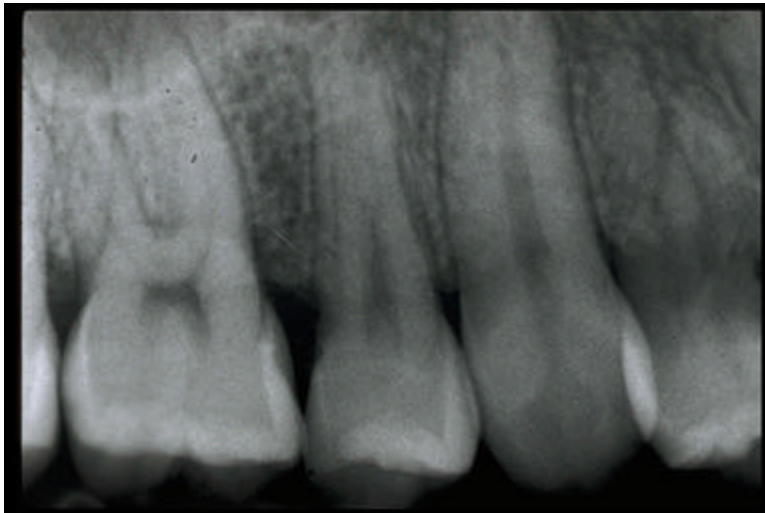
This is a classical cotton wool appearance.



1. Anatomic anomaly seen in this periapical radiograph of the maxillary posterior region -

- a. missing tooth
- b. dentinogenesis imperfecta
- c. amelogenesis imperfecta
- d. transposition
- e. additional tooth \*

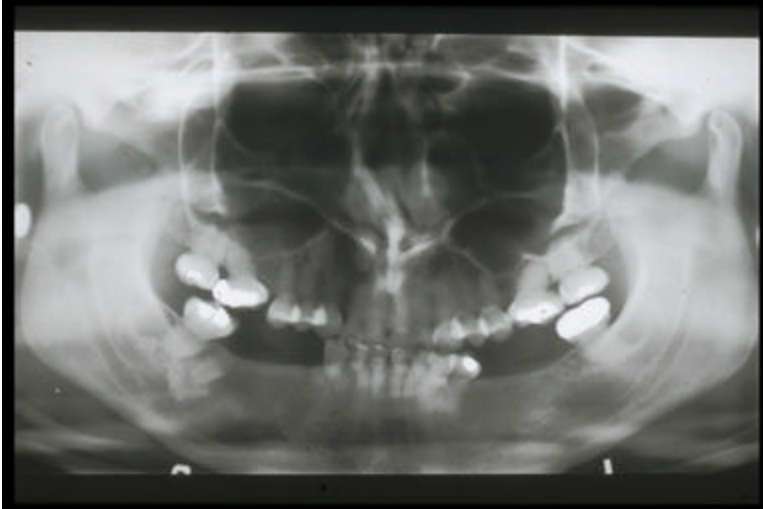
a retromolar/distodens



1. Anatomic anomaly seen in this periapical radiograph of the maxillary premolar region -

- a. missing tooth
- b. dentinogenesis imperfecta
- c. amelogenesis imperfecta
- d. transposition \*
- e. additional tooth

The canine is between the premolars



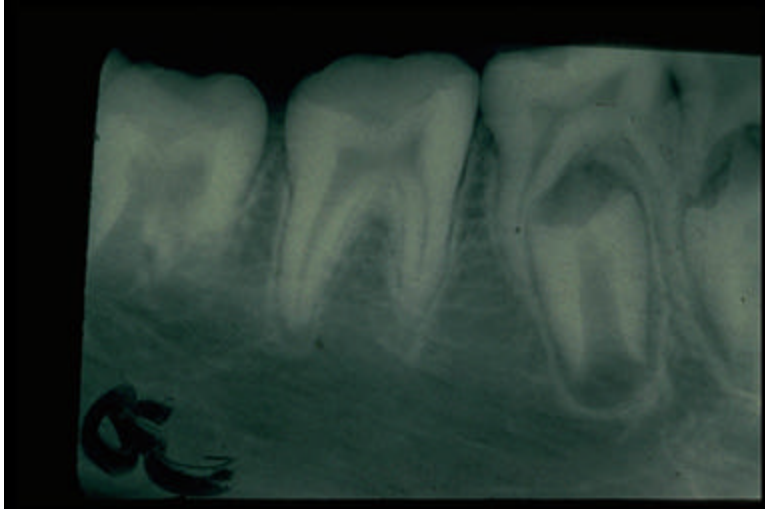
1. Anatomic anomaly seen in this panoramic radiograph -

- a. regional odontodysplasia
- b. dentinogenesis imperfecta \*
- c. amelogenesis imperfecta
- d. transposition
- e. additional tooth

Note - all pulp chambers and nerve canals are obliterated with bulbous crowns.

2. What will you look for to confirm your diagnosis?

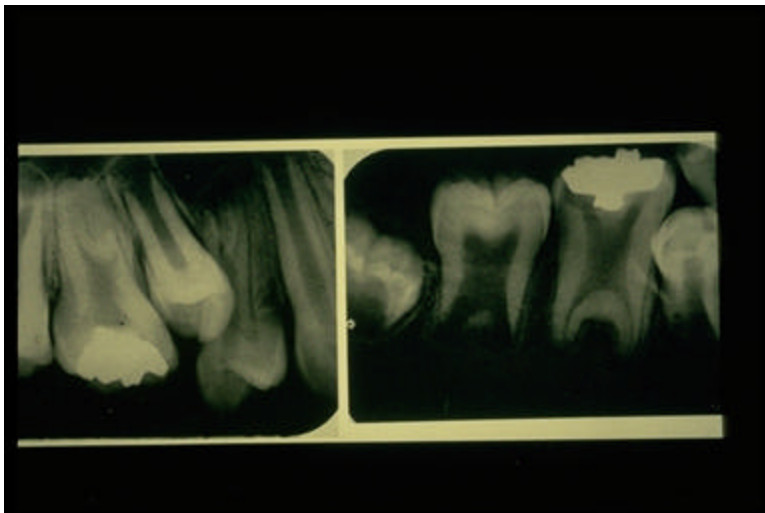
- a. chalky enamel surfaces
- b. supernumerary teeth
- c. incomplete clavicles
- d. opalescent hue
- e. chipped enamel
- f. d+e



1. Anatomic anomaly seen in this periapical radiograph of the mandibular posterior region -
  - a. regional odontodysplasia
  - b. dentinogenesis imperfecta
  - c. amelogenesis imperfecta \*
  - d. transposition
  - e. additional tooth

Note - even the teeth that have not yet erupted do not have *any* enamel

2. What is the best way to distinguish between dentinogenesis imperfecta and amelogenesis imperfecta
  - a. radiographically \*
  - b. chalky teeth
  - c. tooth color
  - d. vitality test



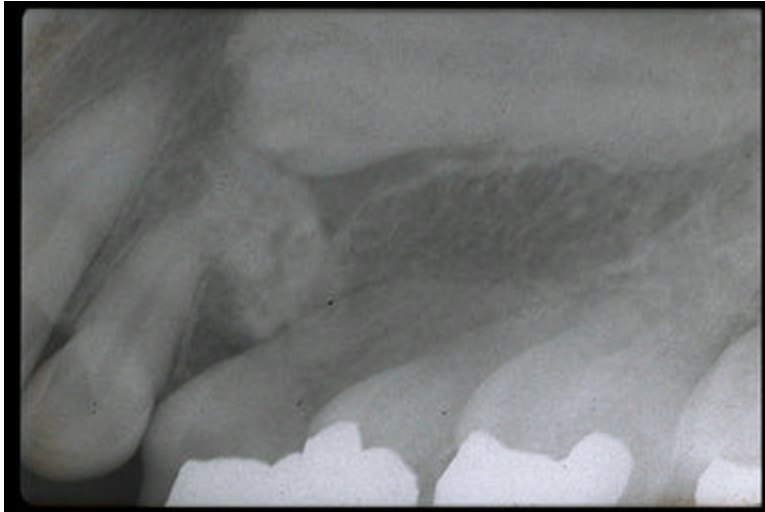
1. Anatomic anomaly seen in these periapical radiographs -
  - a. periapical cemental dysplasia
  - b. taurodontia \*
  - c. amelogenesis imperfecta
  - d. dentinogenesis imperfecta
  - e. concrescence



2. Clinically, what is seen in taurodontia

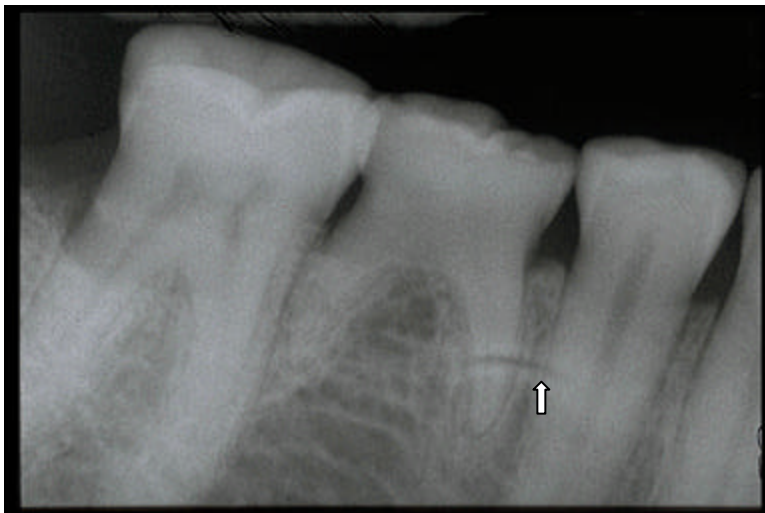
- a. large crowns
- b. large pulps
- c. long teeth
- d. nothing \*

One can not see the pulp clinically



1. Anatomic anomaly seen in this periapical radiograph -

- a. concrescence
- b. taurodontia
- c. compound odontoma
- d. dentinogenesis imperfecta
- e. complex odontoma \*



1. In this periapical radiograph of the mandibular premolar / molar region, the most important finding is

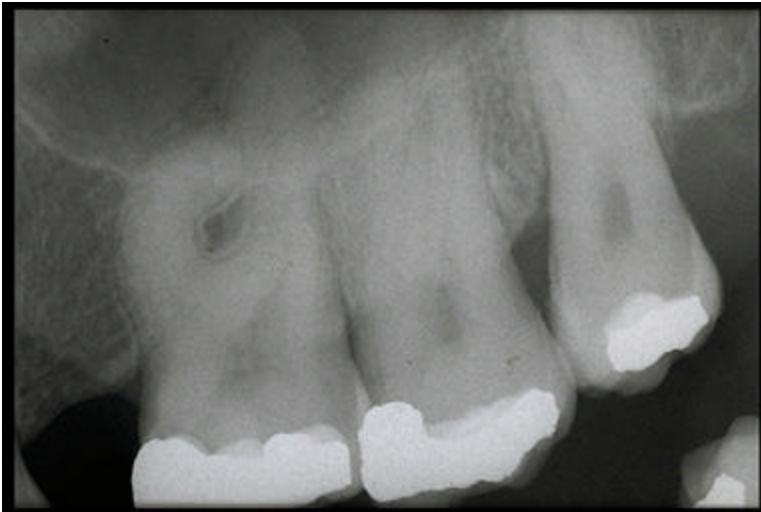- a. missing tooth \*
- b. deciduous tooth present
- c. obliterated pulp chamber
- d. additional cusp
- e. none of the above

2. Treatment for this patient

- a. observe \*
- b. extract and place an implant
- c. extract and place a chromium cobalt bridge
- d. extract and place a resin bonded bridge
- e. extract and close the space orthodontically

3. Identify the semilunar lucency seen over the mesial root identified by open arrow?

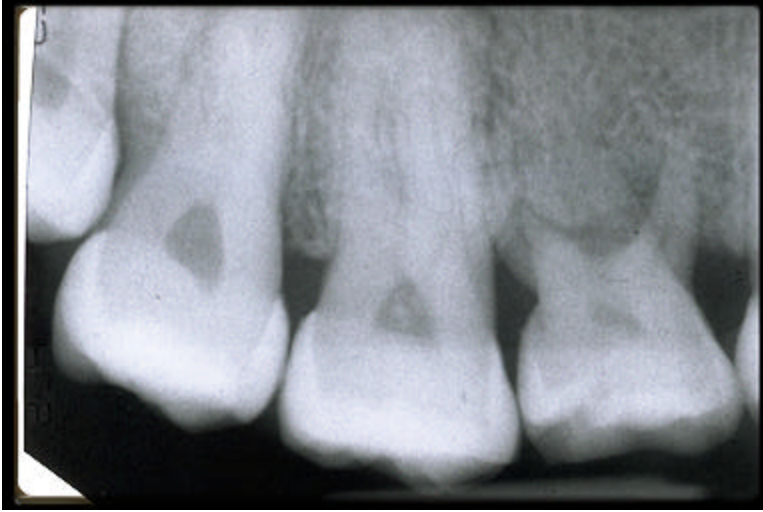- a. static electricity
- b. artifact
- c. finger nail
- d. bent film
- e. c+d \*



1. The most important finding in this periapical radiograph of the maxillary posterior region

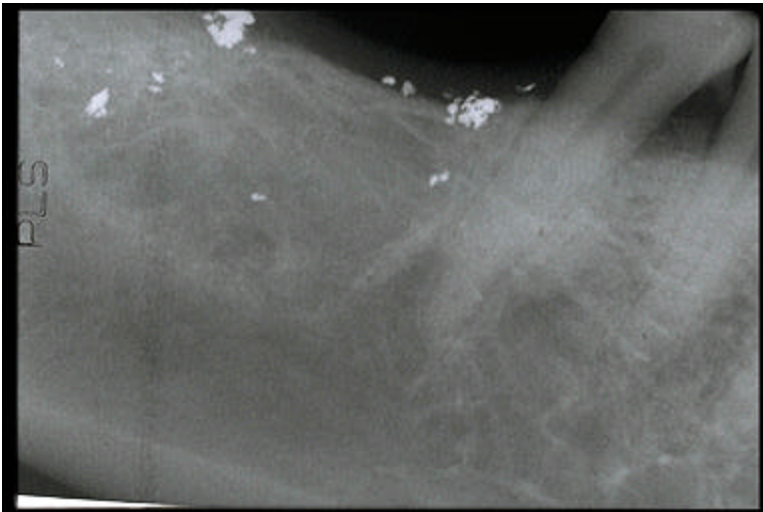
- a. dilaceration \*
- b. loss of vitality
- c. missing tooth
- d. additional cusp
- e. additional tooth

Checking for vitality is done with a pulp tester



1. The most important finding in this periapical radiograph of the maxillary posterior region
  - a. missing tooth \*
  - b. additional tooth
  - c. transposition
  - d. obliterated pulp chamber
  - e. root resorption

You are required to note that there is a deciduous second molar present; not to be confused with the presence of 4 permanent molars.



1. The most important finding in this periapical radiograph of the mandibular posterior region
  - a. fixer drops
  - b. amalgam scraps \*
  - c. exposure to light
  - d. static electricity

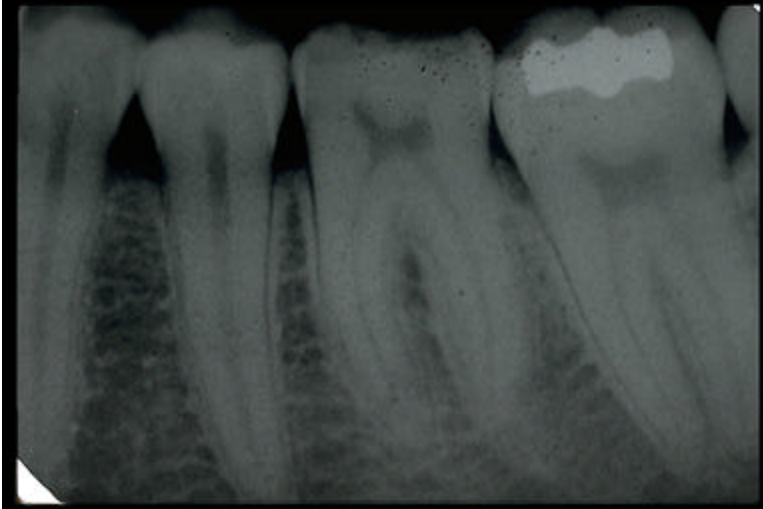
Fixer drops are round. The radiograph was taken immediately after an amalgam restoration was placed and the patient was anesthetized. "c" and "d" would be black



1. Most important finding in this periapical radiograph
  - a. mA too low
  - b. kVp too low
  - c. bent film
  - d. patient moved \*

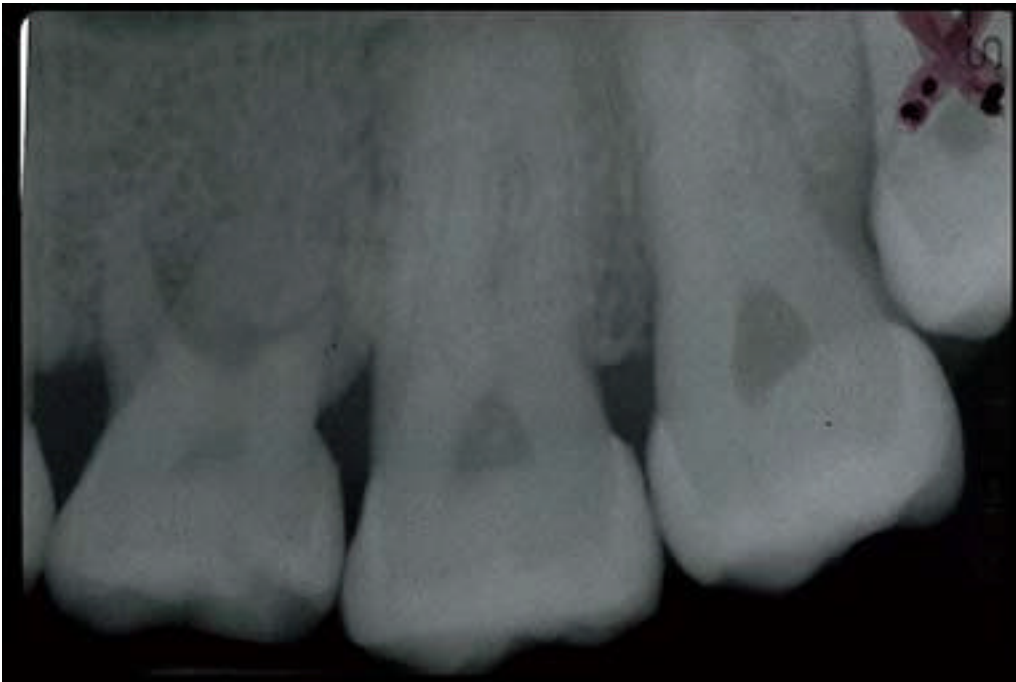
mA would affect the density. Bent film would show part of the image in focus and there would be elongation on the rest of the film; usually apically.

2. This problem can be eliminated / corrected by
  - a. increasing the kVp
  - b. increasing the mA
  - c. using a head support \*
  - d. using aligning instruments
  - e. dropping the patients head



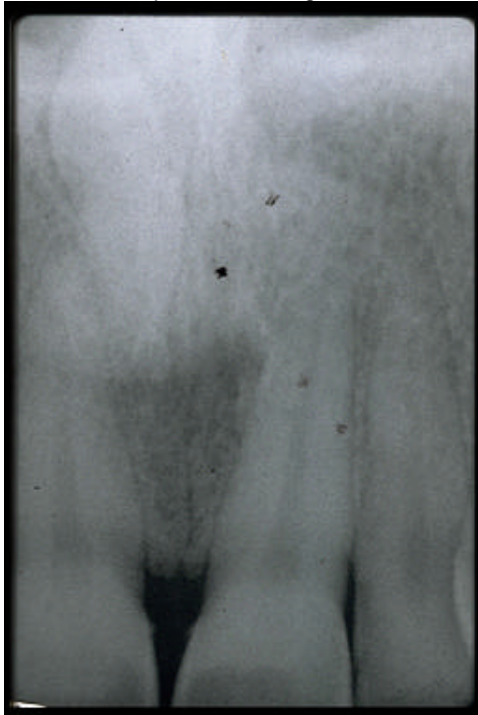1. This was the only tooth in the jaw that was so affected. Your preliminary diagnosis
  - a. juvenile periodontitis
  - b. trauma
  - c. osteitis deformans
  - d. congenital syphilis \*
  - e. amelogenesis imperfecta

There is minimal amount of enamel occlusally of the first molar and the cusps have not formed. A premolar would be Turner tooth. This is a mulberry molar.



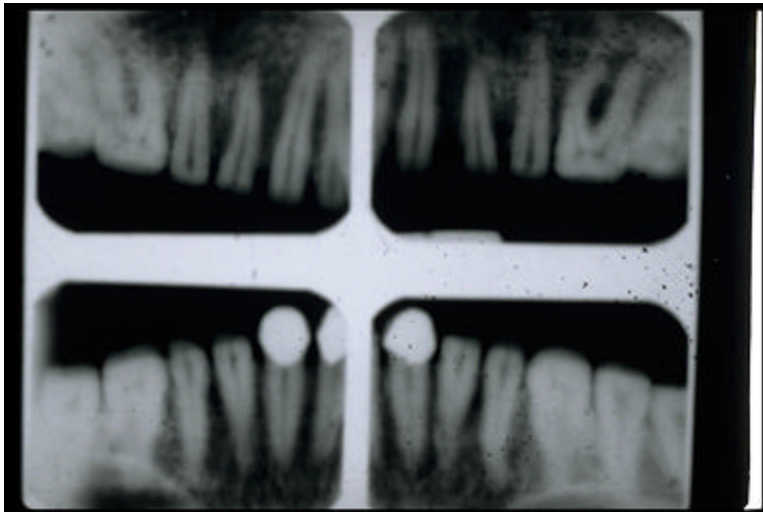
1. In this periapical radiograph of the maxillary posterior region, identify the tooth marked with an "X"
  - a. retromolar
  - b. third molar \*
  - c. second molar
  - d. deciduous second molar
  - e. odontoma

You were required to recognize the first molar as a deciduous second molar



1. The most important finding in this periapical radiograph of the maxillary anterior region
  - a. missing tooth
  - b. additional tooth \*
  - c. transposition
  - d. obliterated pulp chamber
  - e. root resorption

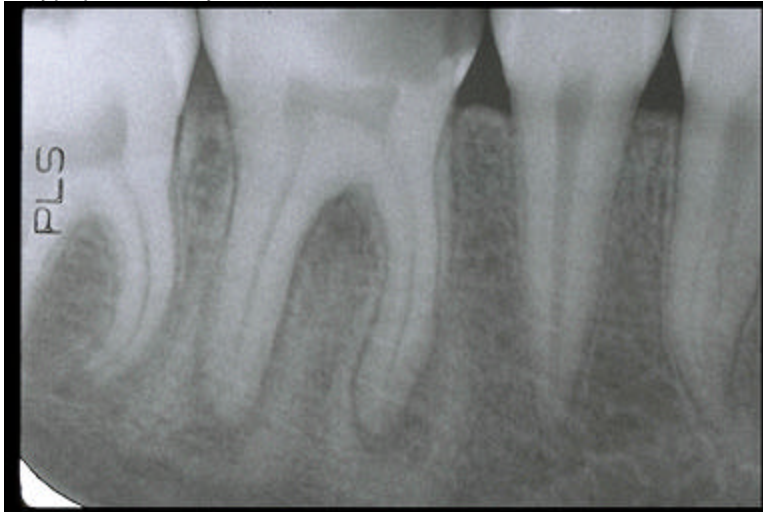
An inverted mesiodens



1. Identify this anatomic anomaly
  - a. dentinogenesis imperfecta
  - b. amelogenesis imperfecta \*
  - c. hypercementosis
  - d. dentinal dysplasia
  - f. concrescence

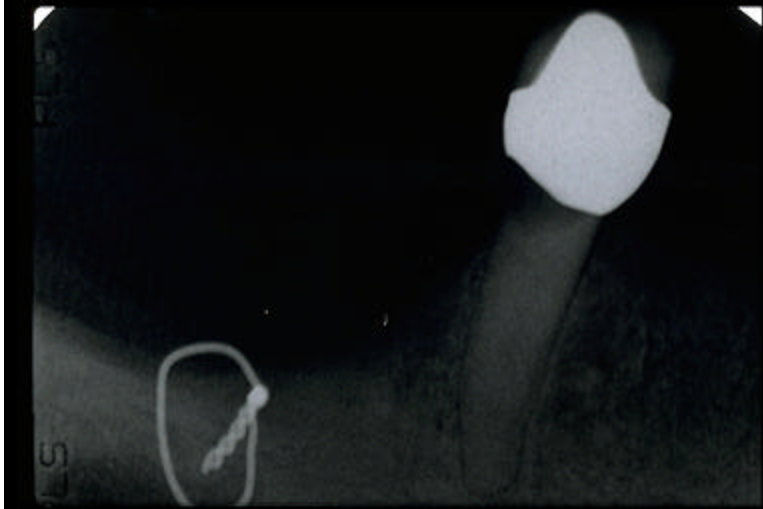There are 2 types of amelogenesis imperfecta.

- 1.hypocalcified-normal volume of enamel labeling in calcified material. Enamel visible interproximally.
- 2.hypoplastic- very little enamel formed. Enamel is normal. Looks like crown preps.



1. The opacity at the apex of the mandibular first molar is best described as
  - a. concrescence
  - b. hypercementosis
  - c. enostosis
  - d. condensing osteitis \*
  - e. benign cementoblastoma

With a hypercementosis the lucency would be peripheral to the opacity.



1. The round, linear opacity seen in this periapical radiograph should be recognized as
  - a. radium needle
  - b. ligature wire \*
  - c. broken extraction instrument
  - d. broken endo instrument