

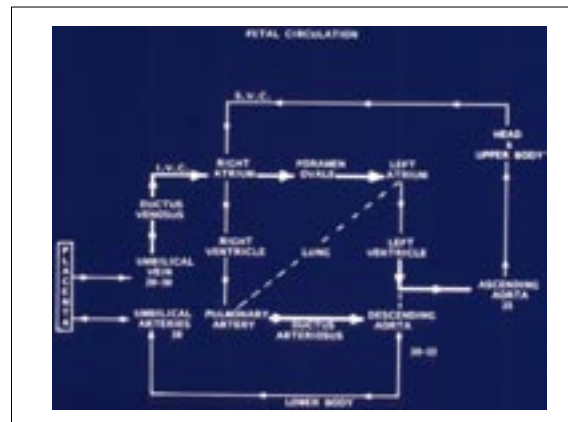
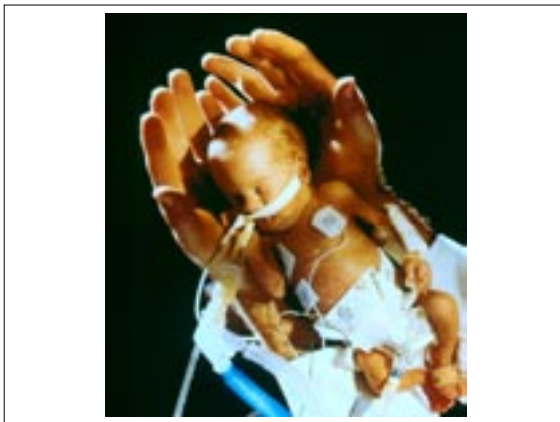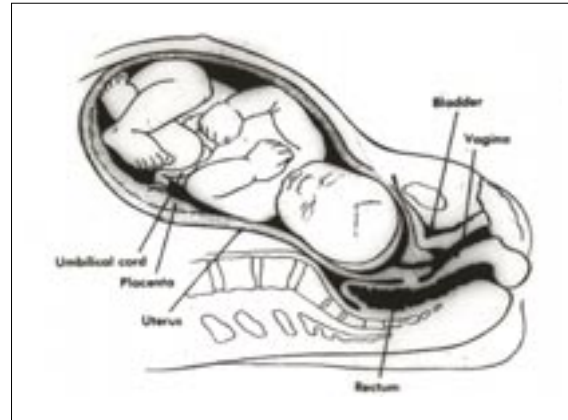
THE NEONATE

Richard A. Polin M.D.

*Professor of Pediatrics
Director of the Division of Neonatology
rap32@columbia.edu*

David S. Rubenstein M.D.

*Professor of Clinical Pediatrics
sdr26@columbia.edu*



Maximus R.

- Born to a 32 year old primagravida
- Fetal distress (bradycardia) during labor
- C-section-meconium noted at membrane rupture
- Apgar scores 1 and 6 (at 1 and 5 minutes)
- Persistent hypoxia despite FiO2 1.0 (pO2 >700)
- IPPV initiated without significant increase in pO2
- pH 7.30, pCO2 48, pO2 38, HCO3 22
- Diagnosis: persistent fetal circulation

Composition of Meconium

- Sloughed intestinal epithelial cells
- Swallowed amniotic debris (hair, vernix)
- Squamous epithelial cells
- Pancreatic lipases and proteases
- Bile acids and salts
- Sucus entericus
- White blood cells

Maximus R.

- Born to a 32 year old primagravida
- Fetal distress (bradycardia) during labor
- C-section-meconium noted at membrane rupture
- Apgar scores 1 and 6 (at 1 and 5 minutes)
- Persistent hypoxia despite FiO2 1.0 (pO2 >700)
- IPPV initiated without significant increase in pO2
- pH 7.30, pCO2 48, pO2 38, HCO3 22
- Diagnosis: persistent fetal circulation

Components of the Apgar Score

Sign	Score		
	0	1	2
Heart rate	Absent	<100	>100
Respiration	Absent	Irregular	Good cry
Color	Cyanotic	Acrocyanosis	Pink
Tone	Limp	Minimal	Active
Reflex	Absent	Minimal	Active

