CHEST®

Official publication of the American College of Chest Physicians

Long-term Complications of Congenital Esophageal Atresia and/or Tracheoesophageal Fistula*

Thomas Kovesi and Steven Rubin

Chest 2004;126;915-925
DOI 10.1378/chest.126.3.915

The online version of this article, along with updated information and services can be found online on the World Wide Web at:
http://www.chestjournal.org/content/126/3/915.full.html

CHEST is the official journal of the American College of Chest Physicians. It has been published monthly since 1935. Copyright 2007 by the American College of Chest Physicians, 3300 Dundee Road, Northbrook IL 60062. All rights reserved. No part of this article or PDF may be reproduced or distributed without the prior written permission of the copyright holder.
(http://www.chestjournal.org/site/misc/reprints.xhtml) ISSN:0012-3692

AMERICAN COLLEGE OF CHEST PHYSICIANS®

Downloaded from www.chestjournal.org on April 6, 2009
Copyright © 2004 American College of Chest Physicians

Long-term Complications of Congenital Esophageal Atresia and/or Tracheoesophageal Fistula*

Thomas Kovesi, MD; and Steven Rubin, MB

Congenital esophageal atresia (EA) and/or tracheoesophageal fistula (TEF) are common congenital anomalies. Respiratory and GI complications occur frequently, and may persist lifelong. Late complications of EA/TEF include tracheomalacia, a recurrence of the TEF, esophageal stricture, and gastroesophageal reflux. These complications may lead to a brassy or honking-type cough, dysphagia, recurrent pneumonia, obstructive and restrictive ventilatory defects, and airway hyperreactivity. Aspiration should be excluded in children and adults with a history of EA/TEF who present with respiratory symptoms and/or recurrent lower respiratory infections, to prevent chronic pulmonary disease. ***(CHEST 2004; 126:915–925)***

Key words: aspiration; congenital defects; gastroesophageal reflux; pneumonia; tracheoesophageal fistula

Abbreviations: EA = esophageal atresia; GERD = gastroesophageal reflux disease; PFT = pulmonary function testing; RV = residual volume; TEF = tracheoesophageal fistula; TLC = total lung capacity

Congenital Esophageal atresia (EA) and tracheoesophageal fistula (TEF) are common congenital anomalies, affecting 1 in 2,400 to 4,500 individuals.[1] Respiratory sequelae are common and may persist life-long. This review will focus on the long-term implications of these conditions.

Definition and Background

EA is defined as a complete interruption in the continuity of the esophageal lumen.[2] TEF may be defined as a congenital, fistulous connection between the proximal and/or distal esophagus, and the airway.[3] While EA and TEF may exist as separate congenital anomalies, the great majority of patients with these congenital malformations have both EA and TEF. As EA, TEF, and EA/TEF generally have similar associations with other anomalies and complications, they will be considered together in this review, except where otherwise noted.[1] The surgical management of EA/TEF has evolved over the last 60 years, associated with a progressive improvement in survival.[4]

Embryology

The median pharyngeal groove develops in the ventral aspect of foregut at day 22 of gestation. This tissue develops into the respiratory and digestive tubes. Normally, mesenchyme proliferating between the respiratory and digestive tubes separates the tubes. While several theories have attempted to explain the etiology of EA/TEF, it is currently believed that the development of an abnormal epithelial-lined connection between the two tubes results in the creation of a TEF.[1] The excess tissue growth may lead to incorporation of part of the esophagus into the posterior wall of the trachea.[5] Excess mesenchymal growth can stretch and disrupt the esophagus, creating EA.[1] Following surgical repair, structural and functional defects in the trachea and esophagus are present in the majority of patients, and this is the source of much of the long-term morbidity caused by this congenital anomaly. The trachea, particularly at the site of the previous EA/TEF, typically retains a U-shaped configuration, with a wide membranous portion, rather than the normal C-shape, with a short membranous portion. This commonly leads to tracheomalacia of varying degrees of severity.[6,7] Loss of the ciliated epithelial lining of the trachea may also be present, and

*From the Pediatric Respirology Service, Department of Pediatrics (Dr. Kovesi), and Division of Pediatric Surgery (Dr. Rubin), Children's Hospital of Eastern Ontario, Ottawa, ON, Canada.
Manuscript received August 13, 2003; revision accepted November 18, 2003.
Reproduction of this article is prohibited without written permission from the American College of Chest Physicians (e-mail: permissions@chestnet.org).
Correspondence to: Thomas Kovesi, MD, Department of Pediatrics, Children's Hospital of Eastern Ontario, University of Ottawa, 401 Smyth Rd, Ottawa, ON, Canada, K1H 8L1; e-mail: kovesi@cheo.on.ca

Downloaded from www.chestjournal.org on April 6, 2009
Copyright © 2004 American College of Chest Physicians

squamous epithelium, lacking both ciliated and goblet cells, appears to be particularly prevalent in the posterior muscular portion of the trachea around the area of the original fistula site, although it may be widespread. However, it is unclear whether this represents a developmental anomaly, or is secondary to aspiration.[5]

The presence of EA/TEF also disrupts the normal *in utero* development of the myenteric plexus in the esophagus, leading to disordered peristalsis and impaired lower esophageal sphincter function. Neural tissue in the Auerbach plexus was markedly reduced, particularly in the distal esophagus, in autopsy specimens from EA/TEF patients, and the gastric plexus was also found to be abnormal.[8] Structural abnormalities are also commonly found in the esophagus, including disorganized muscle layers and tracheobronchial remnants, such as dilated clusters of seromucous glands and cartilage. This may also contribute to abnormal esophageal motor function.[9] One study[10] suggests that concomitant congenital esophageal stenosis involving the lower esophagus is fairly common.

EA/TEF is commonly associated with other congenital anomalies; overall, approximately 25% of patients have other congenital defects. Other defects are present most commonly in patients with isolated EA, where other anomalies are present in 50 to 70% of patients. The most common congenital anomalies associated with EA/TEF patients are cardiac (35% of patients), genitourinary (24% of patients), GI (24% of patients), skeletal (13% of patients), and CNS anomalies (10% of patients).[1] The common occurrence of any combination of these congenital anomalies is often termed the *vertebral, anal, cardiac, tracheoesophageal, renal, and limb association* (VACTERL). There is controversy about whether these represent nonrandom associations, as most series have been biased by specifically collecting similar cases. However, research[11] using large, population-based malformation registries supports the concept that these may be nonrandom associations, possibly due to defective midline blastogenesis. EA/TEF may also be associated with other congenital anomalies of the respiratory tree. Tracheal bronchus and absence of the bronchus to the right upper lobe were frequent in neonates with EA/TEF screened by bronchoscopy by Usui and coworkers.[7] A variety of congenital lung anomalies, including pulmonary and lobar agenesis, horseshoe lung, and pulmonary hypoplasia, have also be reported in individuals with EA/TEF. This suggests that all these conditions may be part of what has been termed a *general foregut malformation*.[12–14] EA/TEF has also been reported in patients with the DiGeorge syndrome, Down syndrome, and Pierre-Robin sequence. A second association of coloboma, heart anomalies, atresia choanae, retardation, and genital and ear anomalies is known as the CHARGE association, and has also been associated with EA/TEF.[1,15,16]

Classification

There are five types of congenital EA/TEF (Fig 1). Two similar classification systems, the Gross and the Vogt classification systems, are in use.[17–18] Gross type C (Vogt type 3B) EA/TEF, which consists of distal TEF with proximal EA, is the most common type, comprising approximately 88.5% of cases. Gross type A, or isolated EA, occurs in approximately 8% of cases. Gross type E EA/TEF, consisting of TEF without EA, or H-type TEF, occurs in approximately 4% of cases, with the remainder consisting of Gross types B and D.[1]

Surgical Management

Most infants with EA/TEF undergo repair in early infancy, with division of the TEF and primary esophageal anastomosis. Patients with EA and wide separation of the esophageal ends continue to represent a major surgical challenge. Lengthening procedures, with or without esophagomyotomy, may be used to allow esophageal anastomosis. Neonatal esophageal stretching has been reported to allow primary anastomosis of the esophagus even in infants with long-gap EA/TEF.[19] In more severe cases, anastomosis may be delayed, with placement of a cervical esophagostomy, until sufficient esophageal growth occurs to allow anastomosis. In cases where esophageal anastomosis is ultimately impossible, esophageal replacement with gastric, jejunal, or colonic tissue may be performed. These procedures are associated with a higher prevalence of long-term respiratory and esophageal complications.[1] Diagnosis, and surgical correction, is generally later in patients with H-type TEF, with the mean age at diagnosis being 8 months in one series.[20] Uncommonly, EA/TEF may be diagnosed and repaired in adults.[21] Occasional patients with an EA/TEF diagnosis have bronchogastric or bronchoesophageal fistulas detected at the time of surgery.[22]

GI Complications of EA/TEF

Growth

GI symptoms are common in children with a history of EA/TEF.[23] Weight and height percentiles of children with EA/TEF may be reduced compared to sibling pairs, although some studies[23,24] have reported normal growth.

Downloaded from www.chestjournal.org on April 6, 2009
Copyright © 2004 American College of Chest Physicians

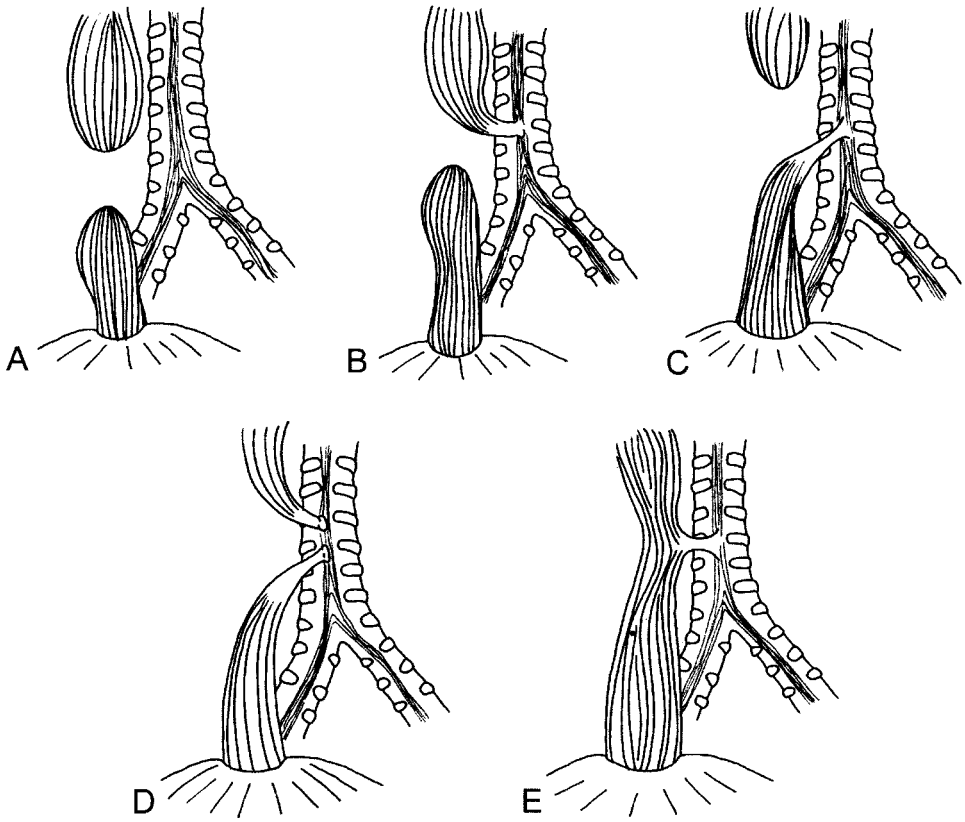

FIGURE 1. Classification of EA/TEF.[17,18] *Top left*, *A*: EA (Gross classification A, Vogt classification 2, approximate frequency 8%). *Top center*, *B*: Proximal TEF with distal EA (Gross classification B, Vogt classification 3A, approximate frequency 0.8%). *Top right*, *C*: Distal TEF with proximal EA (Gross classification C, Vogt classification 3B, approximate frequency 88.5%). *Bottom left*, *D*: Proximal TEF and distal TEF (Gross classification D, Vogt classification 3C, approximate frequency 1.4%). *Bottom right*, *E*: TEF without EA or "H"-type TEF (Gross classification E, approximate frequency 4%).

Anastomotic Leak

Anastomotic leak is an uncommon early complication of surgical repair, occurring in up to 17% of patients. However, it has potentially significant long-term consequences.[1] While 95% resolve spontaneously or with pleural drainage, esophageal stricture follow in 50% of cases. They can be followed by a recurrence of the TEF.[25]

Dysphagia

Esophageal peristalsis, assessed by manometry, is abnormal in 75 to 100% of children and young adults with a history of EA, and in 100% of those with colonic interposition.[23,26] An immotile segment or small, discoordinate contractions is most commonly observed.[26] Many children with repaired EA/TEF need to eat slowly, and may need to avoid meats.[27] In severe cases, failure to thrive or aspiration may develop.[1] Esophageal obstruction following ingestion of organic or nonorganic material (foreign bodies) may occur due to poor peristalsis and/or esophageal stricture (see below), and some patients require repeated removal of esophageal foreign bodies.[25] Occasional dysphagia is still present in 53 to 92% of adults, and is sometimes accompanied by choking in 33% of adults.[27,28] Daily dysphagia is reported by 13 to 20% of adults.[27,29] Dysphagia may be exacerbated by the presence of congenital esophageal stenosis. This may require myotomy for treatment.[10] In rare cases, congenital esophageal stenosis has even been described in association with an H-type TEF.[30] GI symptoms and the frequency of admission for GI causes become less frequent by adulthood. One study[27] reported that 65% of patients were admitted for GI problems during the first 10 years of life, but only 3% of patients > 18 years of age.

Long-segment EA may require delayed closure, using a cervical stoma. This has a significantly higher risk of aspiration. Esophageal replacement with a gastric tube or colon for long-segment EA has a heightened risk of dysmotility and dysphagia, as well as gastroesophageal reflux disease (GERD), aspiration, and failure to thrive, and the complication rate

Downloaded from www.chestjournal.org on April 6, 2009
Copyright © 2004 American College of Chest Physicians

may be as high as 68%.[25] Complications may be more common with colonic replacement than with gastric replacement.[31]

Esophageal Stricture

Postoperative esophageal strictures occur in 6 to 40% of patients with EA/TEF.[25] Strictures need to be differentiated from stenosis. Esophageal stenosis is usually due to ectopic tissue, usually 1 to 2 cm in length, localized in the distal esophageal segment. This is usually intramural cartilage.[10] It should be noted that radiologically, the distal esophagus is always of smaller caliber than the proximal esophagus. The anastomosis site always looks narrower than the rest of the esophagus, but it should not be described as a stricture unless it is functionally obstructing. This can be difficult to determine because the upper pouch is usually quite baggy and the lower esophagus is quite small. However, the passage of barium through it is usually helpful for determining whether it is obstructing or not. With esophageal stricture, there are clinical signs of obstruction, and a barium swallow or endoscopy should be used to confirm the diagnosis.

Anastomotic stricture is especially common after repair of a gap that is > 2.5 cm. In these instances, the anastomosis is usually under tension, which appears to increase the incidence of strictures.[32] Strictures were more common in patients with EA/TEF types A, C, and D, than in patients with EA/TEF type D or E.[25] Vascular compromise especially of the lower esophagus, which has a segmental blood supply from the aorta or the intercostal blood vessels, is thought to be a cause of strictures. As the upper esophagus has a good blood supply coming from the inferior thyroid artery, extensive mobilization of this segment can be performed without any vascular compromise. However, mobilization of the lower esophagus may risk devascularization, ischemia at the esophageal ends, and stricture formation.[33,34] Strictures have been reported to be less frequent when absorbable sutures are used for the initial repair, although this was not confirmed in experimental studies.[35,36] Interrupted sutures are used to potentially reduce the risk of stricture. Two-layered or the Haight anastomosis and end-to-side anastomosis are also associated with an increased incidence of stricture.[1,25,32,37] Strictures are more common after anastomotic leaks.[32] Esophageal strictures present with GI symptoms such as dysphagia, poor feeding, and emesis in 80% of cases; 8% present with food obstruction by an esophageal foreign body, and 12% present with aspiration leading to recurrent pneumonia. Esophageal strictures are usually treated with repeated dilation, and 69% of patients with EA/TEF require esophageal sounding or dilatation.[25,36] Esophageal strictures are more likely to occur when GERD is present. In one series, GERD was present in 52% of patients with esophageal strictures, compared to only 22% in patients without strictures.[36] GERD reduces the likelihood that dilations will be successful, and the management of GERD is therefore an important part of the treatment of esophageal strictures.[36,38] Reassuringly, in one series of 12 individuals, 30 dilatations were required during the first 10 years of life, but only 2 dilatations between 21 years and 30 years of age.[28]

Gastroesophageal Reflux

GERD is extremely common in this population, occurring in up to 35 to 58% of children.[25,36] Heartburn is still present occasionally in 46% of adults, and is frequent in 11%.[27] Evidence of pathologic gastroesophageal reflux may be observed in two thirds of patients, using an esophageal pH probe.[28] GERD appears to be due to intrinsic motor dysfunction of the esophagus, and possibly to a shortened intra-abdominal segment of the esophagus due to anastomotic tension as well.[25] GERD may lead to esophageal strictures, aspiration leading to pneumonia, bronchial hyperreactivity, and/or permanent airway or lung parenchymal damage. It may also cause apnea and cyanotic spells in infants, and failure to thrive.[23–25,36,39] Tracheal inflammation, assessed by biopsy, correlated with abnormalities in pH probe evaluations and manometry. Esophageal biopsy specimens showed severe inflammation in 20% of cases, and Barrett esophagus in 6%.[23] Esophagitis is also associated with reduced esophageal peristalsis.[28]

Fifty-six percent of patients with EA/TEF and GERD may respond to medical therapy, with the remainder requiring antireflux surgery.[25] The indication for surgical correction of gastroesophageal reflux is failure of medical management as evidenced by the effect of persistent reflux, resulting in reflux esophagitis or Barrett esophagus, failure to thrive, development of a distal esophageal stricture or persistent anastomotic stricture, or aspiration proven to be secondary to gastroesophageal reflux. The usual surgical treatment is a Nissen fundoplication. Overall, 13 to 25% of patients with a history of EA/TEF require fundoplication.[23,25] Timing of fundoplication has been reported to vary from within 6 months of the initial surgery to 21 months of age.[40,41] However, in the presence of a dyskinetic esophagus unable to overcome the resistance of a circumferential wrap, severe dysphagia, resulting in further aspiration, may ensue. For this reason, an anterior Thal procedure or a "floppy" wrap is sometimes performed.[41] Impor-

Downloaded from www.chestjournal.org on April 6, 2009
Copyright © 2004 American College of Chest Physicians

tantly, GERD has been reported to recur in 25% of patients following antireflux surgery.[16]

Gastric abnormalities have also been reported in patients with EA/TEF, probably associated with the abnormalities in esophageal motility. Antral hypomotility is present in 45% of adults, and gastric emptying, as assessed by gastric scintigraphy, is delayed in 36%.[29] *Helicobacter pylori* has been found, using antral histology, in 21% of adults.[23]

Respiratory Complications of EA/TEF

Respiratory symptoms are common in patients with repaired EA/TEF. In one series,[16] 46% of patients with EA/TEF (99% of whom had a type C EA/TEF) had respiratory complications, with 19% of patients having recurrent pneumonia, 10% having aspiration, and 13% had choking, gagging, or cyanosis, with feeds. Respiratory complications were due to GERD in 74% of cases, tracheomalacia in 13%, recurrent TEF in 13%, and esophageal stricture in 10%, although many patients had multiple causes.[16] In another study,[39] the prevalence of chronic or brassy cough, bronchitis (defined as cough, chest congestion, and prolonged constitutional symptoms), and pneumonia fell steadily over time, although the prevalence of wheezing remained fairly constant through early adulthood (Fig 2). As the persistence of respiratory symptoms in adulthood was associated with both a history of early respiratory symptoms, and atopy, it was unclear whether the persistence of respiratory symptoms were due to asthma or lung or airway damage in early childhood events.[39] Chronic cough was present in 16% of adults, and 40% of adults in another study continued to have a barking cough.[17,35] The presence of a daily cough was associated with reflux and with dysphagia. Although approximately 25% of adults were reported to have respiratory symptoms, only 2% of subjects related significant impairment from ongoing respiratory and GI complaints.[35]

In patients with EA/TEF (87% of whom had a type C EA/TEF) between 1 year and 37 years of age, the hospital admission rate for respiratory causes was 44%. Hospital admission was more common in patients with low birth weight and patients with GERD.[39] In one series, rates of hospital admission for respiratory disease fell from 38% of patients during the first 10 years of life, to 1.5% of patients who were > 18 years of age.[27]

The mortality rate among 240 patients with congenital EA/TEF between 1990 and 1997 was 9.2%. Thirty-nine percent of early, in-hospital deaths were due to EA/TEF, and the remainder were due to associated congenital malformations, particularly cardiac defects. Sixty percent of late deaths, occurring up to 2 years following repair, were due to respiratory causes including aspiration, tracheomalacia, GERD, sudden infant death syndrome, and reactive airways disease.[4]

Tracheomalacia

Tracheomalacia is present in pathologic specimens in 75% of patients with EA/TEF, but has been

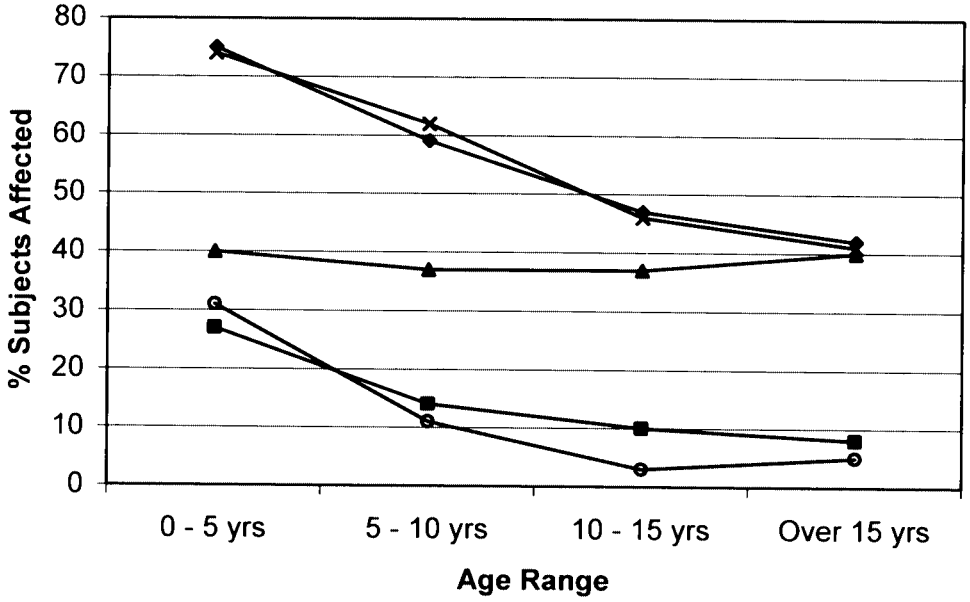

Figure 2. Prevalence of bronchitis (×), brassy cough (♦), wheezing (▲), chronic cough (■), and pneumonia (○) over time (adapted from Chetcuti and Phelan[39]).

Downloaded from www.chestjournal.org on April 6, 2009
Copyright © 2004 American College of Chest Physicians

reported to be clinically significant in only 10 to 20% of patients.[42] Tracheomalacia, both treated and untreated, tends to improve with age.[43] While tracheomalacia may be present in 17% of patients with isolated EA,[25,44] this is rarely clinically significant. Clinically important tracheomalacia, defined as tracheomalacia leading to apnea spells, was not observed in 6 children with isolated EA, but was present in 9 of 61 children (15%) with EA/TEF.[44] As tracheomalacia is usually found at or just above level of the original EA/TEF, the site of collapse is most prominent in the distal one-third trachea in 60% of cases, and in the middle one third in 30%.[1] The soft trachea is easily compressed between the aorta (or innominate artery) and the frequently dilated former esophageal pouch.[45] Bulging of the posterior wall is evident at bronchoscopy.[46] In very severe cases, there is almost total anteroposterior collapse of the lower trachea, with residual 1- to 2-mm-diameter lumen present during coughing and, in the most extreme cases, during expiration.[6] Anteroposterior collapse $> 75\%$ with cough or expiration has been considered severe tracheomalacia.[47] Airway obstruction due to tracheomalacia may cause secondary upper airway obstruction.[48]

In most patients, the manifestations of tracheomalacia are limited to a brassy (barking or honking) cough, which is nearly universal in patients with a history of EA/TEF, and which often persists through adulthood.[27] However, patients with severe tracheomalacia may have stridor at rest or biphasic stridor, dyspnea with feeding, or expiratory wheezing during respiratory infections. Sputum retention due to impaired secretion clearance and ineffective cough may lead to tracheal mucosal metaplasia and reduced cilia, atelectasis, and/or recurrent pneumonia.[7,47,49,50] Aspiration of secretions from the blind pouch at the former TEF site may also lead to infection.[48]

"Dying spells" have been reported in infants with EA/TEF, associated with severe tracheomalacia, demonstrated bronchoscopically. Episodes generally began after 2 to 3 months of age. The event typically occurs during or just after feeding, or during crying or coughing, and is followed by cyanosis progressing rapidly to apnea, bradycardia, and hypotonia, requiring resuscitation. It is postulated that feeding or increases in intrathoracic pressure caused additional airway compression.[45]

Treatment for tracheomalacia is generally reserved for patients with dying spells or recurrent pneumonia. In one series,[51] the indications for surgery were episodes of apnea and cyanosis in 65%, recurrent pneumonia in 25%, and worsening stridor in 46%. Aortopexy involves suturing the aorta to the posterior surface of the sternum. As the posterior aspect of the aorta adheres to the anterior aspect of the trachea, this draws the front wall of the trachea anteriorly, maintaining the tracheal lumen. This has been reported to have initial success rates of 35 to 88%.[45,50,51] A modification of this technique uses a Dacron patch (Dupont; Wilmington, DE) to distribute the tensile forces of the aortopexy more evenly across a wider area of the trachea.[52] The use of an external Marlex splint (CR Bard; Billerica, MA) when aortopexy failed has also been reported, although the success rate was only 50%.[47] Other common complications of EA/TEF should be assessed preoperatively, as success rates are reduced when other conditions such as GERD are present.[50,51] It is important to note that in young children with pronounced wheezing due to severe tracheomalacia associated with EA/TEF, bronchodilators may worsen airflow, by relaxing tracheal smooth-muscle tone necessary for maintaining airway patency. These children may benefit from discontinuation of bronchodilators or, possibly, use of airway smooth-muscle stimulants, such as bethanachol.[53]

More recently, the use of the Palmaz balloon-expandable stent (Johnson & Johnson, International Systems; Warren, NJ) was reported in six patients with EA/TEF and tracheomalacia.[54] Three of these patients had apnea spells, and the remainder had repeatedly failed attempts at extubation. The stent was successful in all the patients, although one patient required a repeat stent and the development of granulation tissue after placement of the stent was observed. After the stents were removed 8 to 12 months later, recurrence of the tracheomalacia was not observed, possibly due to a combination of airway growth and fibrosis induced by the stent. Stenting may be preferable to aortopexy, as it is less invasive. However, severe complications during airway stent removal have been reported.[54] Airway patency following stent placement can be assessed by three-dimensional CT scanning and virtual bronchoscopy.[55] Rarely, patients with very severe tracheomalacia unresponsive to surgical correction may require long-term tracheostomy and management with continuous positive airway pressure.[47]

Recurrent TEF

Recurrence of the TEF occurs in approximately 9% of cases, most often 2 to 18 months after initial repair.[49] It is usually located in the pouch of the original fistula. A recurrent TEF should be differentiated from a second congenital fistula, which is best done by performing a bronchoscopy prior to the initial TEF repair. At this time, the number of congenital fistulae should be documented.[33] The incidence of recurrent TEF appears to be lower in

Downloaded from www.chestjournal.org on April 6, 2009
Copyright © 2004 American College of Chest Physicians

patients who have had minimal mobilization of the esophagus and a one-layer, end-to-end esophageal anastamoses using interrupted absorbable sutures.[38] Ligation of the fistula (Duhamel/Beardmore technique) rather than complete division increases the incidence of recurrent TEF.[56] When the anastomotic lines of the tracheal closure and the esophageal anastomosis are contiguous, a fistula can develop more readily. Recurrent TEF is more common after a previous anastomotic leak, which in turn may be associated with excessive tension at the time of the anastomosis.[57–59] Recurrent TEF is also more common in children with congenital esophageal stenosis.[10] Injury to the tracheal closure or the esophageal anastomosis, usually following the passage of a catheter, can produce a recurrent fistula. It is important to make sure that there is separation between the suture line closing the posterior wall of the trachea and the sutures of the esophagus. A variety of techniques have been used to reduce the incidence of recurrent TEF, including the interposition of pleural, azygous vein, and vascularized pericardial flaps between the trachea and esophagus, and avoidance of damage to the distal esophagus.[1,58] The proximal esophagus should be mobilized with care to separate it from the posterior tracheal wall without breaching the tracheal wall. This mobilization allows anastomosis with minimal tension.

Recurrent TEFs usually present with cough, choking, and/or cyanosis with feeding, and/or recurrent pneumonia.[59] Recurrent TEF nearly always requires re-operation, either through a thoracotomy, or with fibrin glue, and preoperative bronchoscopy is important for defining the lesion and excluding a second TEF.[1] Multiple recurrences in the same patient have been reported.[59]

Recurrent Infections

Recurrent respiratory tract infections are common in infants with repaired EA/TEF, but become less frequent over time. In one small study,[43] "recurrent bronchitis," defined as a history of prolonged episodes of cough, was found in 90% of children with EA/TEF who had a history of frequent respiratory problems during infancy (85% of whom had been admitted to the hospital with pneumonia), but only 25% after 8 years of age. Bronchitis and pneumonia were associated with a history of dysphagia.[43] Thirty-two percent of subjects in another study[23] required antibiotics for respiratory infections in the past year. Ninety-six percent of children with a history of EA/TEF had normal chest radiographic findings, although one individual had bronchiectasis.[24] Approximately 1% of adults with repaired EA/TEF also have bronchiectasis.[27] Twenty-four percent of adults in one report[27] had at least one episode of bronchitis per year, and 8% of adults in another series[28] had recurrent pneumonia. In a small series[21] of nine patients with respiratory-esophageal fistula diagnosed in adulthood, bronchiectasis developed in two of nine subjects (22%).

Wheezing Illnesses

Wheezing illnesses appear to be quite common in patients with repaired EA/TEF. Forty-three percent of a small group of older children with a history of EA/TEF had a history of wheezing, and two thirds of these children had a diagnosis of asthma; however, only 25% of the children with asthma had a response to dilator, suggesting that in many of these children wheezing was due to other causes.[60] In another study,[43] asthma was diagnosed in 25% of children, and another 25% wheezed with exercise or respiratory infections; two thirds of the children with wheezing had a history of atopy. A third study[23] reported that the prevalence of recurrent dyspnea, night cough, and physician-diagnosed asthma were 28%, 37%, and 12%, respectively. Wheezing has been reported in 0 to 26%, and asthma in 14%, of adults with a history of EA/TEF[27,28]

Pulmonary Function

Persistent pulmonary function abnormalities are common in both children (Table 1) and adults (Table 2) with repaired EA/TEF, particularly in when there

Table 1—*Mean Values for Spirometry and Lung Volumes for Children With a History of EA/TEF**

Source	Year	Subjects, No.	Age Range, yr	Mean FVC	Mean FEV_1	Mean TLC	Mean RV/TLC	Mean FRC
Robertson et al[24]	1995	25		91	89	92		
Couriel et al[43]	1982	20	8–17	85	84	95		
Van Gysel et al[61]	1992	47		75	78	80		
LeSouëf et al[26]	1987	18	17 (mean)	Normal	Normal	Normal		
Agrawal et al[60]	1999	14	7–12	Low	Low		High	
Milligan and Levison[62]	1979	24	7–18					Abnormal

*Data are presented as % predicted unless otherwise indicated. FRC = functional residual capacity.

Downloaded from www.chestjournal.org on April 6, 2009
Copyright © 2004 American College of Chest Physicians

has been a history of aspiration. Infant pulmonary function testing (PFT) results performed within 1 year of the initial surgery in 16 subjects with EA/TEF (including patients with aspiration, GERD, and tracheomalacia) were abnormal in 56% of the subjects, with increased airway resistance in 38% of the infants and gas trapping in 19%.[63] However, infant PFT results correlated poorly with conventional PFT results performed in childhood.[60] While 43% of these patients had abnormal inspiratory flow rates during infant PFT, these measures were normal in all of the subjects during childhood, consistent with clinical observations that tracheomalacia in patients with a history of TEF tends to improve with time.[43,60] Other publications, [43,64] however, have reported that mean inspiratory flow rates were significantly reduced, or that abnormal inspiratory flows were present in 38 to 50% of children. Reduced inspiratory flows did not correlate with patient reports of a barking cough.[64]

Most pediatric studies[24,26,43] have reported that the mean FVC and the FEV_1 fall within the normal range in patients with repaired EA/TEF, although low mean values have been reported in some studies.[60,61] Adult studies[27,28] have reported that the mean FEV_1 was either normal or mildly reduced. Published data[24,26,43,61] consistently report that the mean total lung capacity (TLC) in children falls within the normal range (Table 1). However, in these studies,[24,26,43,61] mean values for FVC, FEV_1, and TLC were significantly lower than age-matched control subjects, even when they fell within normal limits.[24,43,60] As with children, the mean TLC in adults is normal.[27,28] One adult study[27] reported a mild elevation of the mean residual volume (RV) [Table 2].

While mean PFT values are stated to be normal in a number of publications, low values are common. One study reported that 15% of children and adults with repaired EA/TEF had an abnormal FVC, 25% had an abnormal FEV_1, and 14% had an abnormal forced expiratory flow between 25% and 75% of vital capacity. Eighteen percent of subjects had an abnormal TLC, and 41% had an abnormal RV/TLC ratio. In one adult study,[28] 33% of subjects had an abnormal TLC.

Table 2—*Mean Values for Spirometry and Lung Volumes for Adults With a History of EA/TEF**

Source	Subjects, No.	Mean Age, yr	FVC	FEV_1	FEV_1/FVC	TLC	RV
Biller et al[28]	12	26		78	82	99	
Chetcuti et al[27]	107	25	91	85		84	135

*Data are presented as % predicted unless otherwise indicated.

Several groups have indicated the proportion of patients with recognized patterns of ventilatory abnormalities. Restrictive ventilatory defects are present in 20 to 49% of patients, obstructive defects are present in 12 to 54%, mixed restrictive-obstructive defects are present in 0 to 11%, and normal lung function is present in 23 to 48% of patients.[24,61,62] In one series,[24] only 4% of patients had a severe restrictive, and only 8% had a moderate or severe obstructive ventilatory defect. Reduced airway function is associated with a history of GERD, choking spells during infancy, pneumonia during the first 4 years of life, and the presence of ongoing respiratory symptoms, but not with the amount of reflux on a concurrent 2-h esophageal pH probe.[26,60,64]

The only study[65] that has evaluated exercise capacity in this population studied eight children with the Bruce protocol, and found that exercise duration and maximal oxygen uptake was significantly reduced. However, it was unclear to what extent this was due to deconditioning, as many patients reported reduced levels of physical activity, generally because of parental anxiety.[65] Further studies of exercise performance in this population are required.

Bronchial Reactivity

Patients with a history of EA/TEF have an abnormally high prevalence of bronchial hyperreactivity, suggesting that airway reactivity in these individuals may be due to events in early childhood such as chronic aspiration, rather than atopy.[24,62] An abnormal methacholine or histamine challenge result (or significant response to bronchodilator) is present in 33 to 65% of patients.[43,62] In one article,[24] 48% of subjects had an abnormal response to methacholine challenge, but this was not a significantly different from the control population. In one series,[60] in 8% of subjects had a positive bronchodilator response; in another report,[64] 29% of children with airway obstruction responded to the bronchodilator. While 42% of adults had an abnormal FEV_1, none had an abnormal FEV_1/FVC or abnormal response to cold air challenge.[28]

Chest Wall Deformity

Chest wall deformities may be common in individuals with a history of EA/TEF. In one large study,[66] 16% had an isolated anterior chest wall asymmetry, 4% had an anterior chest wall deformity and scoliosis, and 6% had isolated scoliosis; 19% of the study population had associated congenital vertebral anomalies, and 42% of this subgroup had chest wall deformities. Chest wall deformity, including scoliosis, was more common in patients with more than

Downloaded from www.chestjournal.org on April 6, 2009
Copyright © 2004 American College of Chest Physicians

one previous thoracotomy, prior rib resection, and division of the serratus anterior and latissimus dorsi muscles or their nerve supply.[66] While anterior chest wall deformity was not associated with reduced pulmonary function, scoliosis was associated with a significant reduction in TLC, with a mean TLC of 98% predicted in subjects without scoliosis, and 88% in patients with scoliosis. Progressive scoliosis requiring surgical correction was essentially limited to patients with congenital vertebral anomalies. A small number of women with chest wall asymmetry and unequal breast sizes required breast reconstructive surgery.[67] In another study,[23] 21% of patients with EA/TEF had scoliosis.

Summary

Serious respiratory and GI complications, such as recurrent pneumonia, obstructive airway disease, airway hyperreactivity, GERD, and esophageal stenosis, are frequent in patients with a history of EA/TEF, although the frequency of such events appears to decrease quite significantly with age.[25,27,28,36,39,60] Respiratory and GI sequelae in patients with a history of EA/TEF result from a complex interplay of numerous potential complications, and some complications can exacerbate others. GERD, for example, can cause respiratory symptoms due to aspiration either directly, or by increasing the risk of esophageal stricture.[36,39]

As recurrent aspiration can lead to recurrent pneumonia and impaired pulmonary function, it is essential that in patients with a history of EA/TEF, known respiratory complications of EA/TEF are excluded before respiratory symptoms are assumed to be due to "asthma."[24,39,62] Common etiologies of respiratory symptoms in older individuals with a history of EA/TEF include retained secretions due to impaired mucociliary clearance secondary to tracheomalacia, and aspiration related to impaired esophageal peristalsis and/or esophageal stricture, recurrence of the TEF, and/or GERD.[16] Multiple causes may be present in an individual patient.[16,50]

Investigations that should be considered in patients with repaired EA/TEF and respiratory complaints include the following: (1) an upper GI series to assess esophageal motility, and should include injection barium with a catheter to exclude a recurrent TEF[38]; (2) radionuclide milk scanning or 24-h esophageal pH probe to exclude GERD; (3) esophagoscopy and esophageal biopsy to diagnose esophagitis and Barrett esophagus[1,23,28,41]; and (4) bronchoscopy to evaluate the presence (or degree) of tracheomalacia and to sample BAL fluid for fat-laden macrophages for evidence of aspiration.[16,68]

While airway fluoroscopy may have limited value for the diagnosis of tracheomalacia in this population, helical CT scanning and cine-CT scan evaluation may be diagnostic.[50,69,70] Three-dimensional CT scanning and virtual bronchoscopy may also be helpful in noninvasively identifying an "H"-type TEF.[71]

Many patients will require several investigations, and when respiratory symptoms persist after treatment of one problem, the patient should be evaluated for other potential conditions.[16] The presence of a previous fundoplication does not exclude the possibility of GERD, and some patients require an additional procedure(s) for recurrent GERD.[16] Some patients with severe swallowing dysfunction and a previous fundoplication may require surgical revision to allow passage of the food bolus into the stomach.[41]

Research Questions

Studies are needed to define the value of proton-pump inhibitors for preventing complications of EA/TEF after the initial repair, and to prevent the recurrence of esophageal strictures.[72] More research is needed to define the exercise capacity of older children and adults with a history of EA/TEF. The relationship between airway hyperreactivity and asthma in patients with EA/TEF, particularly in terms of pathophysiology and outcome, requires further investigation. As this population ages, studies evaluating whether patients with EA/TEF are at risk for premature development of COPD will be required, particularly since at least a subgroup of these patients will enter adulthood with reduced pulmonary function.[73]

References

1 Harmon CM, Coran AG. Congenital anomalies of the esophagus. In: O'Neill JA Jr, Rowe MI, Grosfeld JL, eds. Pediatric surgery. St. Louis, MO: Mosby; 1998; 941–967

2 Fine G, Ma CK. Alimentary tract. In: Kissane JM, Anderson WAD, eds. Anderson's pathology. St. Louis, MO: Mosby, 1985; 1055

3 Thilo EH, Rosenberg AA. The newborn infant. In: Hay WW Jr, Hayward AR, Levin MJ, et al, eds. Current pediatric diagnosis and treatment. Stamford, CO: Appleton & Lange, 1999; 58

4 Choudhury SR, Ashcraft KW, Sharp RJ, et al. Survival of patients with esophageal atresia: influence of birth weight, cardiac anomaly, and late respiratory complications. J Pediatr Surg 1999; 34:70–74

5 Emery JL, Haddadin AJ. Squamous epithelium in respiratory tract of children with tracheo-oesophageal fistula. Arch Dis Child 1971; 46:236–242

6 Benjamin B. Endoscopy in esophageal atresia and tracheoesophageal fistula. Ann Otol Rhinol Laryngol 1981; 90:376–382

Downloaded from www.chestjournal.org on April 6, 2009
Copyright © 2004 American College of Chest Physicians

7 Usui N, Kamata S, Ishikawa S, et al. Anomalies of the tracheobronchial tree in patients with esophageal atresia. J Pediatr Surg 1996; 31:258–262
8 Nakazato Y, Landin BH, Wells TR. Abnormal Auerbach plexus in the esophagus and stomach of patients with esophageal atresia and tracheoesophageal fistula. J Pediatr Surg 1986; 21:831–837
9 Dutta HK, Mathur M, Bhatnagar V. A histopathological study of esophageal atresia and tracheoesophageal fistula. J Pediatr Surg 2000; 35:438–441
10 Kawahara H, Imura K, Yagi M, et al. Clinical characteristics of congenital esophageal stenosis distal to associated esophageal atresia. Surgery 2001; 129:29–38
11 Källén K, Mastroiacovo P, Castilla EE, et al. VATER nonrandom association of congenital malformations: study based on data from four malformation registers. Am J Med Genet 2001; 101:26–32
12 Benson JE, Olsen MM, Fletcher BD. A spectrum of bronchopulmonary anomalies associated with tracheoesophageal malformations. Pediatr Radiol 1985; 15:377–380
13 McLaughlin FJ, Strieder DJ, Harris GBC. Tracheal bronchus: association with respiratory morbidity in childhood. J Pediatr 1985; 106:751–755
14 Wales PW, Drab SA, Connolly B, et al. Horseshoe lung in association with other foregut anomalies: what is the significance? J Pediatr Surg 2002; 37:1205–1207
15 Huang RY, Shapiro NL. Structural airway anomalies in patients with DiGeorge syndrome: a current review. Am J Otolaryngol 2000; 21:326–330
16 Delius RE, Wheatley MJ, Coran AG. Etiology and management of respiratory complications after repair of esophageal atresia with tracheoesophageal fistula. Surgery 1992; 112: 527–532
17 Vogt EC. Congenital atresia of the esophagus. AJR Am J Roentgenol 1929; 22:463–465
18 Gross RE. The surgery of infancy and childhood. Philadelphia, PA: WB Saunders, 1957
19 Foker JE, Linden BC, Boyle EM Jr, et al. Development of a true primary repair for the full spectrum of esophageal atresia. Ann Surg 1997; 226:533–541
20 Karnak I, Senocak ME, Hicsonmez A, et al. The diagnosis and treatment of H-type tracheoesophageal fistula. J Pediatr Surg 1997; 32:1670–1674
21 Azoulay D, Regnard JF, Magdeleinat P, et al. Congenital respiratory-esophageal fistula in the adult. J Thorac Cardiovasc Surg 1992; 104:381–384
22 Srikanth MS, Ford EG, Stanley P, et al. Communicating bronchopulmonary foregut malformations: classification and embryogenesis. J Pediatr Surg 1992; 27:732–736
23 Somppi E, Tammela O, Ruuska T, et al. Outcome of patients operated on for esophageal atresia: 30 years' experience. J Pediatr Surg 1998; 33:1341–1346
24 Robertson DF, Mobaireek K, Davis GM, et al. Late pulmonary function following repair of tracheoesophageal fistula or esophageal atresia. Pediatr Pulmonol 1995; 20:21–26
25 Engun SA, Grosfeld JL, West KW, et al. Analysis of morbidity and mortality in 227 cases of esophageal atresia and/or tracheoesophageal fistula over two decades. Arch Surg 1995; 130:502–508
26 LeSouëf PN, Myers NA, Landau LI. Etiologic factors in long-term respiratory function abnormalities following esophageal atresia repair. J Pediatr Surg 1987; 22:918–922
27 Chetcuti P, Myers NA, Phelan PD, et al. Adults who survived repair of congenital oesophageal atresia and tracheo-oesohageal fistula. BMJ 1988; 297:344–346
28 Biller JA, Allen JL, Schuster SR, et al. Long-term evaluation of esophageal and pulmonary function in patients with repaired esophageal atresia and tracheoesophageal fistula. Dig Dis Sci 1987; 32:985–990
29 Romeo C, Bonanno N, Baldari S, et al. Gastric motility disorders in patients operated on for esophageal atresia and tracheoesophageal fistula: long-term evaluation. J Pediatr Surg 2000; 35:740–744
30 Homnick DN. H-type tracheoesophageal fistula and congenital esophageal stenosis. Chest 1993; 103:308–309
31 Lindahl H, Louhimo I, Virkola K. Colon interposition or gastric tube? Follow-up study of colon-esophagus and gastric tube-esophagus patients. J Pediatr Surg 1983; 18:58–63
32 McKinnon LJ, Kosloske AM. Prediction and prevention of anastomotic complications of esophageal atresia and tracheoesophageal fistula. J Pediatr Surg 1990; 25:778–781
33 Spitz L, Kiely E, Brereton RJ. Esophageal atresia: five year experience with 148 cases. J Pediatr Surg 1987; 22:103–108
34 Malmfors G, Okmian L. End to end anastomosis in oesophageal atresia: clinical application of experimental experiences. Z Kinderchir 1985; 40:67–70
35 Carachi R, Stokes KB, Brown TCK. Esophageal anastomosis: an experimental model to study the anastomotic lumen and the influence of transanastomotic tube. J Pediatr Surg 1984; 19:90–93
36 Chittmittrapap S, Spitz L, Kiely EM, et al. Anastomotic stricture following repair of esophageal atresia. J Pediatr Surg 1990; 25:508–511
37 Hicks LM, Mansfield PB. Esophageal atresia and tracheoesophageal fistula: review of thirteen years' experience. J Thorac Cardiovasc Surg 1981; 81:358–363
38 Myers NA, Beasley SW, Auldist AW. Secondary esophageal surgery following repair of esophageal atresia with distal tracheoesophageal fistula. J Pediatr Surg 1990; 25:773–777
39 Chetcuti P, Phelan PD. Respiratory morbidity after repair of oesophageal atresia and tracheo-oesophageal fistula. Arch Dis Child 1993; 68:167–170
40 Jolley SG, Johnson DG, Roberts CC, et al. Patterns of gastroesophageal reflux in children following repair of esophageal atresia and distal tracheoesophageal fistula. J Pediatr Surg 1980; 15:857–862
41 Curci MR, Dibbins AW. Problems associated with a Nissen fundoplication following tracheoesophageal fistula and esophageal atresia repair. Arch Surg 1988; 123:618–620
42 Spitz L. Esophageal atresia and tracheoesophageal fistula in children. Curr Opin Pediatr 1993; 5:347–352
43 Couriel JM, Hibbert M, Olinsky A, et al. Long term pulmonary consequences of oesophageal atresia with tracheo-oesophageal fistula. Acta Paediatr Scand 1982; 71:973–978
44 Rideout DT, Hayashi AH, Gillis DA, et al. The absence of clinically significant tracheomalacia in patients having esophageal atresia without tracheoesophageal fistula. J Pediatr Surg 1991; 26:1303–1305
45 Schwartz MA, Filler RM. Tracheal compression as a cause of apnea following repair of tracheoesophageal fistula: treatment by aortopexy. J Pediatr Surg 1980; 15:842–848
46 Benjamin B. Tracheomalacia in infants and children. Ann Otol Rhinol Laryngol 1984; 93:438–442
47 Filler RM, Messineo A, Vinograd I. Severe tracheomalacia associated with esophageal atresia: results of surgical treatment. J Pediatr Surg 1992; 27:1136–1141
48 Cozzi DA, Capocaccia P, Roggini M, et al. Respiratory status of infants with esophageal atresia. Pediatr Surg Int 2001; 17:92–96
49 Benjamin B. Endoscopy in esophageal atresia and tracheoesophageal fistula. Ann Otol Rhinol Laryngol 1981; 90:376–382
50 Malone PS, Kiely EM. Role of aortopexy in the management

Downloaded from www.chestjournal.org on April 6, 2009
Copyright © 2004 American College of Chest Physicians

of primary tracheomalacia and tracheobronchomalacia. Arch Dis Child 1990; 65:438–440
51 Corbally MT, Spitz L, Kiely E, et al. Aortopexy for tracheomalacia in oesophageal anomalies. Eur J Pediatr Surg 1993; 3:264–266
52 Spitz L. Dacron-patch aortopexy. Prog Pediatr Surg 1986; 19:117–119
53 Panitch HB, Kekilkian EN, Molley RA, et al. Effect of altering smooth muscle tone on maximal expiratory flows in patients with tracheomalacia. Pediatr Pulmonol 1990; 9:170–176
54 Filler RM, Forte V, Chait P. Tracheobronchial stenting for the treatment of airway obstruction. J Pediatr Surg 1998; 33:304–311
55 Lam WWM, Tam PKH, Chan F-L, et al. Esophageal atresia and tracheal stenosis: use of three-dimensional CT and virtual bronchoscopy in neonates, infants, and children. AJR Am J Roentgenol 2000; 174:1009–1012
56 Touloukian RJ. Long term results following repair of esophageal atresia by end to side anastomosis and ligation of the tracheo-esophageal fistula. J Pediatr Surg 1981; 16:983–987
57 Ein SH, Stringer DA, Stephens CA, et al. Recurrent Tracheoesophageal fistulas: seventeen-year review. J Pediatr Surg 1983; 18:436–441
58 Vos A, Ekkelkamp S. Congenital tracheoesophageal fistula: preventing recurrence. J Pediatr Surg 1996; 31:936–938
59 Ghandour KE, Spitz L, Brereton RJ, et al. Recurrent tracheooesophageal fistula: experience with 24 patients. J Pediatr Child Health 1990; 26:89–91
60 Agrawal L, Beardsmore CS, MacFayden UM. Respiratory function in childhood following repair of oesophageal atresia and tracheoesophageal fistula. Arch Dis Child 1999; 81:404–408
61 Van Gysel D, De Boeck K, Lerut T, et al. Pulmonary status during childhood after corrected esophageal atresia [abstract]. Eur Respir J 1992; 15(suppl):103s
62 Milligan DWA, Levison H. Lung function in children following repair of tracheoesophageal fistula. J Pediatr 1979; 95: 24–27
63 Beardsmore CS, MacFayden UM, Johnstone MS, et al. Clinical findings and respiratory function in infants following repair of oesophageal atresia and tracheo-oesophageal fistula. Eur Respir J 1994; 7:1039–1047
64 Chetcuti P, Phelan PD, Greenwood R. Lung function abnormalities in repaired oesophageal atresia and tracheo-oesophageal fistula. Thorax 1992; 47:1030–1034
65 Zaccara Z, Felici F, Turchetta A, et al. Physical fitness testing in children operated on for tracheoesophageal fistula. J Pediatr Surg 1995; 30:1334–1337
66 Cudmore RE. Oesophageal atresia and tracheo-eosophageal fistula. In: Lister J, Irving IM, ed. Neonatal surgery. 3rd ed. London, UK: Butterworths, 1990; 231–258
67 Chetcuti P, Myers NA, Phelan PD. Chest wall deformity in patients with repaired esophageal atresia. J Pediatr Surg 1989; 24:244–247
68 Benjamin B, Cohen D, Glasson M. Tracheomalacia in association with congenital tracheoesophageal fistula. Surgery 1976; 79:504–508
69 Inoue K, Yanagihara J, Ono S. Utility of helical CT for diagnosis and operative planning in tracheomalacia after repair of esophageal atresia. Eur J Pediatr Surg 1998; 8:355–357
70 Kimura K, Soper RT, Kao SC. Aortosternopexy for tracheomalacia following repair of esophageal atresia: evaluation by cine-CT and technical refinement. J Pediatr Surg 1990; 25:769–772
71 Le SDV, Lam WWM, Tam PKH, et al. H-type tracheoesophageal fistula: appearance on three-dimensional computed tomography and virtual bronchoscopy. Pediatr Surg Int 2001; 17:642–643
72 Swarbrick ET, Gough AL, Foster CS et al. Prevention of recurrence of oesophageal stricture, a comparison of lansoprazole and high-dose ranitidine. Eur J Gastroenterol Hepatol 1996; 8:431–438
73 Sunyer J, Soriano J, Anto JM, et al. Sensitization to individual allergens as risk factors for lower FEV_1 in young adults: European Community Respiratory Health Survey. Int J Epidemiol 2000; 29:125–130

Downloaded from www.chestjournal.org on April 6, 2009
Copyright © 2004 American College of Chest Physicians

Long-term Complications of Congenital Esophageal Atresia and/or Tracheoesophageal Fistula *

Thomas Kovesi and Steven Rubin

Chest 2004;126; 915-925
DOI 10.1378/chest.126.3.915

This information is current as of April 6, 2009

Updated Information & Services	Updated Information and services, including high-resolution figures, can be found at: http://www.chestjournal.org/content/126/3/915.full.html
References	This article cites 68 articles, 14 of which can be accessed free at: **http://www.chestjournal.org/content/126/3/915.full.html#ref-list-1**
Open Access	Freely available online through CHEST open access option
Permissions & Licensing	Information about reproducing this article in parts (figures, tables) or in its entirety can be found online at: http://www.chestjournal.org/site/misc/reprints.xhtml
Reprints	Information about ordering reprints can be found online: http://www.chestjournal.org/site/misc/reprints.xhtml
Email alerting service	Receive free email alerts when new articles cit this article. sign up in the box at the top right corner of the online article.
Images in PowerPoint format	Figures that appear in CHEST articles can be downloaded for teaching purposes in PowerPoint slide format. See any online article figure for directions.

AMERICAN COLLEGE OF CHEST PHYSICIANS®

Downloaded from www.chestjournal.org on April 6, 2009
Copyright © 2004 American College of Chest Physicians