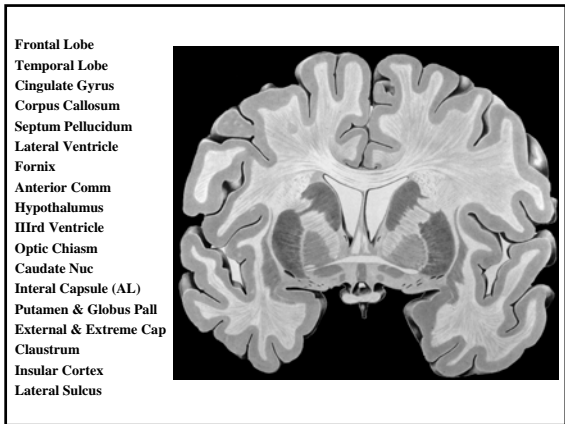
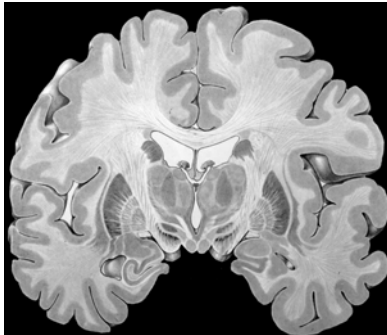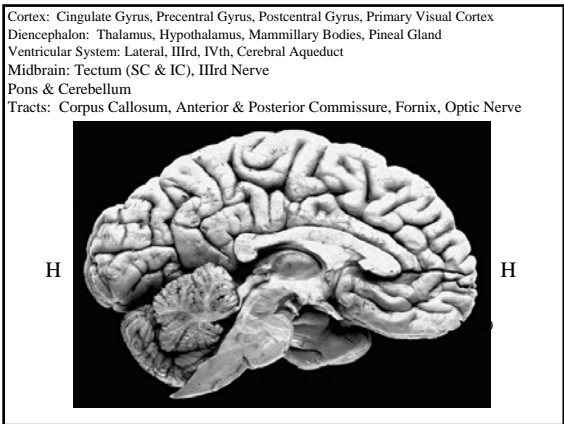
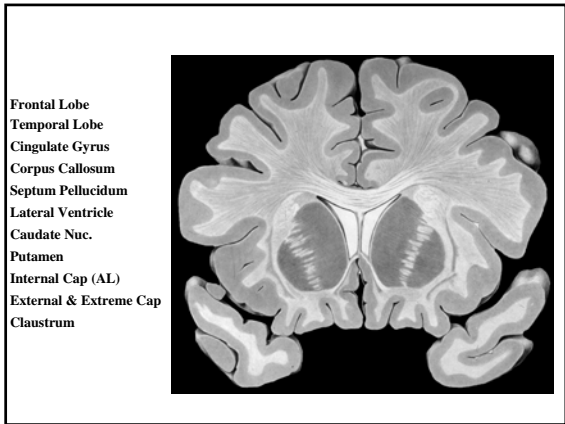
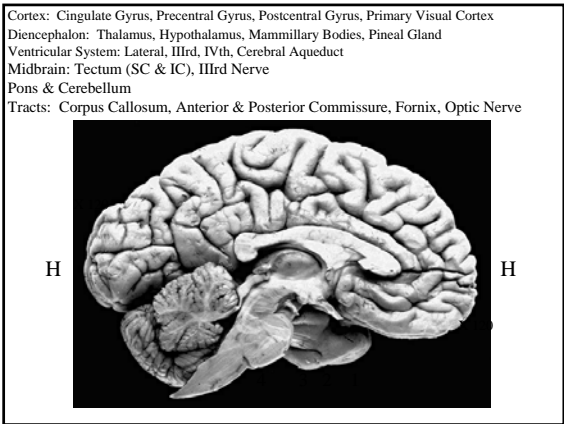
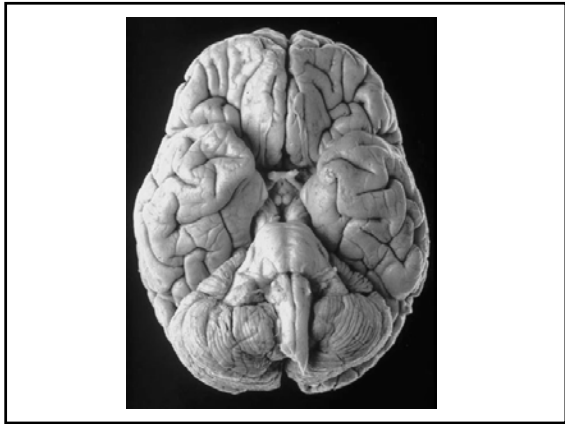
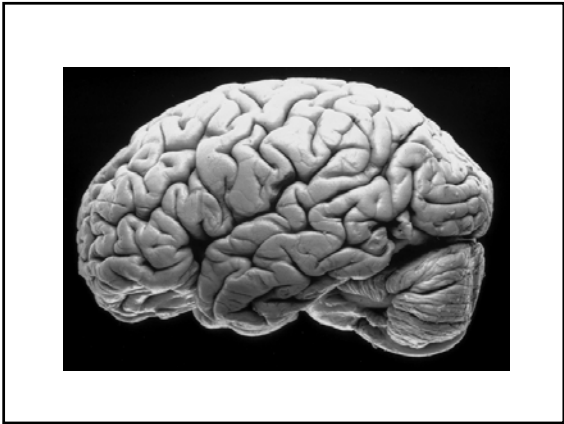Cortex: Cingulate Gyrus, Precentral Gyrus, Postcentral Gyrus, Primary Visual Cortex
 Diencephalon: Thalamus, Hypothalamus, Mammillary Bodies, Pineal Gland
 Ventricular System: Lateral, IIIrd, IVth, Cerebral Aqueduct
 Midbrain: Tectum (SC & IC), IIIrd Nerve
 Pons & Cerebellum
 Tracts: Corpus Callosum, Anterior & Posterior Commissure, Fornix, Optic Nerve



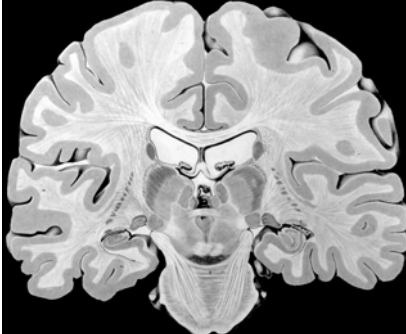
Cingulate Gyrus
 Corpus Callosum
 Lateral Ventricle (Body)
 Choroid Plexus
 Fornix
 IIIrd Ventricle
 Thalamus
 Hypothalamus
 Mammillary Bodies
 Caudate Nuc
 Internal Cap (PL)
 Putamen
 Globus Pall (Ext and Int)
 Subthalamic Nuc
 Substantia Nigra
 Temporal Lobe
 Uncus
 Amygdala & Hipp Form
 Inferior Horn (LV)
 Clastrum
 External and Extreme Cap
 Insular Cortex




Cortex: Cingulate Gyrus, Precentral Gyrus, Postcentral Gyrus, Primary Visual Cortex
 Diencephalon: Thalamus, Hypothalamus, Mammillary Bodies, Pineal Gland
 Ventricular System: Lateral, IIIrd, IVth, Cerebral Aqueduct
 Midbrain: Tectum (SC & IC), IIIrd Nerve
 Pons & Cerebellum
 Tracts: Corpus Callosum, Anterior & Posterior Commissure, Fornix, Optic Nerve



Cingulate Gyrus
 Corpus Callosum
 Lateral Ventricle
 Fornix
 Posterior Comm
 Cerebral Aqueduct
 Midbrain
 Basis Pedunculi
 Pons
 Caudate Nuc
 Thalamus
 Medial Geniculate
 Lateral Geniculate
 Internal Cap (PL)
 Hippocampal Form
 Caudate Nuc (Tail)
 Inferior Horn (LV)
 Temporal Lobe
 Heschl Gyri



Cortex: Cingulate Gyrus, Precentral Gyrus, Postcentral Gyrus, Primary Visual Cortex
 Diencephalon: Thalamus, Hypothalamus, Mammillary Bodies, Pineal Gland
 Ventricular System: Lateral, IIIrd, IVth, Cerebral Aqueduct
 Midbrain: Tectum (SC & IC), IIIrd Nerve
 Pons & Cerebellum
 Tracts: Corpus Callosum, Anterior & Posterior Commissure, Fornix, Optic Nerve



Frontal Lobe
 Temporal Lobe
 Occipital Lobe
 Cingulate Gyrus (2X)
 Lateral Ventricle (2X)
 Caudate Nuc (2X)
 Forix
 IIIrd Ventricle
 Thalamus
 Pulvinar
 Hippocampal Form
 Cerebellum
 Primary Visual Cortex
 Internal Cap (AL, Genu, PL)
 Putamen
 Globus Pallidus
 Optic Radiations
 External & Extreme Cap
 Insular Cortex
 Lateral Fissure

