

Colitis: Causes

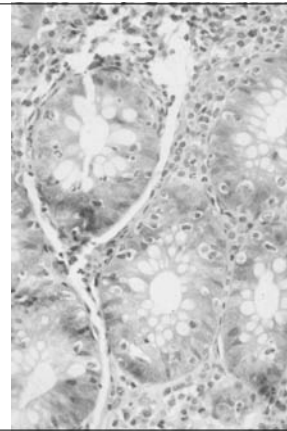
- **Infection** (viral, bacterial, fungal, parasitic)
- Toxicity (drugs)
- Allergy
- **Ischemia**
- Radiation
- Graft-vs-host disease
- **Idiopathic**

Idiopathic Inflammatory Bowel Disease (IBD)

- Incidence: 1-2 million Americans
- Frequent in Jews (Ashkenazi)
- Genetic predisposition:
1st degree family members 30-100 times; twin studies
- Candidate genes on chromosomes 12 and 16
- Interaction of epithelial factors (trefoil factors) and immune system factors (interleukins, IFN-gamma, TNF)

Idiopathic Inflammatory Bowel Disease Definition

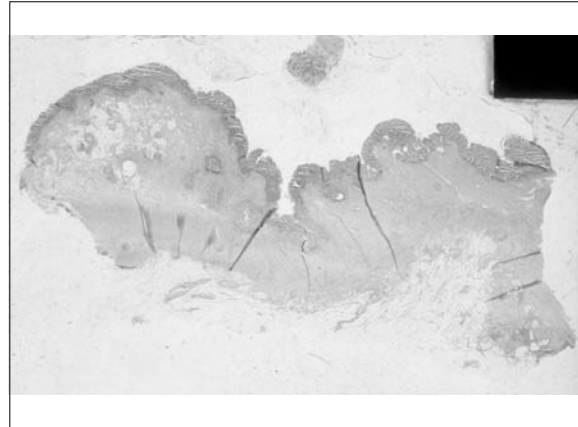
- Chronic relapsing inflammatory disease
- Unknown etiology
- Exacerbations
- Remissions
- Bloody diarrhea



Crohn's Disease Classification

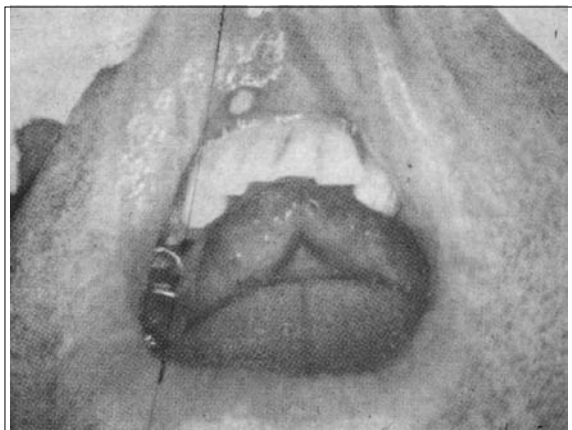
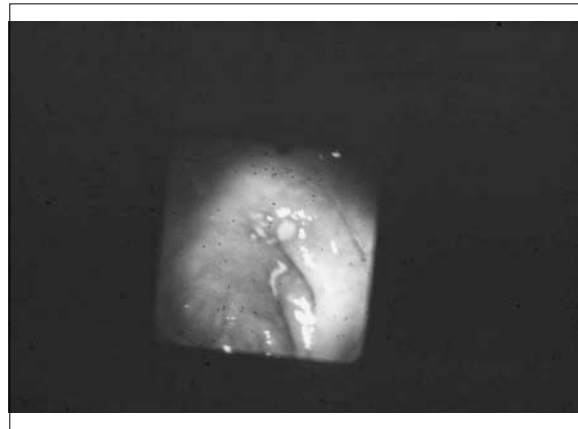
- Terminal ileitis (40%)
- Ileocolitis (30%)
- Colitis (30%)
- Upper GI Crohn's disease (2 - 20%)





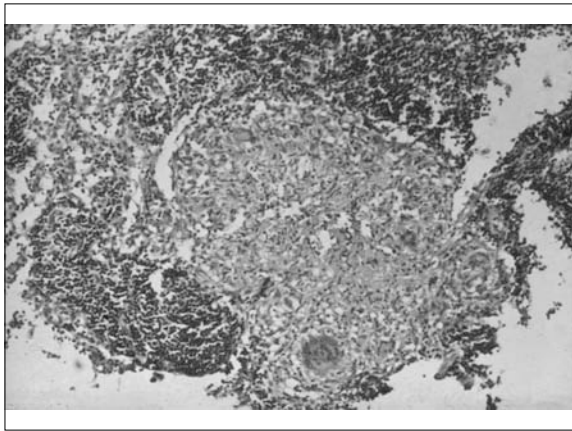
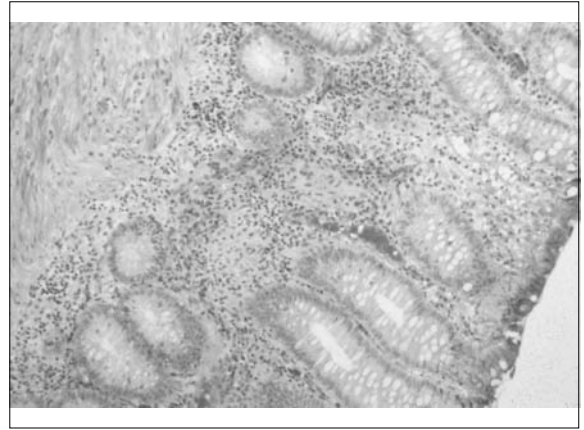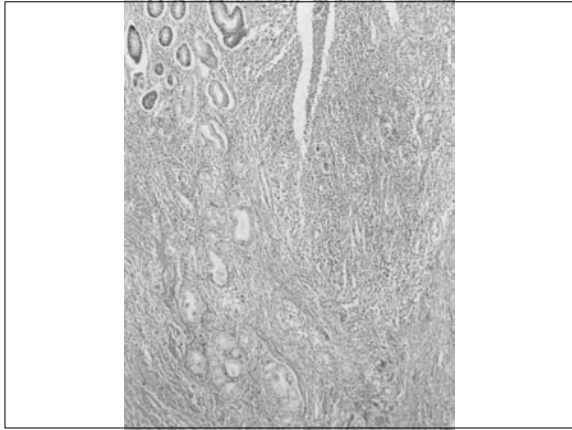
Crohn's Disease Macroscopic Pathology

- Segmental
- Skip areas
- Stiff thickened bowel wall
- Linear ulcers
- Cobblestone mucosa
- Creeping fat
- Rectal sparing



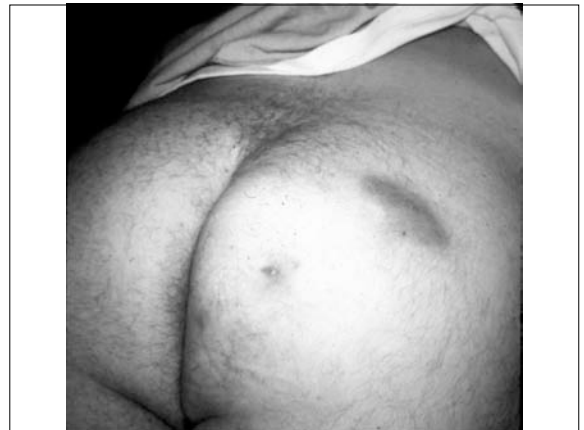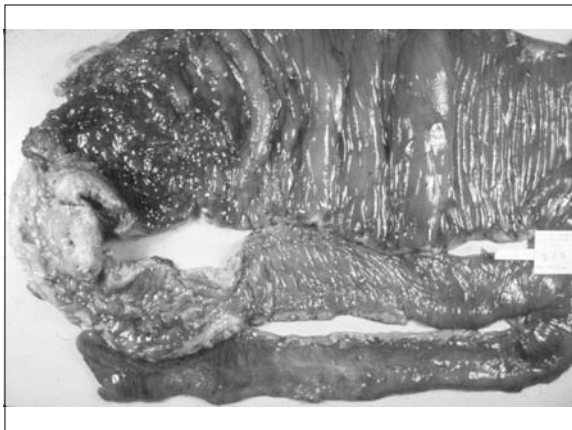Crohn's Disease Microscopic Pathology

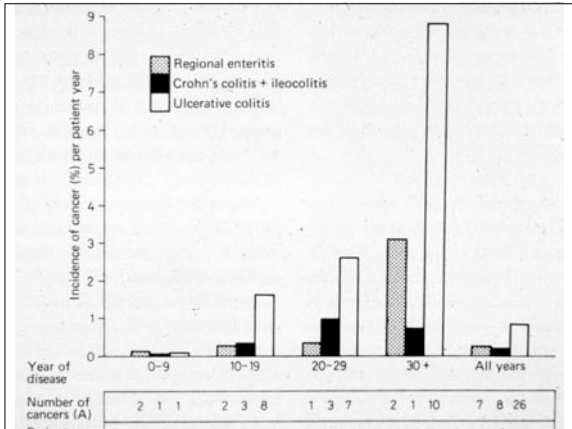
- Necrosis of individual epithelial cells
- Cryptitis and crypt abscesses
- **Aphthoid ulcers**
- **Fissures**
- **Patchy** chronic inflammation, **transmural**
- **Granulomas**
- Crypt irregularity
- Metaplasia: Paneth cell, **pyloric**



Crohn's Disease
Complications


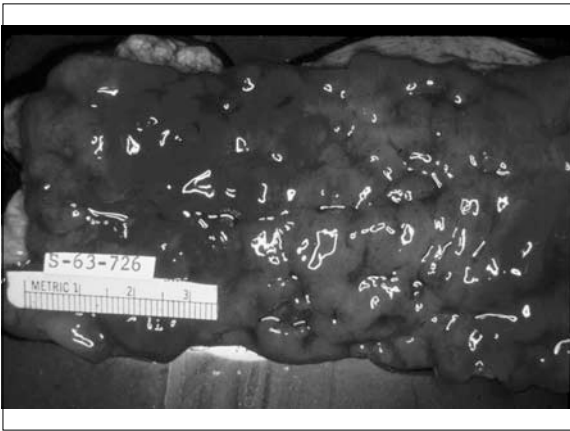
- Stricture
- Fistulae
- Dysplasia
- Cancer (4 - 20x)





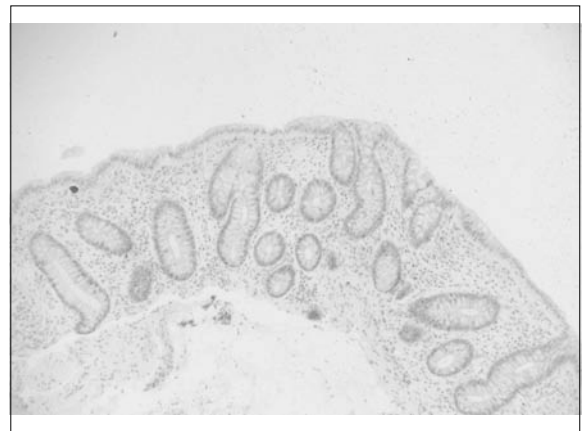
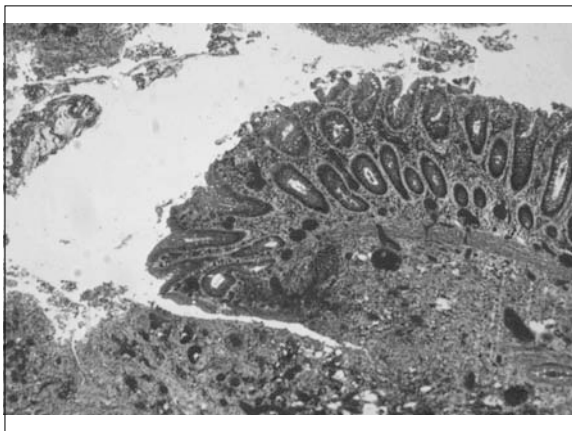
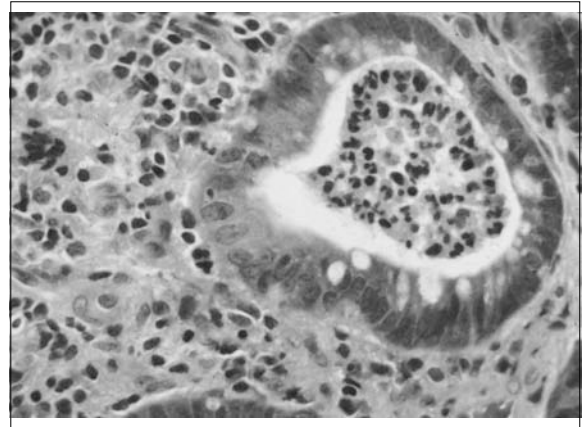
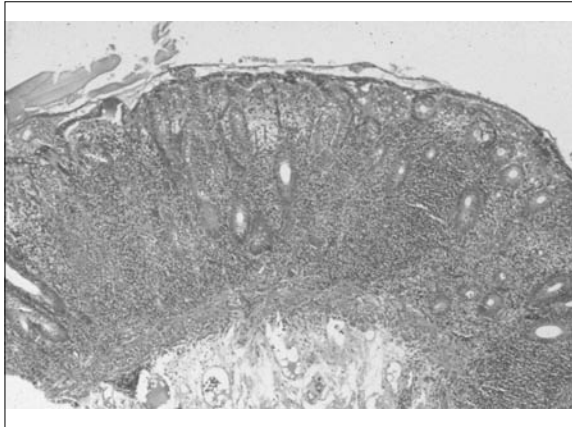
Ulcerative Colitis Classification

- Ulcerative proctitis / proctosigmoiditis (60 - 80%)
- Left-sided colitis (30 - 40%)
- Extensive colitis / pancolitis (10 - 20%)



Ulcerative Colitis Macroscopic Pathology

- Diffuse colitis, usually most marked distally
- Red friable mucosa
- Broad-based ulcers
- Pseudopolyps
- Shortened colon
- Backwash ileitis



Ulcerative Colitis

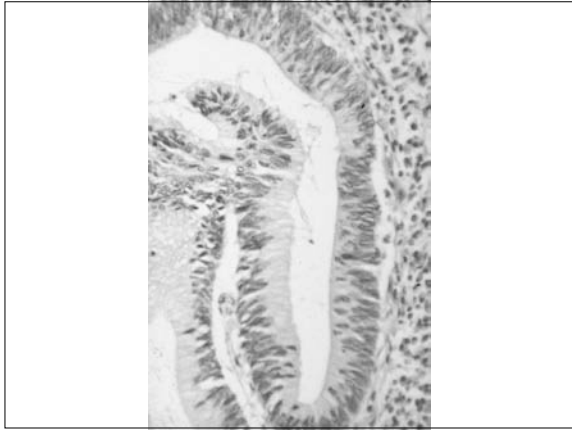
Microscopic Pathology

- Diffuse mucosal inflammation (plasma cells, lymphocytes, eosinophils, neutrophils)
- Cryptitis
- Crypt abscesses
- Ulcers
- Crypt irregularity and atrophy
- Metaplasia: Paneth cell

Ulcerative Colitis

Complications

- Toxic megacolon
- Dysplasia
- Carcinoma:
 - 2% after 20 years of left-sided colitis
 - 10% after 20 years of pancolitis
 - 15 - 20% after 30 years of pancolitis



Provisional Schema of Patient Management
Related to Classification of Dysplasia

Biopsy Classification	Implications for Patient Management
Negative Normal mucosa Inactive (quiescent) colitis Active colitis	Continue regular follow-up
Indefinite Probably negative	
Unknown Probably positive	Institute short-interval follow-up
Positive Low-grade dysplasia	Institute short-interval follow-up <i>or</i> Consider colectomy, especially with gross lesion, after dysplasia is confirmed
High-grade dysplasia	Consider colectomy after dysplasia is confirmed

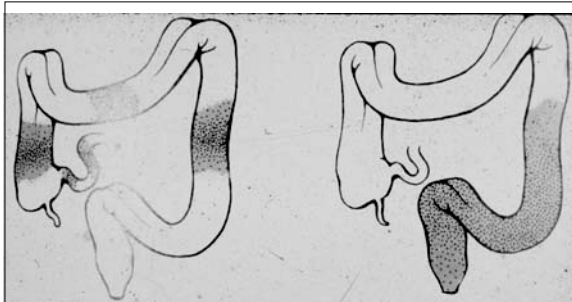
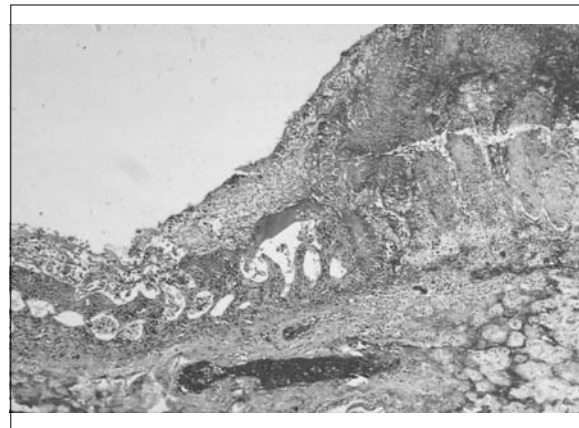
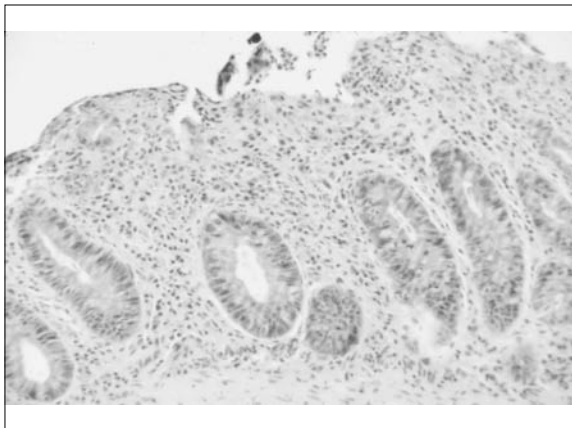
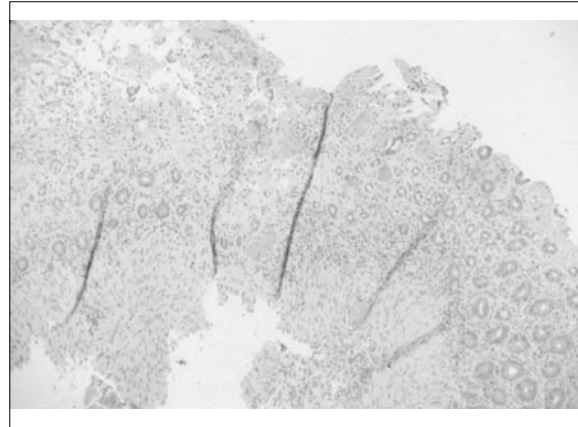



Figure 18-50. Crohn's disease (left) and ulcerative colitis (right). While Crohn's disease typically involves the small and large intestine in a segmental manner with intervening "skip" areas, ulcerative colitis is generally a disease of contiguity that starts in the rectum and progresses in a retrograde fashion to involve varying

IBD: Differential Diagnosis

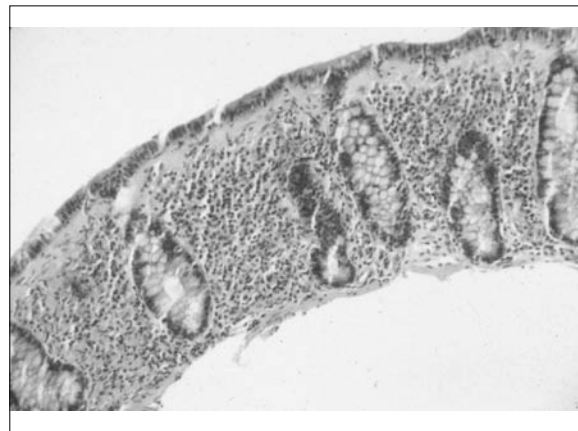- Infectious colitis
- Ischemic colitis
- Microscopic colitis
- Irritable bowel syndrome (IBS)





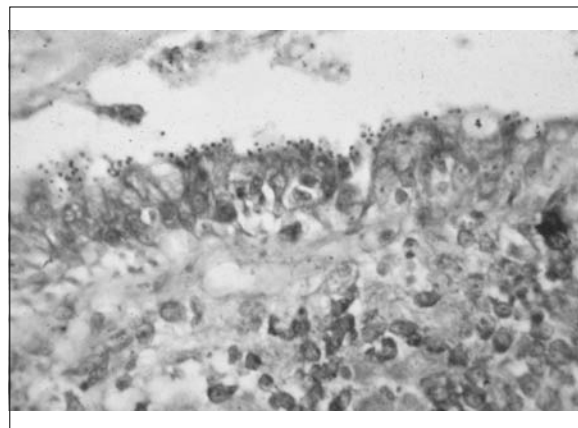
Microscopic Colitis

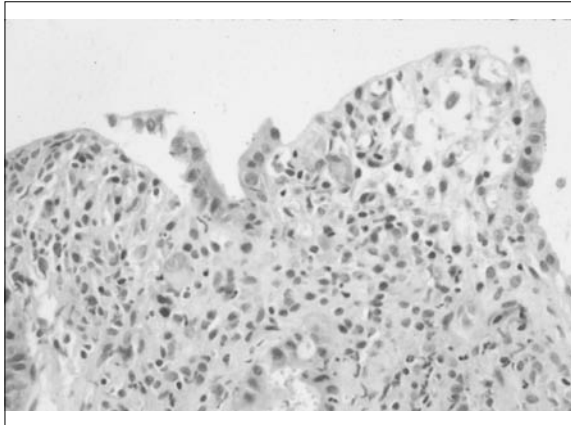
- **Lymphocytic colitis:** lymphocytic infiltration of surface and crypt epithelium, increased inflammatory cells in the lamina propria
- **Collagenous colitis:** same as above plus increased subepithelial collagen
- **Clinical:** watery diarrhea, endoscopically normal colon, middle aged adults
- **Cause:** unknown, association with celiac disease, multiple drugs, family hx of intestinal diseases



Diarrhea in AIDS

- Cryptosporidiosis
- Microsporidiosis
- Isosporiasis
- Cyclosporiasis
- CMV colitis
- MAC enterocolitis
- HIV enteropathy





Extra-intestinal Manifestations

1. *Manifestations the severity of which correlate with severity of bowel disease*
 - a. Colitic arthritis: migratory and transient, usually not deforming; knees, hips, ankles, elbows, wrists
 - b. Skin lesions: Pyoderma gangrenosum and erythema nodosum
 - c. Ocular lesions: uveitis and episcleritis
 - d. Calcium oxalate kidney stones:

Extra-intestinal Manifestations

2. *Manifestations the severity of which doesn't correlate with severity of bowel disease*
 - a. Sacroiliitis and ankylosing spondylitis: progressive and crippling; not ameliorated by colectomy or improvement of bowel disease
 - b. Sclerosing cholangitis: leads to biliary cirrhosis; not improved by colectomy