

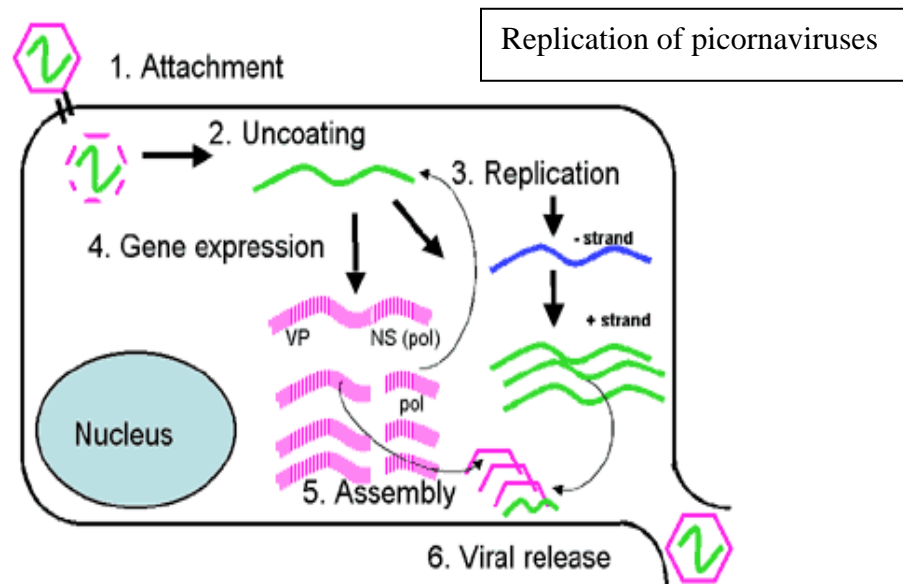
ENTEROVIRUSES AND OTHER GI VIRUSES

Overview: Gastrointestinal viruses are major causes of morbidity and mortality throughout the world. All of the viruses discussed in this section enter the body through the gastrointestinal tract but not all disease entities associated with these viruses are confined to the GI tract. In this section we will discuss enteroviruses, rotavirus, and the caliciviruses. The enteroviruses cause a number of different disease syndromes whereas the effects of rotavirus and calicivirus infections are largely confined to gastrointestinal illness. Because of the myriad of diseases caused by enteroviruses and their importance, the emphasis of this section will largely be on enteroviruses.

Enteroviruses: Enteroviruses belong to the family picornaviridae, very small (pico) RNA viruses, which also includes aphthoviruses, cardioviruses and rhinoviruses. Historically the enteroviruses have been divided into subgroups consisting of the polioviruses, coxsackieviruses, echoviruses, and the so-called “newer enteroviruses”.

Molecular Biology and Pathogenesis: Enteroviruses are small, non-enveloped single stranded positive sense RNA viruses. They enter the body through the gastrointestinal tract, usually from fecally contaminated material (ID mantra- the world is covered in a thin layer of feces). The virus multiplies in the submucosal lymphatic tissues of the gut and passes to regional lymph nodes and the reticuloendothelial system. At this point they are usually contained by the immune system resulting in subclinical infection; however, in some cases heavy sustained replication occurs and the virus is shed into the bloodstream causing disease at many distant sites. The virus penetrates host cells, uncoats and releases its RNA into the cytoplasm within minutes. Inside the cell, RNA is translated into a polyprotein which is subsequently cleaved to form:

- Four viral capsid proteins which make up the icosohedral covering of the virus protecting the viral RNA and allowing the virus to attach to its host cell receptor
- Eight non-structural proteins whose functions include RNA replication, protease activity, and inhibition of host cell protein synthesis



While the virus originally replicates in the gut and lymphoreticular system few inflammatory or necrotic lesions are noted in these tissues. In contrast, the targets of the viremic stage usually show significant inflammation and necrosis which correlates with the titer of virus present and produces much of the morbidity associated with the infection.

Polioviruses

Polioviruses are the cause of poliomyelitis, a systemic infectious disease of varying severity that usually affects the central nervous system and can result in paralysis.

Host Range and Pathogenesis: Humans are the only natural host and reservoir of polioviruses. Like all enteroviruses, polio enters through the gut, replicates in the submucosal lymphoid tissue and spreads to the reticuloendothelial system. In certain susceptible hosts, the virus then spreads through the blood to the central nervous system where it causes extensive necrosis of neurons in the gray matter of the spinal cord and brain. Polioviruses affect primarily motor and autonomic neurons. Destruction of neurons is accompanied by an inflammatory infiltrate of polymorphonuclear leukocytes, lymphocytes, and macrophages. The most characteristic feature of the histopathology of polio is the distribution of the lesions. The main sites of attack are the gray matter of the anterior horn of the spinal cord and the motor nuclei of the pons and medulla.

Epidemiology: Before 1900 in the United States polioviruses were ubiquitous and resulted in mostly inapparent early childhood infection. With rising hygienic standards, infection was delayed until later in childhood. This created a pool of susceptible hosts and the conditions for an epidemic. The increase in paralytic disease seen in the 1950's was probably due to the fact that while infected infants are protected by maternal antibody older children have no natural immunity. With the introduction of the first polio vaccine in 1955 dramatic reductions were seen in polio cases in the US and other developed countries. The last case of wild type polio in the United States occurred in 1979 and polio has now been eradicated from the Western hemisphere and Europe. The goal of the WHO is to eradicate polio worldwide; however, polio infections still occur in developing countries.

Clinical Features: The incubation period of polio (the period from presumed contact until the onset of the prodrome) is 9-12 days. The manifestations of infection by polioviruses range from inapparent illness to severe paralysis and death. At least 95% of infections are asymptomatic. Symptomatic disease can take a number of increasingly severe forms:

- Abortive poliomyelitis, which occurs in 4-8% of infections, is characterized by fever, headache, sore throat, listlessness, anorexia, vomiting and abdominal pain. Neurologic exam is normal and the illness lasts only a few days.
- Nonparalytic poliomyelitis differs from abortive polio in that there are signs of meningeal irritation and the systemic symptoms are generally more severe. However, it is clinically indistinguishable from other enterovirus-associated meningitides and full recovery is the norm.
- Spinal paralytic poliomyelitis occurs in 0.1% of polio infections. In children there is generally a biphasic course with "minor" and "major" illnesses. The minor illness corresponds with the viremia and the symptoms mimic those of abortive polio. The patient recovers after 1-3 days of mild illness, remains well for 2-5 days but then abruptly becomes ill with headache, fever, vomiting, and neck stiffness. Characteristic of the onset of this major illness is muscle pain which is relieved by motion. This phase of the major illness lasts 1-2 days before

frank weakness and flaccid paralysis ensue. The severity of the disease is variable ranging from a single portion of one muscle to quadriplegia. Paralysis is generally asymmetric with proximal muscles more affected than distal and continues to evolve until the fever dissipates in 2-3 days. Sensory loss is very rare in polio and should suggest another diagnosis.

- Bulbar paralytic poliomyelitis is characterized by paralysis of the muscles innervated by the cranial nerves. This results in dysphagia, nasal speech, and dyspnea with cranial nerves 9 and 10 most commonly affected. Involvement of the vasomotor and respiratory centers is less common but results in rapid pulse, hypoxia, and elevated blood pressure followed by circulatory collapse which can result in death.
- Polioencephalitis is manifested by confusion and changes in mental status. It is uncommon and occurs primarily in infants. Paralysis, if it occurs, is spastic suggesting upper motor neuron disease.

Diagnosis: Poliovirus can be isolated from throat secretions in the first week of illness and from feces for several weeks; however, unlike other enteroviruses, they are rarely isolated from CSF. The diagnosis can also be made by testing paired acute and convalescent sera for a rise in antibody titer.

Prevention: Poliovirus vaccines have been used effectively for more than 30 years and have wiped out wild type poliovirus infections from the Western hemisphere. Two vaccine formulations are currently available, the oral polio vaccine (OPV) and the inactivated polio vaccine (IPV). For many years, the OPV, a live attenuated vaccine, was the mainstay of vaccination campaigns throughout much of the world. It is given orally, was more immunogenic than the original IPV and because it was excreted in the feces of vaccinated individuals, allowed for the spread of vaccine virus to unimmunized individuals. However, as cases of naturally occurring poliovirus infection fell in the developed world the risk of the very-rare but real paralytic disease resulting from the OPV virus itself actually exceeded that of naturally occurring polio and the United States has since recommended that only the IPV be used in this country. The original Salk IPV was introduced in 1955. Since then it has undergone modifications that have made it more immunogenic- at least equal to OPV. IPV has an excellent safety record and can safely be given to immunocompromised individuals as it contains no live virus.

Coxsackieviruses, echoviruses, and newer enteroviruses

Coxsackieviruses, echoviruses, and newer enteroviruses share many characteristics of polioviruses including their structure, mode of replication, pathogenesis, and epidemiology. Despite their name, enteroviruses usually do not cause symptomatic infections of the gastrointestinal tract. Their portal of entry is through the GI tract but end-organ damage occurs in a variety of other systems.

Central Nervous System Infections: Some of the more serious manifestations of enteroviral infections involve the CNS.

- Aseptic Meningitis is characterized by signs and symptoms of meningeal irritation in the absence of bacteria or fungi. Most community acquired cases of aseptic meningitis are caused by viruses and of these 90% are caused by group B coxsackieviruses and echoviruses. Infants younger than 3 months have the highest rates of clinically recognized aseptic meningitis. In older children and adults the severity of the disease varies widely but the typical patient has a

prodrome of fever and chills followed by headache, stiff neck and symptoms of an upper respiratory tract infection. These infections are usually self-limited and uncomplicated. The diagnosis depends upon examination of the cerebrospinal fluid which usually shows clear fluid with 10-500 white cells. Initially these white cells may be predominantly PMNs but the differential will invariably shift to a lymphocyte predominance over the first 1-2 days of illness. In general CSF glucose and protein concentrations are normal or very slightly elevated.

Enteroviruses can be detected in the CSF by cell culture or PCR. The differential diagnosis includes partially treated bacterial meningitis, other viral meningitis such as arbovirus, LCMV, and HIV associated meningitis, Lyme disease, and leptospirosis. Treatment consists of symptomatic relief. Pleconaril, an orally administered picornaviral capsid-stabilizing drug, decreases the duration of symptoms but has been disappointing in clinical trials of severely ill patients and the company is reportedly not pursuing further development.

- Encephalitis is a well-described but relatively rare manifestation of echovirus and coxsackievirus CNS infection. The enteroviruses (including polio) account for 11-22% of viral encephalitis cases. Children and young adults are most commonly affected with clinical manifestations ranging from lethargy and drowsiness to seizures and coma. The prognosis, other than in infants, is excellent.
- Chronic meningoencephalitis is seen in patients with hereditary or acquired defects in B-lymphocyte function. Most reported cases are in children with X-linked agammaglobulinemia. Most cases are caused by echoviruses. Nervous system manifestations may vary from mild nuchal rigidity and headache to seizures and ataxia. Enterovirus can be recovered from the CSF for periods of months to years. In many, if not most, affected persons the disease ends fatally. Prophylactic use of intravenous immune globulin is currently used to prevent enteroviral infection in patients with B cell defects and it has been used less successfully to treat those with chronic meningoencephalitis.
- Paralysis is occasionally associated with coxsackie and echovirus infection. Coxsackievirus A7 and enterovirus 71 have been associated with outbreaks of flaccid paralysis. Paralytic disease caused by nonpolio enteroviruses is usually less severe than poliovirus associated paralysis. Paresis is not permanent. Guillain-Barre syndrome, transverse myelitis and Reye's syndrome have all been associated with enteroviruses.

Exanthems, or rashes, are common features of enterovirus infections. They can take many different forms, and with the exception of hand-foot-and-mouth disease, are not distinctive enough to make a definitive diagnosis.

- Morbilliform exanthems are fine, erythematous, maculopapular (both flat and raised) rashes that are common manifestations of echovirus infections especially during summer outbreaks. The most common serotype associated with this rash is echovirus 9. The rash usually appears simultaneously with fever and starts on the face spreading to the chest and extremities.
- Roseoliform exanthems are discrete, nonpruritic (not itchy), salmon-pink macules and papules which appear on the face and upper chest. They are usually associated with a prodrome of fever and pharyngitis. The rash does not appear until after the patient has defervesced and generally lasts from 1-5 days. These infections are quite contagious and usually occur in young children. Echovirus 16 is most commonly associated with this syndrome.

- Hand-Foot-and-Mouth disease, not to be confused with foot and mouth disease, is a distinctive vesicular eruption usually caused by coxsackie virus A16 or enterovirus 71. It is most common in children under the age of 10 and is characterized by fever and vesicles in the oral cavity, hands and feet. The palms and soles may be affected. The lesions are tender and consist of mixed papules and clear vesicles with surrounding erythema. The differential diagnosis is chickenpox; however, while patients with HFM disease invariably have oral mucosal lesions, oral lesions are less common in chickenpox. Patients with chickenpox generally appear more ill than those with HFM disease. However, it can be difficult to differentiate the two infections and this may account for “repeat” cases of chickenpox.
- Generalized vesicular eruptions are caused most frequently by coxsackievirus A9 and echovirus 11. The lesions are similar to those of HFM disease but occur in crops on the head, trunk, and extremities. Unlike chickenpox, they do not evolve into pustules and scabs.
- Herpangina is a well-characterized vesicular rash involving the pharynx and soft palate that is accompanied by fever, sore throat, and pain on swallowing. It is usually seen in summer outbreaks and group A coxsackieviruses are most commonly associated with the syndrome. The illness begins suddenly with fever, vomiting, myalgia and headache which resolve quickly. Sore throat and pain on swallowing precede the development of the oral lesions. Prompt recovery over a week occurs in all cases.

Respiratory disease is common in enterovirus infections.

- Colds: Many enteroviruses cause undifferentiated febrile illness with sore throat, cough and coryza (runny nose). They account for a large number of the viruses recovered from children with summer colds. Coxsackieviruses A21 and A24 produce common cold symptoms indistinguishable from rhinovirus infections except for a higher percentage of fever. Echovirus 11 is the most common echovirus cause of cold-like syndromes. Other respiratory tract manifestations of enteroviral infection include:
- Epidemic pleurodynia is an acute disease characterized by fever and sharp, spasmodic pain in the chest or upper abdomen. Group B coxsackieviruses are the most common etiological agents and can cause major epidemics. Pleurodynia is a disease of muscle (not the pleura) and tenderness mimicking the pain of the infection can be elicited by placing pressure on the affected muscle. It is characterized by the abrupt onset of spasmodic pain with fevers which peak one hour after each paroxysm and subside as the pain decreases. The severity of the pain varies widely and generally covers a wide area; however the spasmodic and paroxysmal character of the pain is its hallmark. Most patients are ill for 4-6 days and adults are more severely affected than children. The disease may relapse and can occur over a several month period; however, all patients eventually recover completely.

Myopericarditis is defined as inflammation of the myocardium and pericardium. Enteroviruses are the most common viral etiologic agents accounting for at least 50% of all cases of acute myopericarditis. All group B coxsackieviruses, group A types 4 and 16 and echoviruses types 9 and 22, have been definitively linked to myopericarditis. The virus reaches the heart during the viremia that follows replication in the reticuloendothelial system. Virus replication appears to occur in the myofibers and results in scattered myofiber necrosis followed by focal inflammatory infiltrates. Healing is accompanied by a variable degree of interstitial fibrosis and evidence of myocyte loss.

Clinical manifestations of enteroviral myopericarditis are variable. It occurs at all ages but has a special predilection for physically active adolescents and young adults. The incidence in males is twice that in females. In over 60% of cases, an upper respiratory illness precedes the onset of cardiac symptoms by 7-14 days. Cardiac involvement is heralded by dyspnea, chest pain, fever and malaise. Chest pain is usually in the precordial area and is usually dull and relieved by sitting up and forward. On EKG abnormalities are almost always present, echocardiograms may show dilatation and dysfunction of the heart muscles, and serum levels of myocardial enzymes are usually elevated. Frank congestive heart failure is present in about 20% of cases. Chronic dilated cardiomyopathy leading to chronic congestive heart failure is the most dreaded complication of enteroviral myopericarditis; however, up to one third of all patients will have some permanent sequelae including EKG changes, cardiomegaly and chronic constrictive pericarditis. Management is primarily supportive. Intravenous immune globulin (IVIG) which is pooled immunoglobulin from multiple blood donors has shown some value in clinical trials.

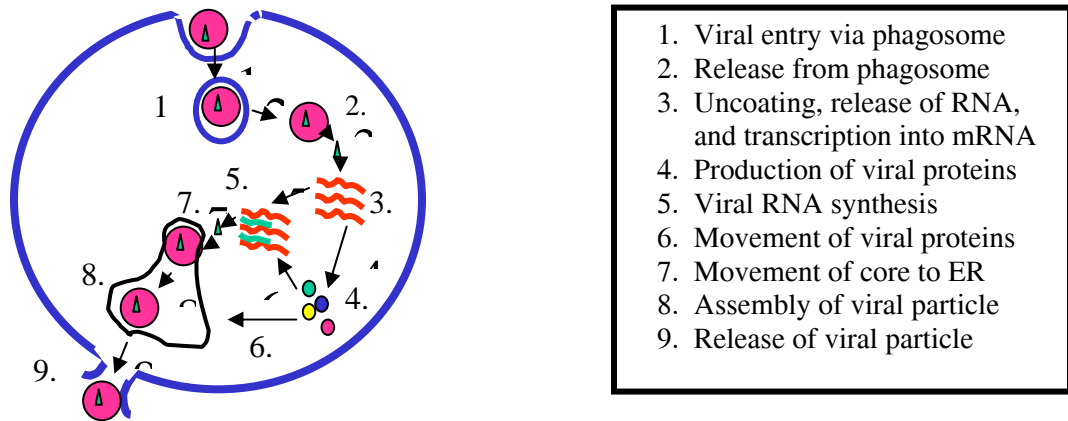
Enterovirus infection of the newborn infant is a serious problem as neonates are uniquely susceptible to enterovirus infections. Group B coxsackieviruses serotypes 2-5 and echovirus 11 are the most common culprits. Most neonatal enteroviral infections are acquired directly from the mother; however, nosocomial outbreaks have been reported. Incidence and severity generally reflect the occurrence of enteroviral disease in the community. Most neonates are infected in the perinatal period and 60-70% of women transmitting the infection will have fever in the week prior to delivery. Once the newborn is infected enterovirus spreads systemically through the bloodstream where it has particular tropism for the heart and liver. Neonates can form neutralizing antibody responses to enteroviral infections, but they lack the macrophage activity necessary to control infection completely. Symptoms develop between 3 and 7 days of life and are generally mild and nonspecific. One third of cases have a biphasic illness with a period of 1-7 days of well-being between the initial symptoms and more serious manifestations. Generalized enterovirus disease in the newborn most often occurs in one of two characteristic clinical syndromes: myocarditis or hepatitis. Myocarditis, which is often accompanied by encephalitis, is usually caused by Group B coxsackieviruses. Fulminant hepatitis is characterized by hypotension, profuse bleeding, jaundice and multiple organ failure and is usually the result of echovirus 11 infection. The diagnosis of neonatal enterovirus infection is most rapidly made by PCR or viral culture. Virus may be detected in a number of secretions including urine, feces, blood, CSF and oropharyngeal secretions. The management of neonatal enterovirus infection is supportive. IVIG may be considered as may pleconaril; however, results with this drug have been disappointing to date.

Acute hemorrhagic conjunctivitis is a contagious ocular infection characterized by pain, swelling of the eyelids, and subconjunctival hemorrhage that generally resolves spontaneously within a week. Enterovirus 70 is the major cause of this syndrome and has been responsible for tens of millions of cases worldwide since 1969. It has resulted in epidemics in Africa, Asia, and Europe. Unlike most other enteroviral infections, acute hemorrhagic conjunctivitis is probably spread from fingers directly to the eye. It is highly contagious and spreads rapidly. It begins abruptly with burning, pain, photophobia and watery discharge in one eye followed a few hours later by symptoms in the other eye. Conjunctival hemorrhage can be pinpoint or occupy the entire conjunctiva. Most cases resolve spontaneously but a few may be followed by motor paralysis mimicking poliomyelitis.

Rotaviruses

Rotaviruses are large, non-enveloped RNA viruses that are responsible for 10-20% of all diarrhea related deaths in children world-wide and account for up to 120,000 hospitalizations in the US each year.

Molecular Biology and Pathogenesis: Rotaviruses are members of the Reovirus family and derive their name from their wheel-like appearance. Their genome is double-stranded RNA which is segmented. The segmented nature of the genome allows for reassortment (mixing up) of strands when two different strains co-infect a single host cell. This allows the virus to adapt to combat host defenses, although major antigenic shifts like those seen in influenza A don't appear to occur. As the genomic RNA is double stranded, it can't function directly as mRNA so these viruses package their own RNA polymerase to make mRNA. The figure below shows the replicative cycle of rotaviruses.



Rotaviruses can be grouped into seven antigenic groups named A-G. Only groups A-C cause disease in humans with group A viruses responsible for most human disease worldwide. Rotaviruses are spread through the oral-fecal route and, lacking an envelope, are quite resistant to gastric acid (as well as a number of disinfectants). They are highly infectious with the human infectious dose being as low as 1 pfu. They replicate in the mature villus epithelial cells of the small intestine. Infection of the villus epithelium results in the loss of these cells. This results in a decrease in the absorptive area of the small intestine and can result in lactase deficiency, a common sequela of viral and bacterial gastroenteritis. The exact mechanism by which rotaviruses cause vomiting and diarrhea is not known although loss of absorptive area may play a role. It is postulated that these viruses may produce an enterotoxin but this has yet to be verified.

Epidemiology: Rotaviruses occur worldwide and almost everybody over the age of 2 has been infected with at least one strain. Infections in temperate climates are strikingly seasonal occurring over a 3-4 month period in the winter. In North America outbreaks begin in late autumn in Mexico and spread north and east ending up in eastern Canada by spring. There are essentially no cases in the summer months.

Clinical Features: Infections can range from asymptomatic to severe gastroenteritis. In general the first infection is the most severe. Rotavirus infection, like many viral

gastroenteritis, involves both vomiting and diarrhea usually accompanied in severe cases by nausea and a high fever. Diarrhea is usually watery without mucous or blood. Fecal leukocytes, which are usually not present in viral diarrheas may be present in severe rotavirus infections. Dehydration and electrolyte imbalance are the most common reasons for hospitalization and death from rotavirus infection.

Diagnosis: Diagnosis can be suspected clinically particularly in a febrile young infant with both vomiting and diarrhea in the winter. Most clinical labs today use either ELISAs to detect rotavirus antigens in stool samples or PCR. Electron microscopy of stool samples will show the characteristic wheel shaped viral particles, but this is beyond the capability of most hospital labs.

Treatment: Treatment is supportive with replacement of fluid and electrolytes either orally or IV. Early feeding is encouraged as it appears to promote enterocyte regeneration and decreases intestinal permeability. Antidiarrheal medications are not recommended (the body is trying to get rid of the virus for a reason).

Prevention: Good hygiene (washing hands!!) and chemical disinfection are the best ways to prevent rotavirus spread in communities and households. Despite the fact that almost everyone is infected and mounts an immune response to infection by age 2, immunity to rotavirus is not complete and infections do occur in older children and adults (watch out during your peds rotation!). Usually, however, these infections are milder than in young infants. A vaccine, Rotashield, was licensed for use in the US in 1998. The vaccine was highly effective; however, after 10 months on the market, 15 cases of intussusception (telescoping of the bowel on itself- a nasty complication that requires surgical repair and can be fatal) were reported in young vaccinated infants. In July of 1999 the FDA halted vaccination and the vaccine has since been pulled from the market. This decision, which seems reasonable in the US where few children actually die from rotavirus infection, is controversial in the developing world where death rates are much higher.

Caliciviruses **“The Love Boat Bugs”**

Caliciviruses are single stranded, positive sense RNA viruses that are responsible for many outbreaks of gastrointestinal illness across the world. They derive their name from the “cuplike” indentations on their surfaces.

Molecular biology and pathogenesis: Caliciviruses are simple, non-enveloped viruses whose genome encodes four polypeptide products:

- Helicase which is responsible for unwinding double helical regions in RNA during recombination, replication, transcription and splicing.
- Protease which is responsible for cleaving the single polypeptide into its functional parts
- RNA polymerase which is responsible for replicating RNA
- Capsid which covers the RNA genome

Caliciviruses cannot be grown in cell culture so much of their biology is understood through molecular biology techniques. Caliciviruses are spread through the oral-fecal route. Being non-enveloped they are able to survive gastric acid and pass to the small bowel where they cause disease. Acute calicivirus infection results in a reversible lesion

in the jejunum characterized by blunting of the villi which appears within 24 hours of infection. The mucosa remains relatively intact and neutrophils are seen in the lamina propria. Diarrhea is associated with transient malabsorption of D-xylose and fat and with decreased activity of brush-border enzymes. Infection is not associated with detectable toxin production and the exact mechanism behind the diarrhea and vomiting is not known. Of note, virus shedding in stool is highest in the first 24-48 hours after illness and is rarely detected beyond 72 hours after illness onset suggesting patients are most infectious while symptomatic.

Epidemiology: Caliciviruses are widespread and common. Disease can occur throughout the year and affects all age groups. Almost any type of food that has contact with contaminated water (shellfish) may serve a vehicle for outbreaks of calicivirus gastroenteritis. Contaminated drinking water and even swimming pools and lakes in which infected people have swum have served as vehicles for outbreaks. The viruses are hardy and can withstand chlorination and even heat inactivation (cooking doesn't eliminate risk of transmission). They are responsible for the several recent large outbreaks of diarrheal illness reported on cruise ships.

Clinical manifestations: Caliciviruses were first identified in point-source outbreaks of gastroenteritis and remain important causes of such outbreaks. The features of a calicivirus outbreak are useful in empirical diagnosis and include a short lived illness (2-3 days duration) with vomiting as a predominant symptom, an incubation period of 24-48 hours and high secondary attack rates. Generally both vomiting and diarrhea occur and myalgias, malaise and fever are common. Disease manifestations generally last 48-72 hours and remit without sequelae.

Diagnosis: Diagnosis can be suspected on clinical and epidemiological grounds and by the absence of any other pathogen. Laboratory tests are generally not useful. Electron microscopy of stool samples can reveal the characteristic virus particles but is not used much outside the research setting. An ELISA test for calicivirus antigens is in preparation but not yet widely available.

Treatment and Prevention: Treatment is supportive only. Oral fluid replacement is generally all that is necessary although some individuals will require IV rehydration. No vaccine is available and prevention is primarily through judicious food and water handling.



“The happiest place on earth...”