

**Review Session #2
2006**

List of teams:

1. Group 1 - Room 304 - Dr. Dobkin
2. Group 2 - Room 306 - Dr. Yin
3. Group 3 - Room 308 - Dr. Lowy
4. Group 4 - Room 310 - Dr. Neu
5. Group 5 - Room 316 - Dr. Prince
6. Group 6 - Room 320 - Dr. Hammer
7. Group 7 - Room 322 - Dr. Gordon
8. Group 8 - Room 324 - Dr. Sobieszcyk
9. Dental Students

Practice question: Who heroically shot a rabid dog in Harper Lee's To Kill a Mockingbird?

1. **Atticus Finch**
2. Scout Finch
3. Walter Cunningham
4. Tom Robinson
5. Boo Radley

Team Leader Board

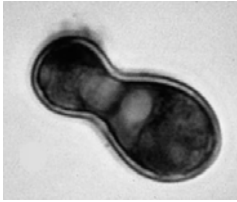
A 34 year old HIV infected male is admitted to your service with cough and upper lobe pulmonary infiltrates with cavities. His sputum acid fast stain is positive. Which of the following statements regarding his illness is correct?

1. **This presentation would be most consistent with reactivation of an old focus of infection.**
2. The PPD (tuberculin) skin test is very helpful in making the diagnosis of this infection acutely.
3. The chest x-ray appearance of this disease in HIV-infected persons always appears the same as in non-HIV infected persons.
4. Pathogenesis of this infection involves aspiration of the patient's own normal oral flora.
5. The organism causing his illness is a facultative anaerobe.

A 37-year old male with HIV is admitted with fever, headache and confusion. A lumbar puncture reveals cloudy fluid, an increased number of lymphocytes and a positive India Ink prep. He is treated with an agent that causes fever and shaking chills during the infusion. Which one of the following agents was used to treat this infection?

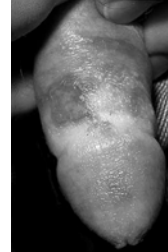
1. Caspofungin [a beta (1,3)-D-glucan synthase inhibitor].
2. **Amphotericin (a membrane disrupting agent).**
3. Voriconazole (an ergosterol synthesis inhibitor)
4. Fluconazole (an ergosterol synthesis inhibitor)
5. 5-Fluorocytosine (a nucleic acid inhibitor).

A forest ranger who has been working on the preservation of a beaver dam develops a nodule on his cheek that fails to respond to antibiotics. A biopsy grows the organism illustrated below. This is an example of which of the following pathogens?



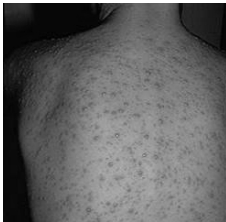1. Aspergillus fumigatus
2. **Blastomyces dermatitidis**
3. Cryptococcus neoformans
4. Histoplasma capsulatum
5. Coccidioides immitis

A 22 year old man develops a painful cluster of fluid-filled vesicles and an ulcer on the shaft of his penis one week following exposure to a new sexual partner. Which of the following statements concerning the cause of this syndrome is **not** true?



1. The agent of this infection can cause both primary and recurrent infections.
2. The site of latency for this agent is the dorsal root ganglion.
3. **Once infected with this agent, a person is immune from getting infected with another viral serotype.**
4. Immunosuppression due to organ transplantation, HIV, etc. can lead to very severe manifestations of this infection.
5. Effective therapy exists to treat this infection.

A healthy 10 year old boy who immigrated from eastern Europe 5 days ago develops fever and a vesicular rash. Which of the following statements is true?



1. This infection is not spread easily person-to-person.
2. If not treated with an antiviral agent, he has a high likelihood of developing disseminated disease to vital organs and dying.
3. Once he recovers, he will have full immunity and never experience any form of recurrent disease.
4. **A live attenuated viral vaccine is effective at preventing this disease.**
5. He should be given aspirin to reduce his fever and make him feel better.

Which of the following is **not** true concerning the Herpesvirus family?

1. Anti-VCA and anti-EBNA antibodies may be used to diagnose Epstein-Barr virus (EBV) infection.
2. Cytomegalovirus (CMV) downregulates MHC Class I expression to decrease effectiveness of the cellular immune response.
3. They share the characteristics of causing latency and persistence in the human host.
4. **Persons infected with varicella-zoster virus (VZV) can shed the virus and transmit it to others even when no symptoms of disease are present.**
5. Some of the viruses in this family are oncogenic.

A 10-year old girl awakens to find a bat in her room. She tells her mother who is concerned about rabies. Which of the following statements concerning rabies is correct?

1. Postexposure prophylaxis must be given immediately (within 24 hours) to be effective.
2. She should receive a single dose of rabies immune globulin, but should defer receipt of the inactivated rabies vaccine because the rabies immune globulin may interfere with antibody production.
3. **She should receive a series of 5 doses of an inactivated rabies vaccine and a single dose of rabies immune globulin.**
4. If no evidence of a bat bite is seen, no further intervention is needed.
5. The goal of postexposure prophylaxis is the development of a cellular immune response to the rabies virus.

Team Leader Board

A 10 year old boy is brought by his mother to the CUMC-NYPH emergency room in August complaining of fever and headache. A lumbar puncture reveals a slightly elevated opening pressure, 30 white blood cells with 100% lymphocytes, a mildly elevated protein and a normal glucose. The alert ER doctor notes that this is the 8th similar case she has seen in the past week. This is most likely an example of:

1. Herpes simplex encephalitis.
- 2. Enteroviral meningitis.**
3. West Nile encephalitis.
4. Pneumococcal meningitis.
5. Meningococcal meningitis.

Which statement most accurately describes the pathogenesis of enteroviruses?

1. They are blood-borne pathogens that are commonly transmitted by sexual contact and injection drug use.
2. Their envelope protects them from digestion by stomach acid and allows them to enter the body through the gastrointestinal tract.
- 3. They enter the body through the gastrointestinal tract, undergo local replication in the lymph nodes leading to viremia and seeding of target organs (e.g., central nervous system, heart).**
4. Their primary site of replication is in the epithelial cells of the small intestine.
5. They predominantly cause serious disease through the mechanism of antibody dependent enhancement

A 35-year old woman who fondly remembers receiving the live attenuated oral polio vaccine as a child is surprised to learn that her infant daughter will only receive the inactivated polio vaccine. Which of the following statements made by her pediatrician concerning polio vaccines is true?

1. The inactivated polio vaccine has replaced the live attenuated vaccine because inactivated vaccines in general are more immunogenic than live attenuated vaccines.
2. The inactivated polio vaccine is effective at achieving herd immunity.
3. The live attenuated polio vaccine is no longer used anywhere in the world.
4. The inactivated polio vaccine is used despite its association with a small risk of causing paralytic disease.
- 5. The inactivated polio vaccine, unlike the live attenuated vaccine, may safely be administered to immunocompromised individuals.**

A family of four decides to take a Caribbean vacation on a cruise ship. Five days into the trip, the teenage son develops fever, nausea, vomiting and diarrhea. He recovers within 24 hours but the rest of his family and dozens of other tourists on the ship develop the same syndrome. Which of the following is the likely etiologic agent?

1. Human herpesvirus 8
2. Enterovirus type 70
- 3. Calicivirus**
4. Rotavirus
5. Adenovirus

Team Leader Board

A 65 year old man develops fever, sore throat, severe muscle aches and cough. He sees his doctor who obtains a nasopharyngeal swab which is positive for influenza A virus by a rapid test. Which of the following is ***not*** true?

1. Influenza virus binds to sialic acid residues on the surface of respiratory epithelial cells.
2. The virus enters the cell through receptor mediated endocytosis.
3. The mechanism of viral uncoating is well worked out for influenza virus.
- 4. Pandemic influenza arises from a single point mutation in the hemagglutinin gene.**
5. Bacterial superinfection is a serious threat to this person.

Which of the following is true concerning HIV pathogenesis?

1. After a person recovers from acute HIV-1 infection, the virus remains latent in the body until the clinical syndrome of AIDS develops.
2. Most new infections are caused by viruses that predominantly use the CXCR4 coreceptor.
3. **Latently infected resting memory CD4+ T cells present a substantial barrier to eradication of infection.**
4. Persons heterozygous for the 32 base pair deletion in CCR5 are less susceptible to infection with HIV.
5. Neutralizing antibodies play an important role in downregulating viral replication in the body during acute infection.

A 22-year old female law student presents to her physician with fever, fatigue, swollen lymph glands, sore throat, oral ulcers and a maculopapular rash. She reports having a new sexual partner during the past month and did not use condoms. A serum RPR and tests for EBV- and CMV-related mononucleosis are all negative. Which set of tests would you do next to establish the diagnosis?

1. **HIV-1 ELISA antibody, Western blot and plasma HIV-1 RNA level.**
2. HIV-1 ELISA antibody and Western blot.
3. Plasma HIV-1 RNA level.
4. Rapid HIV-1 antibody test.
5. HIV-1 ELISA antibody, plasma HIV-1 RNA level and CD4 cell count.

Which of the following would be the least likely to be an opportunistic complication of HIV disease?

1. *Pneumocystis jiroveci* (formerly carinii) pneumonia
2. **Herpes simplex encephalitis**
3. Cytomegalovirus retinitis
4. Cryptococcal meningitis
5. Disseminated *Mycobacterium avium-intracellulare* infection

Team Leader Board

Which of the following best describes the mechanism of action of nucleoside reverse transcriptase inhibitors (NRTIs) vs. HIV-1?

1. NRTIs immediately bind to the HIV-1 reverse transcriptase once they enter the cell.
2. NRTIs bind to the gp41 transmembrane protein of HIV-1 and prevent virus-cell fusion.
3. NRTIs prevent integration of the HIV-1 proviral DNA.
4. NRTIs bind to the structural proteins of HIV-1 and prevent virion maturation.
5. **NRTIs must be converted to their triphosphate forms to be active against the viral reverse transcriptase.**

Which of the following statements is not true concerning the non-nucleoside reverse transcriptase inhibitor (NNRTI) class of anti-HIV drugs?

1. **NNRTIs are active against both HIV-1 and HIV-2.**
2. NNRTIs are active immediately upon entry into cells.
3. NNRTIs are vulnerable to the rapid emergence of resistance.
4. NNRTIs in combination with two nucleoside analogs (NRTIs) form one of the current standard-of-care HIV treatment regimens.
5. NNRTIs are useful in the prevention of maternal-fetal transmission of HIV.

Which of the following statements is true concerning the protease inhibitor (PI) class of anti-HIV drugs?

1. PIs should not be used with non-nucleoside reverse transcriptase inhibitors (NNRTIs) because of problems with drug interactions.
2. PIs act prior to the reverse transcription step of virus replication.
3. PIs must undergo intracellular metabolism to be active vs. HIV.
4. **PIs inhibit the cleavage of gag and gag-pol polyprotein precursors preventing virion maturation during assembly and release.**
5. PIs are excreted by the body unchanged.

A television news announcer recently diagnosed with HIV infection is discussing the pros and cons of initiating antiretroviral therapy. The CD4+ T cell count is 375/mm³, and the HIV-1 RNA level is 42,000 copies/ml. Which of the following contributes to the rationale for not starting antiretroviral therapy in all HIV infected patients regardless of their CD4 cell counts or viral load?

1. **The potential metabolic complications of therapy.**
2. Antiretrovirals are only effective when the CD4 cell count is less than 200/mm³.
3. The immune system is completely reconstituted no matter when antiretroviral therapy is started.
4. Resistance to the medications develops rapidly even if the medications are taken correctly .
5. Antiretroviral regimens involve multiple pills taken multiple times per day, and most patients cannot adhere to the regimens.

A 50-year old man develops fever, headache, change in mental status, difficulty speaking and focal seizures. An MRI scan shows an abnormality in the left temporal lobe and a CSF PCR is positive for a DNA virus. Which of the following describes the mechanism of action of the drug used to treat this patient?

1. Inhibits viral neuraminidase from cleaving sialic acid residues attached to glycoproteins and glycolipids.
2. **Selectively phosphorylated by a viral thymidine kinase as the first step in being triphosphorylated, and then acts as a competitive inhibitor of viral DNA polymerase.**
3. Prevents cleavage of gag and gag-pol polyproteins by the protease enzyme.
4. Inhibits beta (1,3)-D-glucan synthase that is involved in cell wall assembly.
5. Inhibits ergosterol synthesis.

Team Leader Board

Which of the following statements concerning resistance to antiviral agents is true?

1. Influenza A virus cannot develop resistance to amantadine.
2. Resistance to HIV protease inhibitors occurs to a very limited extent because the target protein, the HIV protease, is only 99 amino acids in length and mutations prevent it from functioning.
3. **HSV resistance to acyclovir is most commonly associated with alteration or deficiency of the viral thymidine kinase.**
4. Viral resistance to interferon-alpha does not develop because it is a cytokine.
5. Influenza B virus is intrinsically resistant to amantadine (uncoating inhibitor) and oseltamivir (neuraminidase inhibitor).

A 32-year old woman, who lived in England until a couple of years ago and loves beef, develops a neurological syndrome involving psychosis which then progresses to dementia and death. Which one of the following statements concerning this illness is true?

1. Brain biopsy would show a marked inflammatory response.
2. If she had cooked her hamburgers more thoroughly she would not have acquired this etiologic agent.
3. Large outbreaks of this illness have occurred in the U.S.
4. **The disease is caused by accumulation of an altered form of one of her own endogenous proteins.**
5. The etiologic agent was transmitted by a dog bite.

Which of the following correctly matches a first-line agent for the treatment of tuberculosis with one of its prominent side effects?

1. Isoniazid – discoloration of bodily fluids
2. Rifampin -- neuropathy
- 3. Ethambutol – optic neuritis**
4. Pyrazinamide – vestibular toxicity
5. Streptomycin – marked drug-drug interactions

A 45-year old investment banker is happy to be recovering from a rhinoviral cold which had seriously interfered with his ability to work, but he is still experiencing a dry cough. Which of the following statements about his illness is true?

1. He should have listened to his mother who advised him to wear a hat and scarf on his way to work.
2. Anybody who worked on his floor was likely exposed because this virus spreads by aerosolized droplets which can travel fairly long distances.
3. The virus uses the CCR5 receptor for cellular entry.
- 4. His immune system's response to the virus was largely responsible for his symptoms.**
5. He needs antibiotics for what is probably now a bacterial bronchitis.

A 23-year old woman recovering from a bone marrow transplant for leukemia who has profound neutropenia and recently received a long course of steroids, now develops fever, chest pain with inspiration, a dense pulmonary infiltrate, and then dies of a massive stroke. Which of the following is most likely to be responsible for this process?

- 1. *Aspergillus fumigatus***
2. *Candida albicans*
3. *Histoplasma capsulatum*
4. *Mycobacterium tuberculosis*
5. *Cryptococcus neoformans*

Team Leader Board

Which of the following is correct concerning the nucleotide analog reverse transcriptase inhibitor, tenofovir disoproxil fumarate?

1. Tenofovir binds to a different region of the HIV-1 reverse transcriptase than nucleoside analogs
2. Tenofovir needs to be triphosphorylated in the cell in order to be active against HIV
3. Because of its formulation, tenofovir cannot be combined with other antiretroviral agents in the same tablet
- 4. Tenofovir is also active against hepatitis B virus**
5. Tenofovir is a major cause of lactic acidosis through inhibition of mitochondrial DNA polymerase gamma

A 56 year old man is brought by his wife to the emergency room with fever, cough and yellow sputum production. He had just recovered 3 days previously from a "flu-like" illness but now had "relapsed". A chest x-ray reveals a left lower lobe infiltrate. Which of the following statements is correct?

1. Antibiotics are not needed because this likely represents primary influenza (viral) pneumonia
2. Amantadine should be immediately prescribed
- 3. Bacterial superinfection is highly probable**
4. Oseltamivir has been proven to decrease mortality in this situation
5. A rapid influenza antigen test is not worth doing given the number of days that have passed

Which of the following is true concerning tuberculosis when it occurs in the setting of HIV infection?

1. Tuberculosis only occurs in patients with CD4 cell counts $<200/\text{mm}^3$
2. Upper lobe infiltrates are the most common chest x-ray manifestation of tuberculosis in this setting
3. Blood cultures for *M. tuberculosis* are an efficient way to make the diagnosis in co-infected patients
4. Antiretroviral therapy and anti-tuberculous therapy are always started together in patients who are not on anti-HIV treatment when their TB is diagnosed
5. **Worldwide, tuberculosis is the #1 opportunistic infection in HIV infected persons**

Which of the following statements is correct concerning patients who present with an acute infectious mononucleosis-like picture [fever, sore throat, fatigue, adenopathy, rash, splenomegaly with atypical lymphocytes and elevated liver enzymes (AST and ALT)]?

1. The absence of atypical lymphocytes excludes the diagnosis of mono
2. A negative monospot test rules out EBV-associated mono
3. **The differential diagnosis may include EBV, CMV, HIV, toxo, HAV, HBV and HCV**
4. Antibody tests are useless in the diagnosis of mono-like syndromes because patients are usually present in the "window" period before antibody conversion
5. Infectious mononucleosis is never fatal

Team Leader Board