

Case Discussions

2006

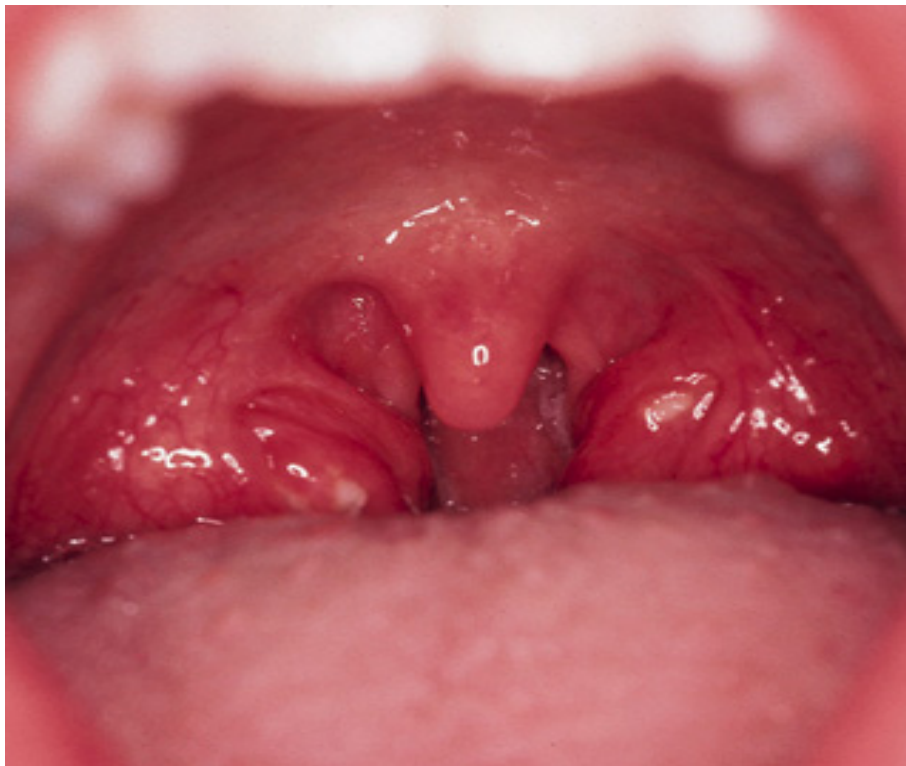Session 1: Bacteria I

1) Joey's sore throat

Joey G., a sullen 14-year old boy, is dragged to your office by his mother in February. Joey is complaining about a sore throat and fever. His symptoms began two days ago and have gotten progressively worse to the point where he finally agreed to come to your office. His mother tells you that his five-year old sister had similar symptoms last week but didn't get this sick. On further questioning Joey states that he has had chills, headaches and throat pain when he swallows food.

On physical examination he appears ill, has a temperature of 101°. He has enlarged, anterior cervical lymph nodes. His throat is red and injected and he has white pustules on his tonsils (slide #1) The remainder of his exam is unremarkable with no rash, clear lungs, a normal cardiac exam and no evidence of an enlarged spleen.

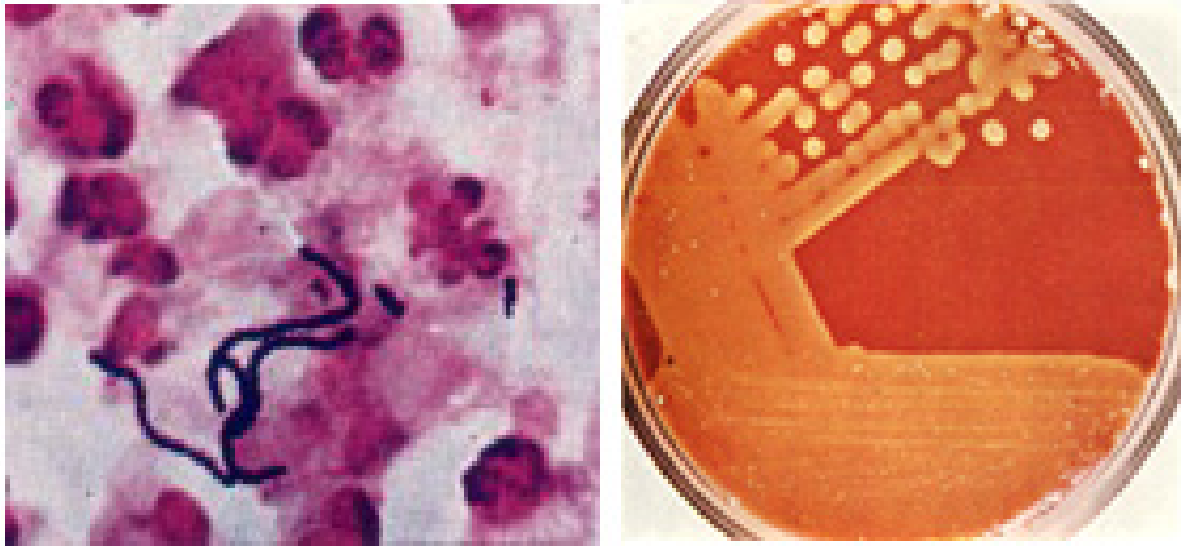
Slide #1: Joey's sore throat



1. What is your differential diagnosis?
2. How would you proceed from here? What are your options for confirming the diagnosis?

Slide #2 shows the results of Joey's throat culture. (The Gram stain on the left will help you in your identification of the organism)

Slide #2: Joey's throat culture and Gram stain



3. What is the rationale for treating this infection?
4. How is this infection spread?
5. What bacterial determinants are involved in the pathogenesis of these infections?

Two weeks after you institute therapy for his infection, Joey returns with his mother with new complaints. He has now developed recurrent fever, joint aches and pains and he has also noticed some swelling of his joints. When you examine him you notice that he now has a soft systolic heart murmur heard best at the apex (suggesting mitral insufficiency). His left knee and right wrist are warm, swollen and tender. His mother mentions parenthetically that she's had the devil of a time getting Joey to take his medication and he probably took only a third of his pills.

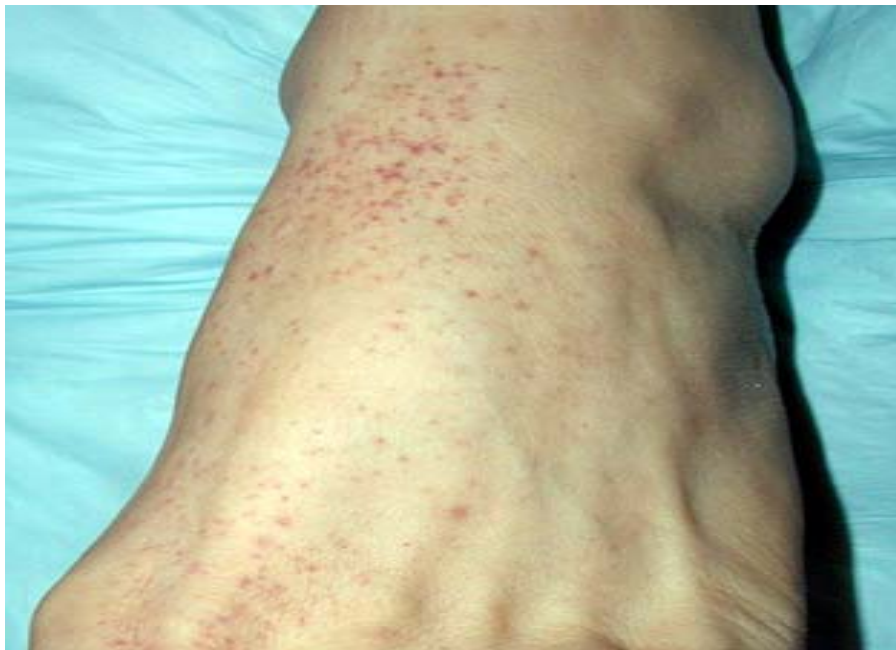6. What's going on? Why?
7. How will you diagnose this new process?
8. Do you have any recommendations for the future for Joey's management?

2) **George W. the construction worker looks awfully sick!**

A 33-year old construction worker, George W., has a history of intermittent injection drug use. He last injected heroin intravenously 2-3 days ago. He presents to the Columbia emergency room appearing acutely ill. He is complaining of a cough productive of bloody sputum, pain with deep breathing, and severe lower back pain. Until this presentation he has been in good health. Despite his frequent drug use he has had no drug related complications (until now).

On physical examination his temperature is 103° and his pulse is 124. He is an ill appearing male. He has petechiae (a hemorrhagic rash indicative of low platelets or overwhelming infection, see slide #3) on his arms and legs and some brown macular (flat) lesions on his left palm.

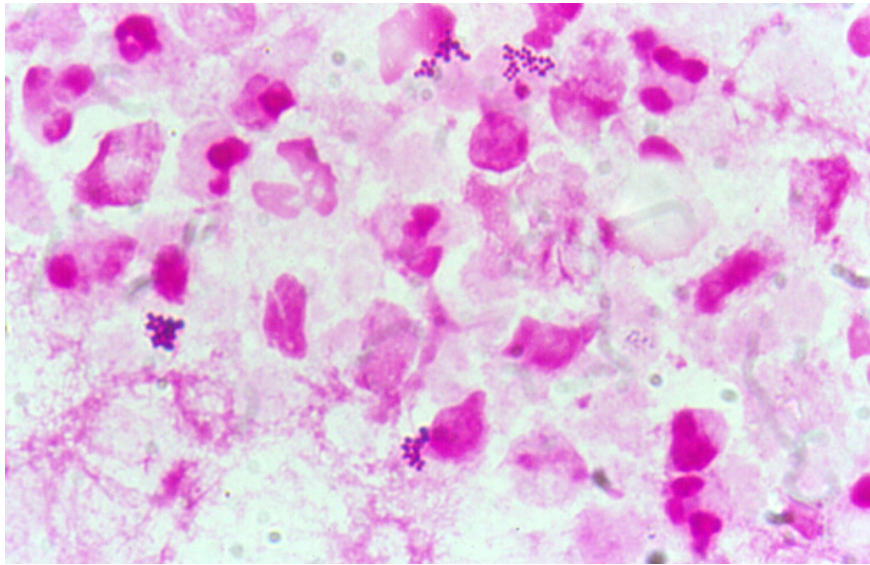
Slide #3: George W.'s rash



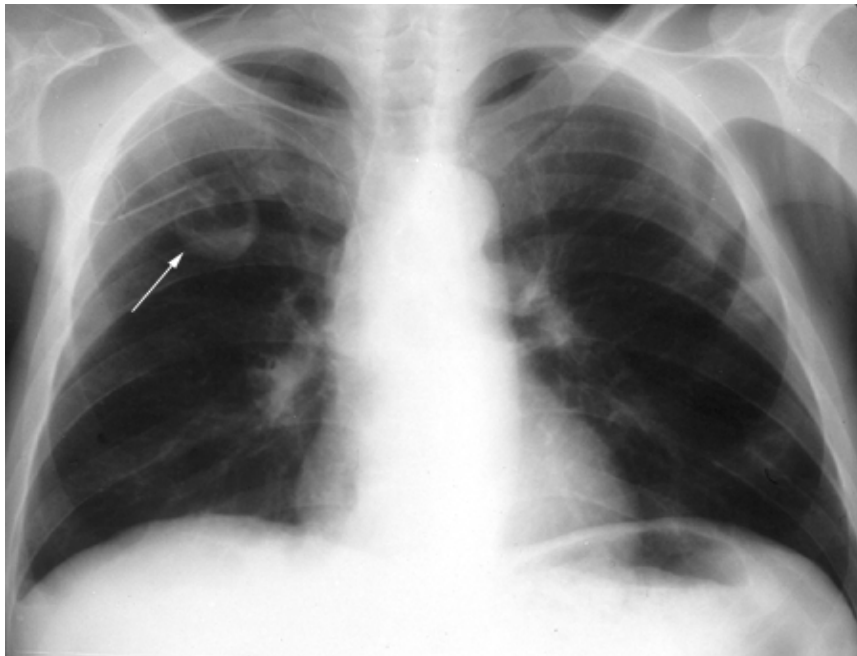
His left forearm has a small abscess at the site of his last drug injection that has a small amount of purulent drainage (pus). His lungs are clear. His cardiac exam except for his tachycardia is normal. His liver and spleen are not enlarged.

You order some lab tests and learn the following: White blood cell (WBC) count 21,000 (high) with a marked left shift (suggestive of an infection). His erythrocyte sedimentation rate (ESR) is 95 (an indication of nonspecific inflammation). His urine contains numerous red blood cells. Blood cultures are pending. A sputum Gram stain and chest x-ray are shown in slides #4 and 5, respectively.

Slide #4: George W.'s sputum Gram stain



Slide #5: George W.'s chest xray

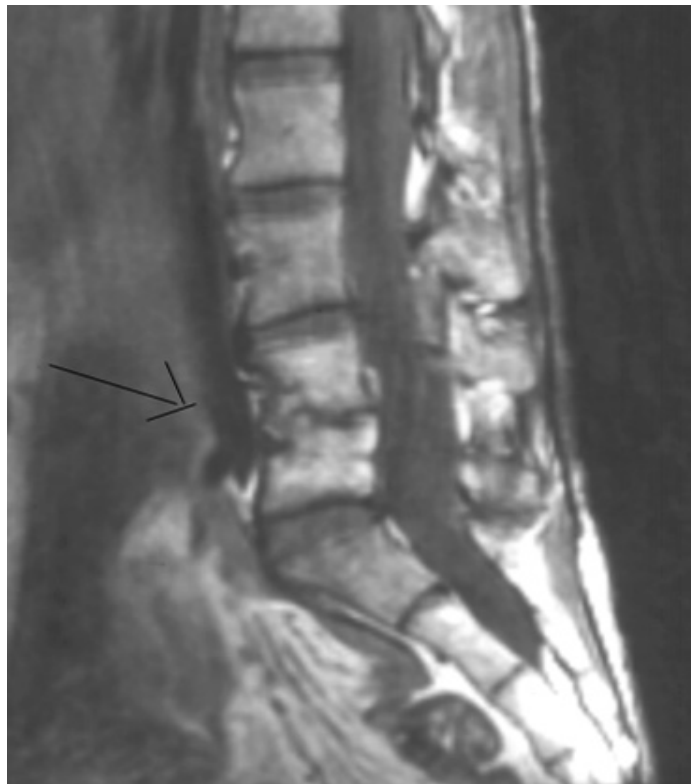

1. What is your differential diagnosis? Be prepared to provide a rationale for your choices.
2. What are the likely pathogens responsible for this infection?
3. Blood cultures grow Gram positive cocci in clusters. What is the likely pathogen?
4. How does the pathogenesis of the likely diagnosis correlate with the clinical findings?
5. How would you proceed from here? What criteria can you use to establish a diagnosis?
6. Are there additional studies that you feel are indicated? Why?

The patient slowly begins to improve on the antibiotics that you have selected as a part of his therapy. However he is still complaining of pain in his back. On closer examination you note that he appears to have developed a left foot drop (a dragging foot indicative of nerve damage).

7. What do you think is going on and how would you proceed?
8. The diagnostic test shown in slide #6 is performed. Discuss the pathogenesis of this process.

Slide #6: George W.'s spine MRI



The patient recovers after several weeks of therapy.

9. Are there other routine medical measures that you should have performed while he was hospitalized?

Session 2: Bacteria II

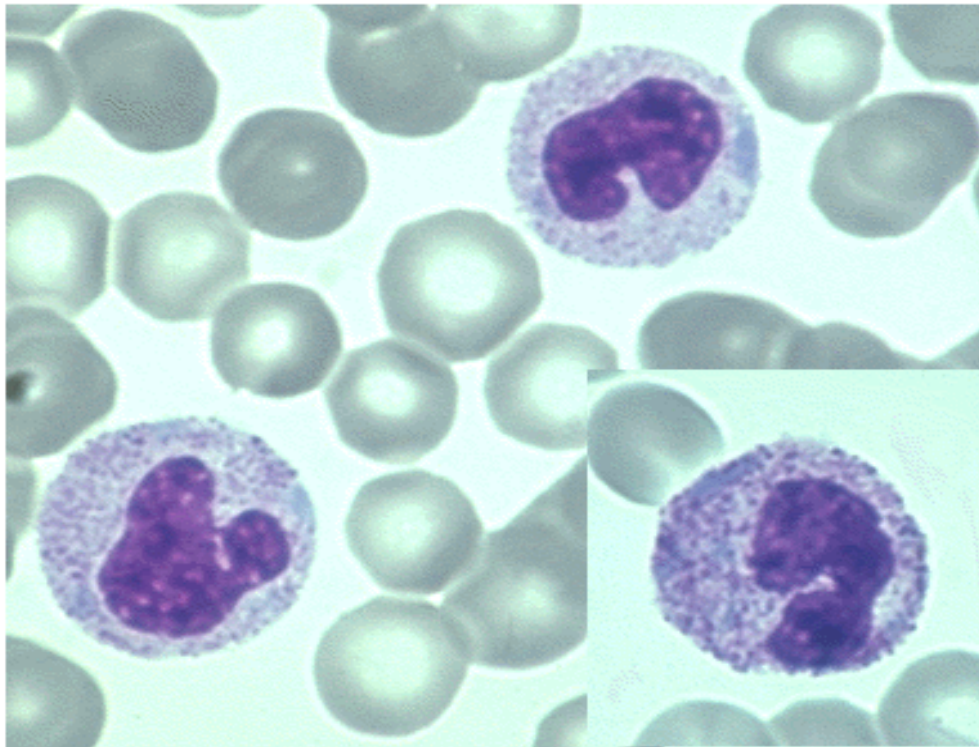
1) Sharon B. – an unhappy 10 year old

Sharon B., a ten-year old girl, is brought to the emergency room by her mother. Sharon has been in excellent health with no prior hospitalizations. She began complaining of crampy, lower abdominal pain about three days ago. Her appetite decreased and she had some nausea. Over the next two days the pain worsened and was associated with increased nausea and vomiting. She describes the pain as around her belly button and in the last day in the lower right part of her belly. In the past 24 hours her mother has noticed that Sharon has had a fever and chills. Sharon states that she has had four or five watery stools in the past two days.

On physical examination you note an uncomfortable child with a temperature of 103°. She appears acutely ill and, on examination of her abdomen, you find right lower quadrant tenderness with some rebound (pain when you release your hand usually indicative of peritonitis). Her bowel sounds are diminished and she also has some involuntary guarding (muscular contraction protecting a painful area).

Laboratory studies are of note for the following: WBC count 15,000 (high) with a marked left shift and toxic granulations observed on peripheral smear (slide #7) -- these findings are quite suggestive of infection.

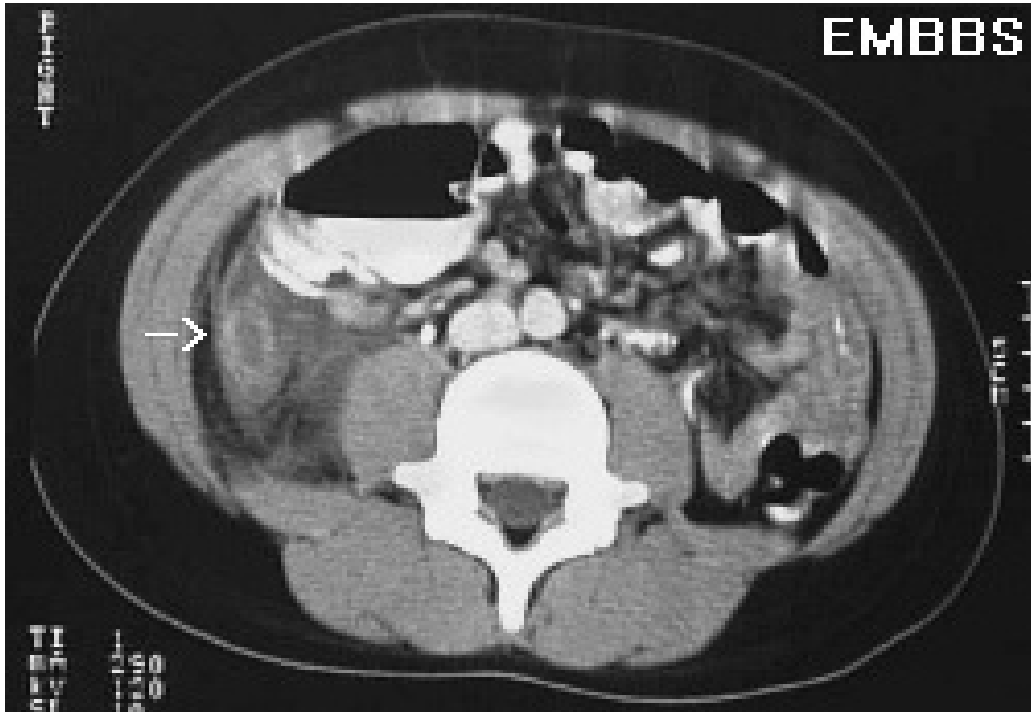
Slide #7: Sharon B.'s smear



1. What is the differential diagnosis for this presentation?
2. Are there additional studies that you would consider ordering?
3. What is the pathogenesis of this infection?

Based on the results of the additional studies that you decided to order (slide #8 shows abdominal CT scan results), the patient is promptly taken to the operating room and undergoes an exploratory laparotomy.

Slide #8: Sharon's abdominal CT scan



At surgery a perforated appendix is found with an abscess. The appendix is excised and the abscess drained and debrided. Following surgery the patient rapidly defervesces (becomes afebrile) and clinically improves.

4. What are the likely pathogens and what unique virulence determinants are responsible for their ability to cause abscesses?

2) Sally C. and her recurrent urinary tract infections

Sally C., a 28-year old female with insulin-dependent diabetes who is new to your practice, presents with a 3-day history of dysuria and increased urinary frequency. She denies fever, chills, abdominal pain, back pain, or vaginal discharge. She is sexually active and reports that she always uses condoms. She reports that she has recurrent urinary tract infections – approximately 4/year – and this feels just like the rest of them. In fact she simply tells you she needs Bactrim (trimethoprim/sulfamethoxazole). On examination, she is afebrile and has no costovertebral angle tenderness. Microscopic examination of the sediment of a centrifuged urine sample reveals 10-15 white blood cells per high power field and numerous bacteria. You send a urine culture and prescribe a 3-day course of Bactrim.

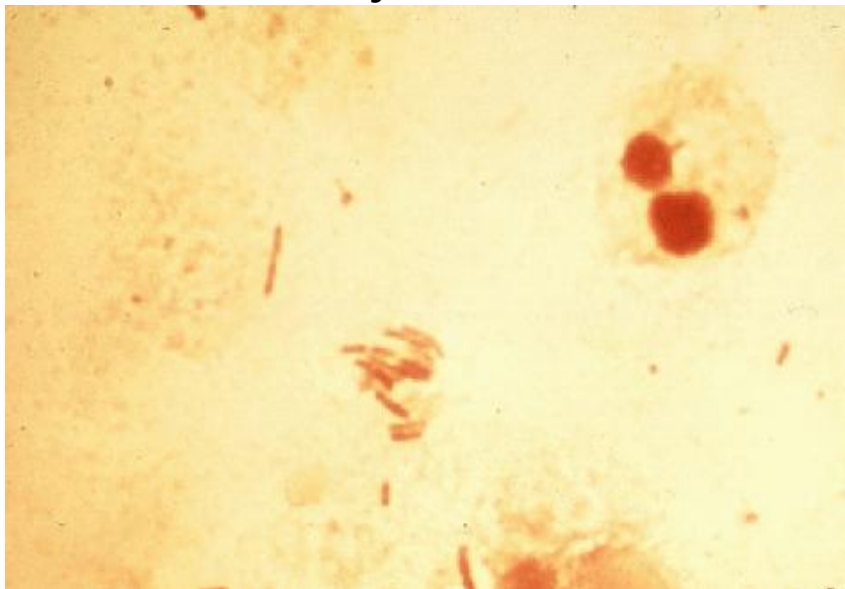
1. Why does Sally get so many UTIs?
2. What are the likely organisms responsible for her recurrent infections?

Unlike her previous episodes Sally calls from home several days later to tell you that her symptoms have not improved and she now has fever, nausea and back pain. She has generalized myalgias (muscle pains) but her back pain is especially bothersome. When she comes into your office she looks acutely ill, her temperature is 104°, she has diffuse abdominal pain and also has marked left costovertebral angle tenderness (pain right over the kidney).

3. What has happened? Why?
4. What tests would you order?

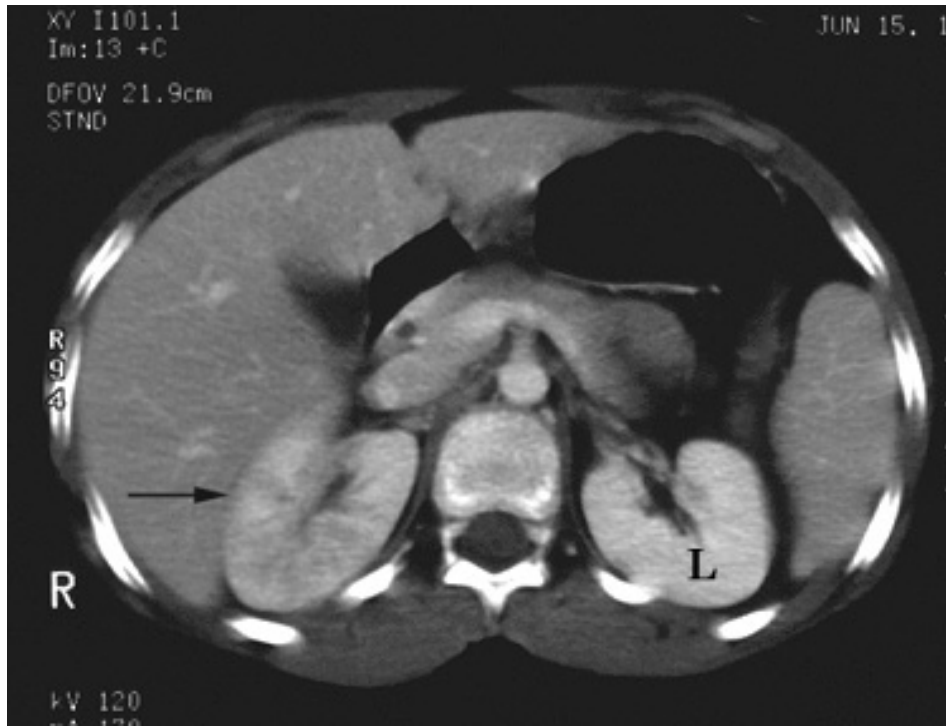You hospitalize Sally and treat her with antibiotics. Her blood and urine cultures are both growing the same organism (*E. coli*) that you cultured out initially. Slide #9 shows the urine gram stain.

Slide #9: Sally's urine Gram stain



After 72 hours of treatment she remains febrile, and you order a CT scan (slide #10).

Slide #10: Sally's abdominal CT scan (Right sided pyelonephritis)



5. What are you looking for on the CT scan?

By the next day she is feeling better, and her fever has resolved. The following day she is sent home to complete a 2-week course of antibiotics.

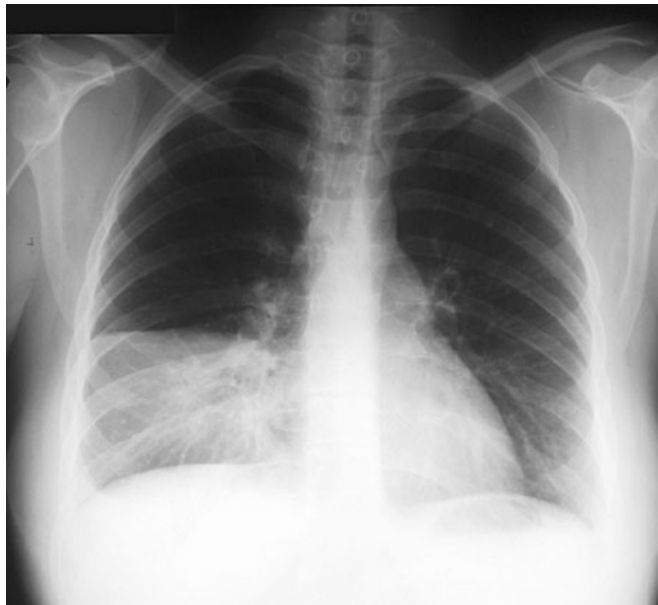3) **S.H. develops a nasty cough**

S.H., a 60-year old woman who smokes half a pack of cigarettes daily but has no other past medical history and takes no medications, develops malaise and a mild cough in mid-January. Within 24 hours, she notes the onset of severe right-sided pleuritic (pain when taking a deep breath) chest pain, a fever of 103 degrees and a teeth rattling chill. Her cough worsens and becomes productive of greenish and rusty colored sputum. She immediately calls her physician and is seen in the office that afternoon.

Physical examination reveals a blood pressure of 120/70, pulse of 96, respirations of 24 and an oral temperature of 101 degrees. There is no rash, the head and neck examinations are normal as is the cardiac exam. On lung exam, there is dullness to percussion and bronchial breath sounds over the right lower chest. The remainder of the examination is normal.

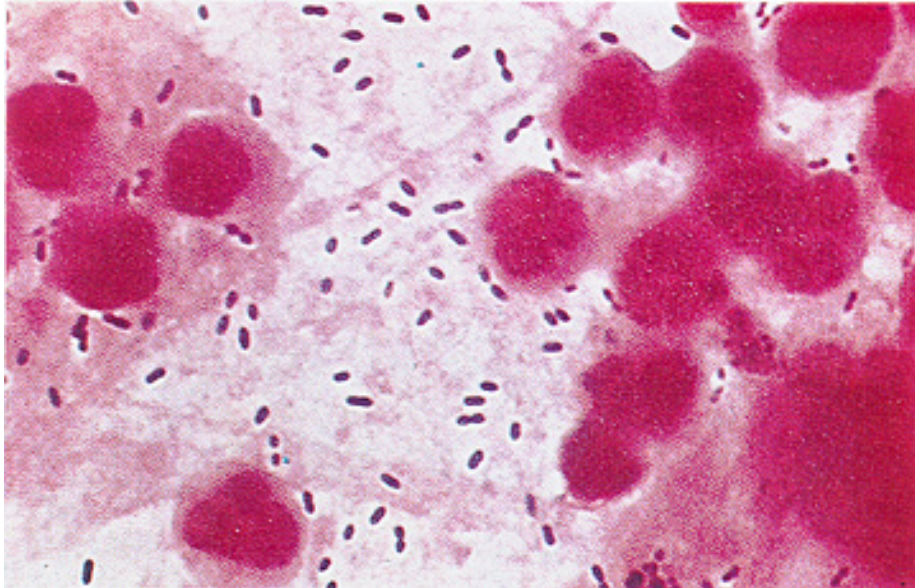
Laboratory data reveal a hemoglobin of 13.5 gm/dL (normal), a white blood cell count of 18,000 (high) with 80% PMNs, 10% bands (immature PMNs indicative of bacterial infection) and 10% lymphocytes. The electrolytes, blood urea nitrogen, creatinine and liver enzymes are normal. The chest x-ray (slide #11) shows a consolidation in the right middle lobe.

Slide #11: S.H.'s chest xray



A sputum Gram stain (slide #12) shows many PMNs and Gram positive, 'lancet'-shaped, diplococci.

Slide #12: S.H.'s sputum Gram stain



1. Are there any clues in the history as to the nature of the pulmonary infection in this patient?
2. Why is the sputum rusty colored?
3. Would you characterize this as a "typical" or "atypical" pneumonic process? Why? and how does this correlate with the pathogenesis of this process?
4. What additional tests would you order to secure the diagnosis?
5. What do you predict is the pathogen in this case?
6. Could this illness have been prevented?

Session 3: Meningitis

1) Mr. Seagram has a fit

Mr. Seagram, a 68 year old male, is perched precariously on his usual stool at Coogan's pub when he has a seizure, falls off his stool and is brought to the CPMC emergency room by several helpful medical students (we're not sure what they were doing there in the first place). The denizens of the pub assumed it was just another of Mr. Seagram's "rum fits." However, when he is assessed in the emergency room he is noted to have a temperature of 104° and appears toxic (acutely ill). His blood pressure is reduced, his pulse is 120 and his respirations are rapid and shallow. He remains obtunded (minimally responsive) after the seizure and is unable to answer questions. His neurological exam reveals no focal abnormalities.

His old chart does indeed reveal a history of alcohol withdrawal related seizures in the past. There is also a history of head trauma on several occasions related to his drinking.

1. What diagnoses should be considered?
2. How would you proceed from here?

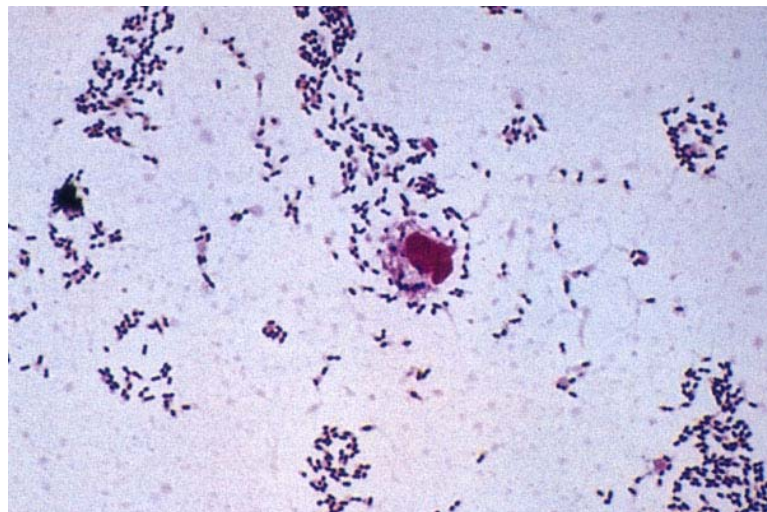
A CT scan is negative. A lumbar puncture is performed next and reveals the following:

Opening pressure – increased; CSF appearance – turbid (normal- clear). The CSF is sent to the lab for analysis.

3. What pathogens should be considered if this is meningitis?

WBC- 2,300 (normal 0-5); 95% polymorphonuclear leukocytes (PMNs) (indicative of bacterial infection); Red blood cells – 100; protein 178 (elevated); glucose 18 (very low). Gram stain is shown in slide #13.

Slide #13: Mr. Seagram's CSF Gram stain



How do these results influence your differential diagnosis?

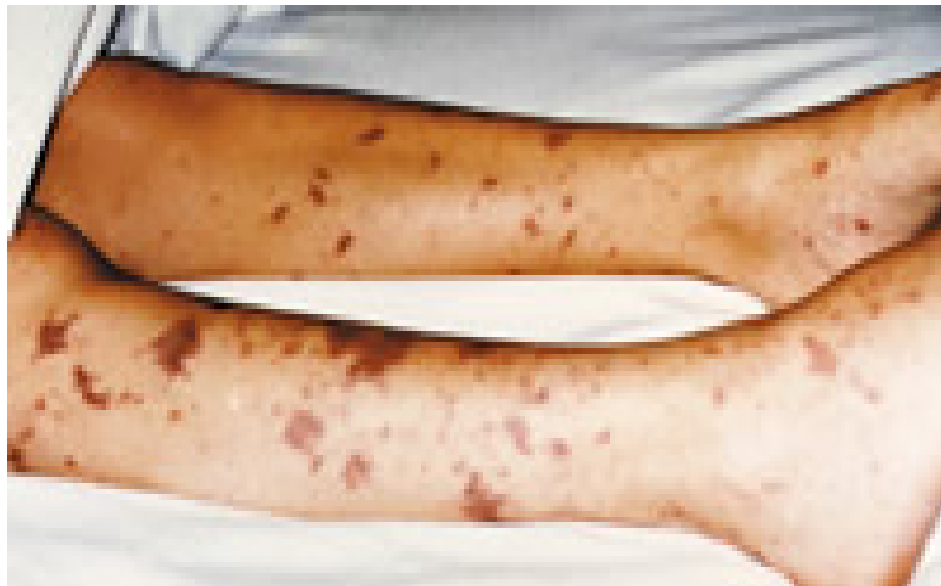5. What is the likely pathogenesis of this infection? Are there any particular risk factors that contribute to Mr. Seagram's illness?
6. What potential complications or future sequelae should be anticipated?
7. Could this illness have been prevented?

Mr. Seagram's symptoms resolve with appropriate treatment, and he is discharged home.

2) **Junior has a rash**

Junior, an 18 year-old college freshman, has, with some difficulty, made it through the first semester of college. He returns for the second semester rejoining his five fraternity suite mates. One week into the second semester he starts to feel ill. His symptoms start with a mild cough and some myalgias. He thought that this might have been due to a late night drinking and smoking (we're not sure what he smoked) binge with his buddies in the local pub. On the day of his admission he develops a low-grade fever and headache. He goes to lie down and is found several hours later by one of his roommates delirious, with shaking chills and a rash covering much of his body. He is rushed to the hospital where he is examined in the emergency room and found to have the following: Temperature 103°; BP - 80/palpable (reduced); Respirations 28 (increased), and Pulse 124. He is minimally responsive to questions and is shaking in bed. His entire body is covered with a petechial rash (pinpoint hemorrhagic lesions) with some areas where the skin rash has become confluent (slide #14).

Slide #14: Junior's rash



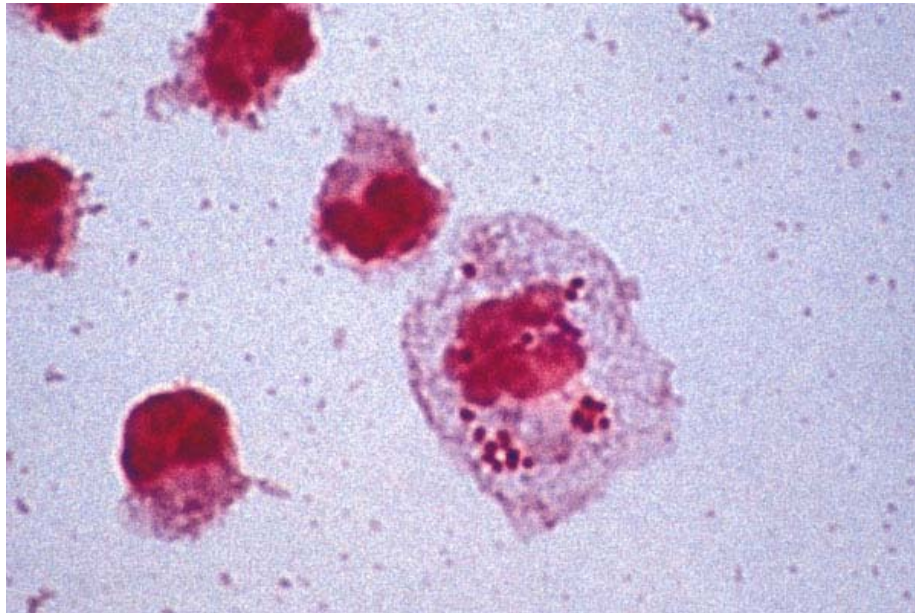
Laboratory studies reveal: White blood cell count: 19,000 (high) with a marked left shift. Platelet count 70,000 (reduced).

Lumbar puncture: Opening pressure increased; WBC 9,500 (normal 0-5); PMNs - 98% (high- suggestive of bacterial process); Gram stain pending; Protein – 130 (high); glucose – 5 (very low).

1. What are the likely causes of this process?
2. What is the pathogenesis of this process?

The Gram stain comes back and is shown in slide#15.

Slide #15: Junior's CSF Gram stain



Junior is admitted and promptly treated with appropriate antibiotics. His suitemates come to the emergency room because they have heard that Junior's infection is contagious and they want to know if they should take anything.

3. Should they? Why?
4. Would it have been possible to prevent this infection?

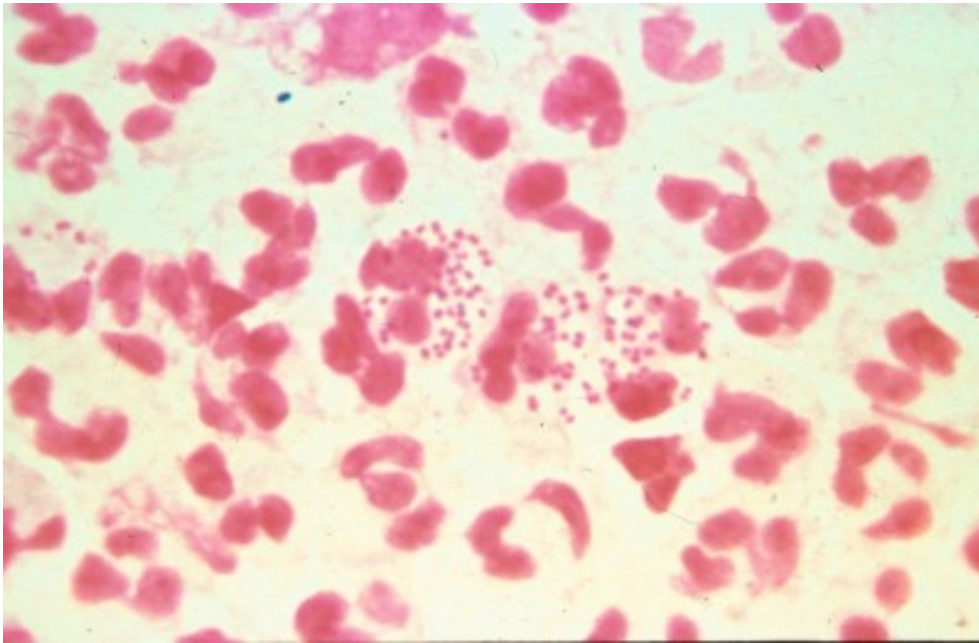
Session 4: Sexually transmitted diseases

1. A.L., age 22, has a lapse in judgment

After college, R.A. is slaving away at medical school while her ex-boyfriend has been traveling the world. One day R.A. gets a worried email from A.L. who is on a tropical island in the South Pacific—"I think I have a urinary tract infection. It hurts when I pee and I have pus on my shorts. What should I do?" R.A., being an astute medical student, knows there's more to that story and she isn't happy. Nonetheless, she decides it is her duty as an aspiring physician to help her ex. She inquires back—"Who did you have unprotected sex with recently?" A.L. admits his indiscretion—"Well, there was this Australian woman last week. We didn't exactly use a condom." R.A. tells A.L. that he probably has a sexually transmitted disease and he should see a doctor.

A.L. follows R.A.'s advice and seeks treatment. He can only manage to find a shady doctor who tells him he has "the clap" based on what he saw under the microscope (see slide#16) and gives him a big shot. A.L. says it was ceftri-something (a beta-lactam antibiotic as it turns out) and thanks R.A. for being so understanding.

Slide #16: A.L.'s Gram stain (penile discharge)



1. What is the likely diagnosis of A.L.'s symptoms? Is a Gram stain a good way to make the diagnosis in this case? What other options are available to make the diagnosis? If you wanted to culture the organism, what media and growth conditions would you use?
2. What is the pathogenesis of this infection and how is it transmitted?
3. Was he given appropriate therapy? Why or why not?

However, one week later A.L. writes R.A. and is still complaining of scant penile discharge and dysuria (painful urination).

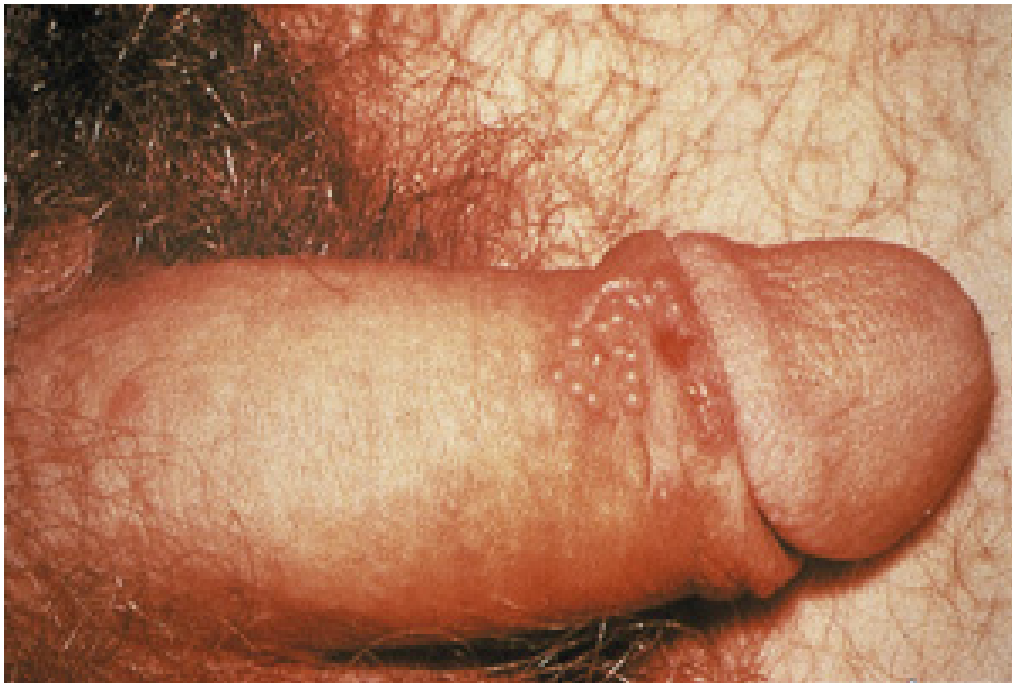4. What is the most likely diagnosis? How would you confirm this?
5. When did he most likely acquire this infection? Should anything have been done at his first visit to prevent this presentation? Why was this organism not seen on routine bacterial culture?
6. Describe the life-cycle of this organism.
7. What are the major complications of this infection in men? Women? Perinatally infected infants?
8. When A.L. returns to the U.S. and you become his physician, what other tests would you recommend, if any?

2) Arrowsmith's Ulcers

Arrowsmith, a previously healthy 19 year old male college student, notices the onset of fever to 100.5°F, headache, chilly sensations, fatigue, anorexia and muscle aches. Within a day of these symptoms, he notices a sense of tingling and mild discomfort on the shaft of the penis. He takes some acetaminophen but feels no better and over the course of the next 1-2 days, becomes concerned about the development of a cluster of painful “bumps” on his penis. These are initially clear and appear to be fluid filled. The pain is localized, sharp and associated with tender “lumps” in the groin. His headache has worsened, and is now associated with light sensitivity and neck stiffness.

With these complaints, he visits the internist at the university health service who elicits the history that the patient has had two new female sexual partners in the past month and did not use condoms. On physical examination, an oral temperature of 100 degrees is noted; other vital signs (blood pressure, pulse, respirations) are normal. Direct light shone into the eyes causes the patient to turn away. The neck is resistant to passive motion. There are multiple 1-2 cm tender lymph nodes in the inguinal regions bilaterally. A 1-1.5 cm cluster of 1-2 mm, clear, glistening vesicles is noted on the shaft of the penis (slide #17).

Slide #17: Arrowsmith's ulcers



The remainder of the physical examination is entirely normal. A complete blood count (CBC), kidney and liver tests, and urinalysis are all normal.

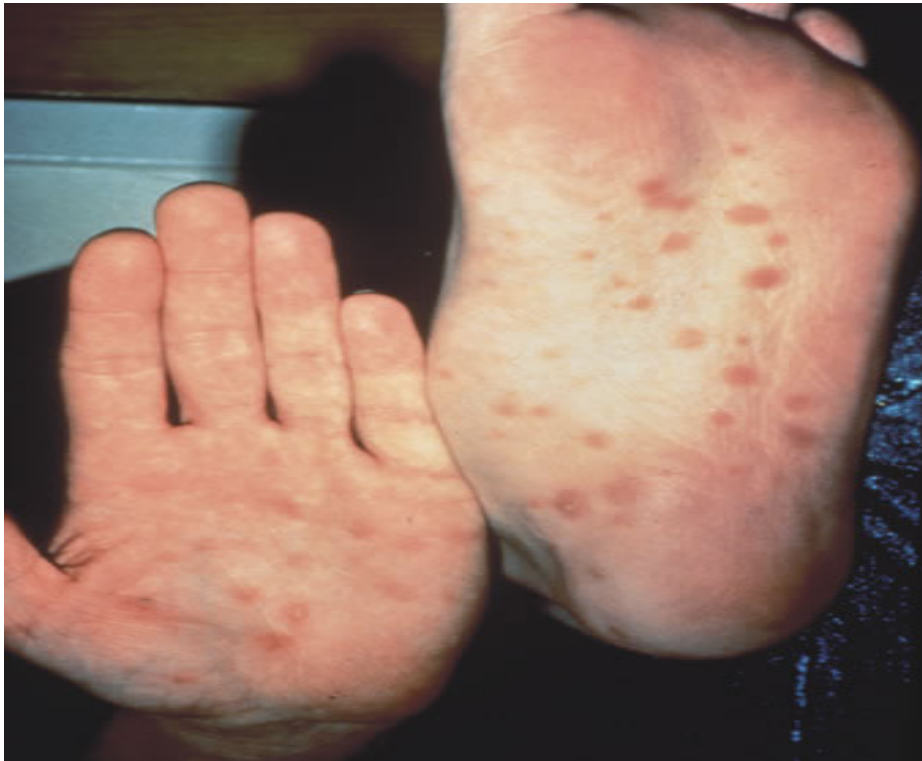1. What in Arrowsmith's history and physical examination is of significance to you in trying to make the diagnosis?
2. What is your differential diagnosis?
3. What is the significance of the photophobia and neck stiffness?
4. What additional laboratory studies would you like to see ordered?

You send a viral culture looking for what you consider to be the most likely pathogen, and it returns positive, confirming your suspicions.

5. What should you advise Arrowsmith about the possibility of recurrences of this infection?

Two months later Arrowsmith returns with low-grade fevers, malaise (tiredness), sore throat and a rash (slide#18).

Slide #18: Arrowsmith's rash



On examination his temperature is 100.4°F. His inguinal, cervical, axillary and epitrochlear lymph nodes are enlarged and he has a diffuse, erythematous (red), maculopapular (raised and flat) rash over his trunk and extremities, including his palms and soles.

6. The differential diagnosis is quite large (list some possibilities), but given his history and the current presentation, what tests would you order to establish the diagnosis?
7. What is the pathogenesis of this stage of infection? If he hadn't sought medical attention, what might have happened?
8. How would you treat him? What about his sexual partners?

Session 5: Antibiotic Case Discussion

Introduction

Discuss the following questions in class at some point during the session:

- A. Why do most bacterial infections respond to bacteriostatic antibiotics? Why do some infections require bactericidal compounds?
- B. When the microbiology laboratory indicates that an organism is "susceptible" or "resistant" to an antibiotic, what does that mean?
- C. What is meant by synergistic interaction between antimicrobials? Discuss several mechanisms of synergy.
- D. Discuss the potential advantages and disadvantages of using more than one antibiotic in the treatment of infections.

The Case

Charles D. Gold, a 72 year-old lawyer, begins to wake up three to six times per night to urinate. After a month of these symptoms he consults a urologist, who makes a diagnosis of benign prostatic hyperplasia and schedules him for a transurethral resection of the prostate (TURP).

Mr. Gold's preoperative evaluation notes that he is in good health and takes no routine medications. His medical history is notable for rheumatic fever at age 12, with no serious sequelae. On physical exam, his temperature, pulse rate, blood pressure and respiratory rate are normal. His exam is unremarkable except for a soft, pansystolic heart murmur (suggestive of mitral regurgitation) and a symmetrically enlarged prostate. Routine laboratory results are normal. A urinalysis shows 30- 40 white cells per high power field and occasional bacteria. A urine culture is sent to the laboratory.

The next day the TURP is performed uneventfully. Mr. Gold's symptoms are much improved. Ten days later, however, he begins to feel weak and unwell. He develops fevers, sweats, chills, then a cough and shortness of breath when he walks.

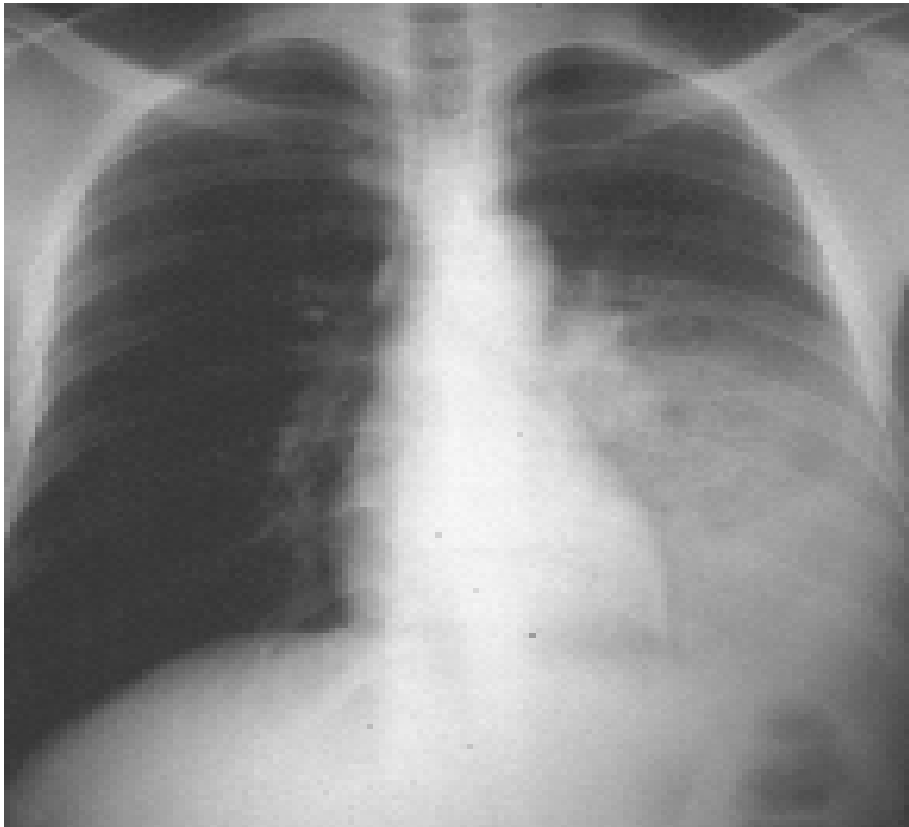
On evaluation, Mr. Gold now has a temperature of 101° and a respiratory rate of 22. There are a few petechiae on his conjunctivae. His chest exam is notable for rales in both lung fields, and his heart murmur is much louder than it was previously. Routine labs show a fall in his hematocrit and a high erythrocyte sedimentation rate. His chest X-ray shows signs of heart failure. His urinalysis shows red cells, white cells and bacteria. Both his urine and his blood cultures grow *Enterococcus faecalis*.

1. What is the differential diagnosis for Mr. Gold's illness? Justify your differential.
2. Which antibiotics will you choose to treat his infection? How will you administer them? About how long should he be treated?
3. Mrs. Gold calls you from Mr. Gold's hospital room just as the nurse is preparing to give him his first dose of antibiotics. She thinks you should know that he got a rash the last time he was given penicillin. What else do you want to know? Will this change your choice of antibiotics?
4. How do you plan to monitor Mr. Gold's response to antibiotic treatment?

Mr. Gold begins on the course of antibiotics you have selected. Within a week he has become afebrile, and subsequent blood cultures are negative. However, he continues to have difficulty breathing and his heart failure appears to be worsening. He is transferred to the medical intensive care unit where he is endotracheally intubated and placed on a mechanical ventilator. The next day a mitral valve replacement is performed.

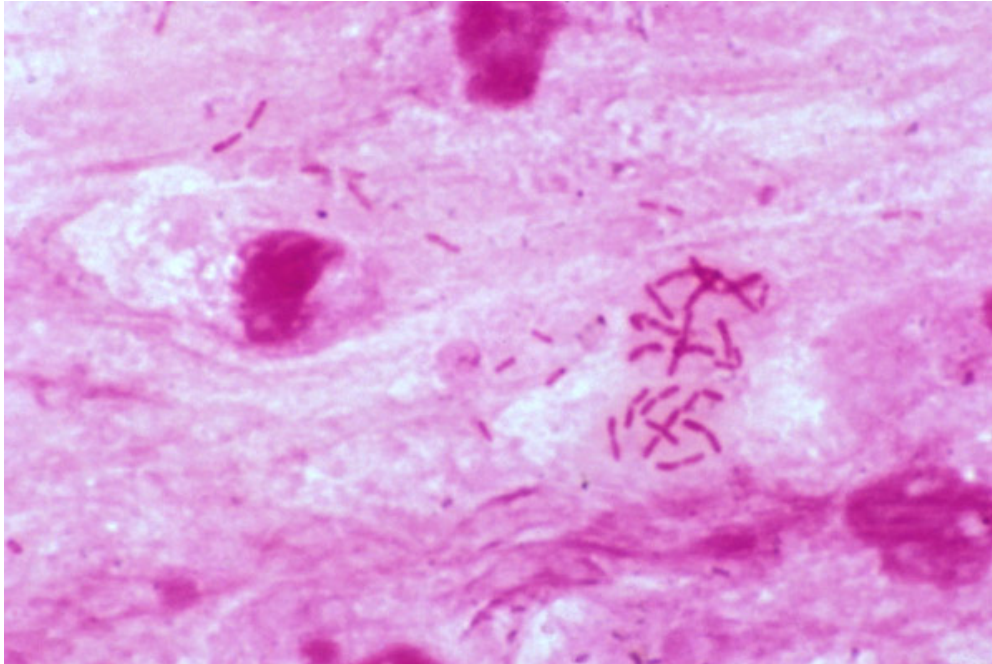
After the operation Mr. Gold's cardiac and respiratory status stabilize. Two days later, however, he develops a fever of 104°. On chest X-ray he has a new left lower lobe infiltrate (slide #19).

Slide #19: Mr. Gold's chest xray



Sputum suctioned from his endotracheal tube is purulent, and on Gram stain many white blood cells and bacteria are seen (slide#20).

Slide #20: Mr. Gold's sputum Gram stain



5. What infection does Mr. Gold have now? What organisms are likely to be involved?
6. What antibiotics can be used to treat this condition? Which would you select for Mr. Gold? How would you administer them? About how long would you treat him?

After a lengthy discussion, you elect to empirically treat Mr. Gold with a third generation cephalosporin plus an aminoglycoside. Several days after the antibiotics you have chosen are begun, Mr. Gold becomes afebrile. His sputum culture is eventually reported positive for *Enterobacter cloacae*, sensitive to the antibiotics you have chosen. Mr. Gold then does well for several days. Although he remains in the intensive care unit, he can finally be removed from the ventilator. However the next morning, he once again develops a fever of 104°. His sputum, which had become scanty, is once again copious and purulent. His chest X-ray shows an enlarging infiltrate. A sputum culture again grows enterobacter, but now the organism is resistant to the antibiotics Mr. Gold is receiving. The susceptibility report reveals the following:

Resistant: ceftriaxone, piperacillin, ceftazidime, timentin.

Sensitive: imipenem, ciprofloxacin.

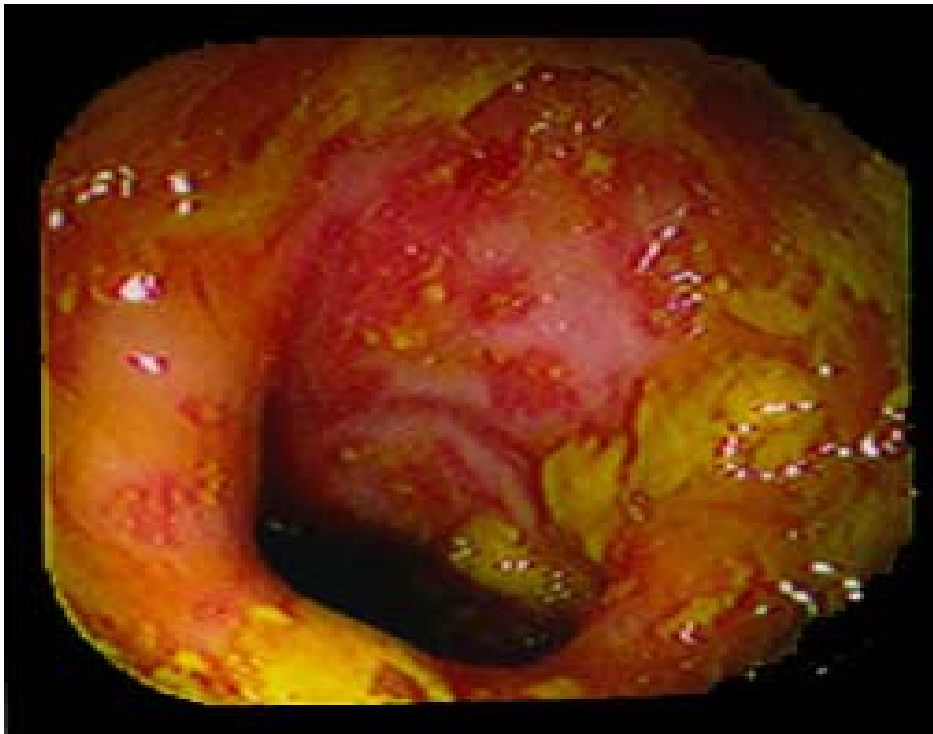7. Why has this organism become resistant? Is there any way you might have prevented resistance from developing?

8. Is this finding of clinical significance? Should you change Mr. Gold's antibiotics? To what?

Mr. Gold begins to do well on the antibiotics you have chosen. He leaves the intensive care unit. He begins to take short walks around the ward and is looking forward to going home. Suddenly, however, on the day before his discharge, he develops excruciating crampy abdominal pain, profuse diarrhea and a fever of 101°.

Mr. Gold undergoes colonoscopy (shown in slide #21).

Slide #21: Mr. Gold's colonoscopy



9. What is the differential diagnosis for Mr. Gold's new illness?

10. What is the likely pathophysiology?

11. Which antibiotics can be used to treat this condition? Which would you select for Mr. Gold? How would you administer them?

Mr. Gold does well on the antibiotics you have selected and finally leaves the hospital, eight weeks after his admission, feeling well and thanking you for all your efforts. As he heads for the elevator he mentions that one of his molars has been bothering him for weeks. He is planning to go see his dentist in the morning.

12. Do you have any parting advice for Mr. Gold? Is there any way this long hospitalization of his might have been prevented?

Session 6: Respiratory Tract Infections

1) Fever and sweats in T.J., a homeless man

T.J., a 35 year old homeless man appears in the CPMC ER looking wasted and ill. He reports that he has been having daily fevers and drenching night sweats for a month. He has had no appetite and has lost 25 pounds. In addition, he has had a worsening cough productive of yellowish sputum that is occasionally blood streaked. He denies any other symptoms.

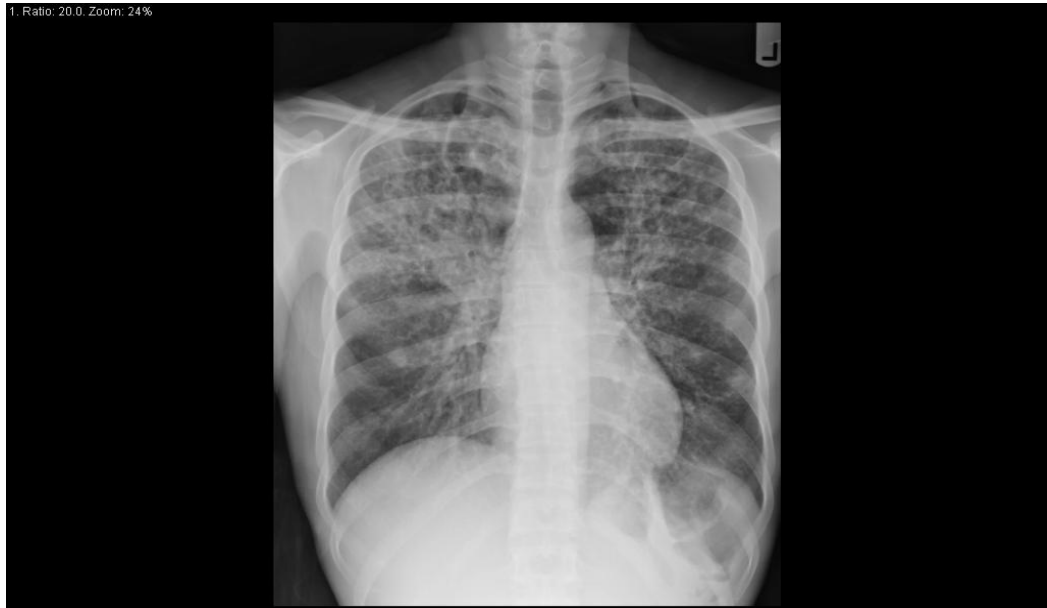He was born in the Dominican Republic and moved to the New York area 10 years ago. He does not recall whether he drank unpasteurized milk as a child. He has no other travel history. He has worked intermittently as a handyman and has spent a good part of the past three years in shelters in Manhattan. He is heterosexual and has had approximately 6 partners in the past 2 years. He smokes 1 pack of cigarettes per day and drinks approximately 2-3 bottles of Night Train per day.

Physical examination reveals a chronically ill appearing man with a blood pressure of 130/70, a pulse of 90, respiratory rate of 22 and a temperature of 101.4 degrees orally. There is temporal muscle wasting, no oral thrush (yeast infection of the mouth), poor dentition, no significant lymphadenopathy (enlarged lymph nodes), occasional rhonchi (a whistling sound indicative of some airway compromise) on lung exam, no heart murmur, a firm liver edge palpable 2 cm below the right costal margin with a span of 12 cm (indicating mild hepatic enlargement) and a palpable spleen tip (indicating a possibly enlarged spleen).

Laboratory studies show a Hgb of 10 gm/dL (low), a white blood cell count of 8,000 (normal) with 70% PMNs (slightly elevated), and 4% bands (slightly elevated). The aspartate aminotransferase (AST) is 65 and the alanine aminotransferase (ALT) 90 (both elevated). The bilirubin is normal but the alkaline phosphatase (another liver enzyme) is elevated at 190. Electrolytes, blood urea nitrogen, creatinine and blood sugar are normal.

The chest xray is shown in slide #22.

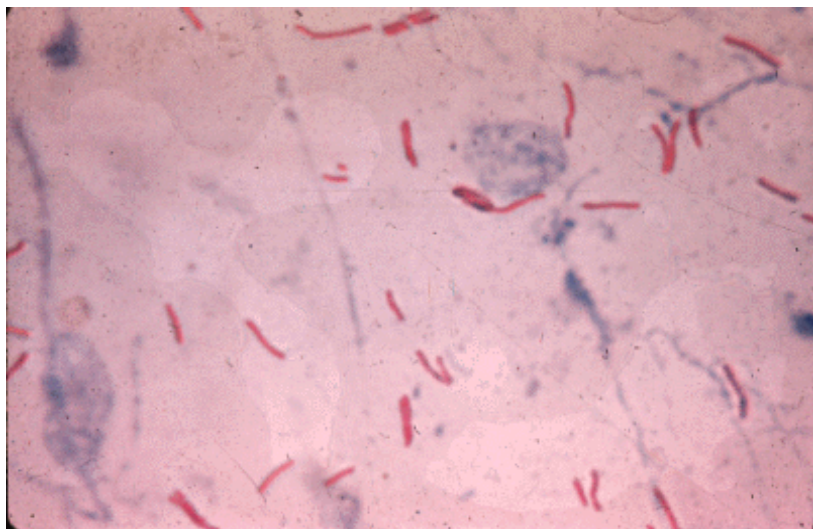
Slide #22: T.J.'s chest xray



1. Do any of the epidemiologic clues help you in your thinking of the differential diagnosis?
2. Do the cough, hemoptysis, night sweats, weight loss and chest x-ray suggest one pathogen as most likely?
3. When this patient is admitted to the hospital, would you take any infection control precautions? If so, what?
4. What are the possible causes of the elevated liver enzymes?
5. What additional laboratory tests would you request?

Results of a sputum evaluation are shown in slide #23.

Slide #23: T.J.'s sputum (acid fast stain)



6. What is the approach to treatment of the most likely pathogen?

2) **Jane feels lousy**

Jane H., a 75-year-old woman, wakes up on New Year's Day feeling lousy, with total body aches, a splitting headache, and a fever to 102. Over the next two days she develops a sore throat and dry cough. On the fourth day of her illness, she starts to feel a bit better but her husband persuades her to visit her doctor, you. Jane has no chronic medical problems except osteoarthritis, and she takes no medications. Her physical examination reveals a temperature of 100.8 degrees, blood pressure 126/84, pulse 102, respiratory rate 12, palatal erythema but no exudate, and mildly enlarged cervical lymph nodes bilaterally. Her heart and lung exams are within normal limits.

- 1) What is the differential diagnosis of Jane's illness?

You suspect influenza, but Jane says that could not be possible because she received the flu shot 2 years ago. She has not received it since, because she was convinced she got the flu last time she received the vaccination. You confirm your suspicion with a rapid test for influenza on a nasopharyngeal swab. Because the illness has been going on for four days, you decide not to treat Jane with antivirals, but prescribe acetaminophen and plenty of rest.

- 2) What is the pathogenesis of Jane's illness?
- 3) Why did Jane get the flu even though she received the flu shot 2 years ago?
- 4) Why did you choose not to treat her with antivirals?
- 5) What recommendations, if any, should you make for Jane's 78-year-old husband with rheumatic heart disease and mitral stenosis?
- 6) What should you tell Jane about influenza immunization?

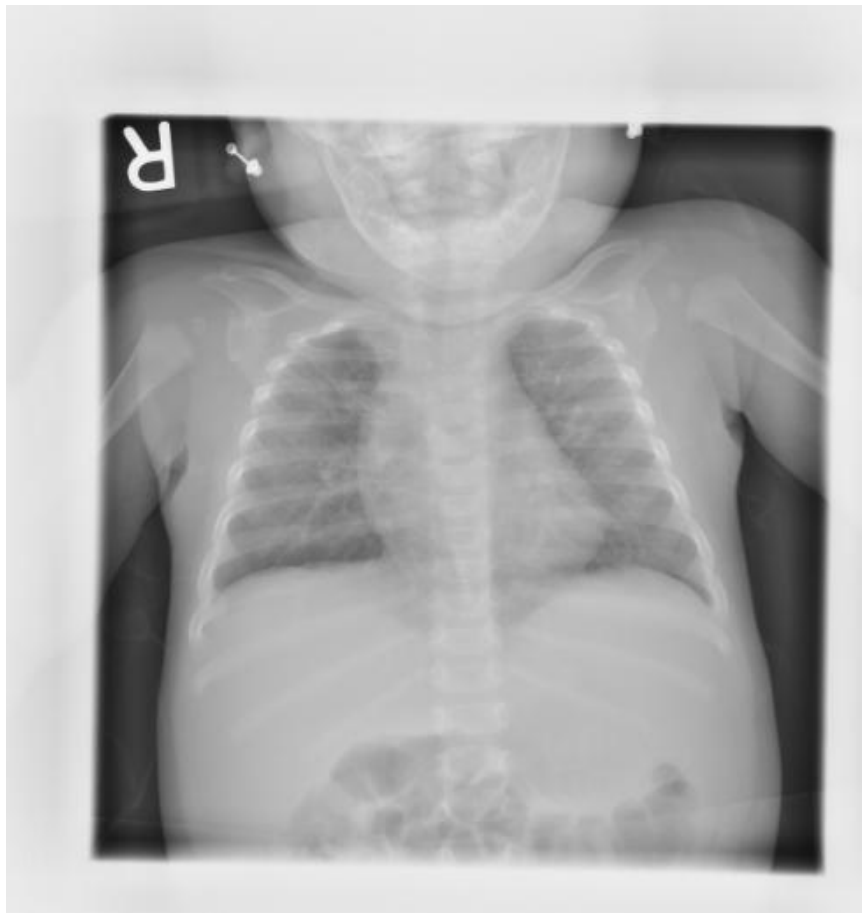Jane returns three days later feeling worse, with high fevers again, chills, a cough productive of greenish sputum, and shortness of breath.

- 7) What do you think has happened, and what are the most likely pathogens? What should you do now?

3) **R.J. appears to have more than just a cold**

R.J., a 4-month-old infant, is brought to the emergency room in late February because of cough, wheezing and difficulty breathing. The baby was well until a few days before presentation when he was noted to have some nasal congestion and a fever. A mild cough was present and over the past 2 days this has deepened and become more severe. On the day of his presentation his respiratory rate increased and his parents noticed that his chest seemed to be collapsing when he inhaled. R.J. was the full-term product of a normal pregnancy. He had no serious illnesses and all his vaccinations were up to date. On examination the baby appears ill and in respiratory distress. Intercostal retractions are noted. His temperature is 101°F. Ear exam shows normal tympanic membranes and his pharynx is clear. Lung exam shows crackles and wheezing diffusely through his lung fields. Cardiac, abdominal and neurological exams are normal. An oxygen saturation monitor reads 87% (normal above 95%). A chest X-ray shows multiple areas of interstitial infiltration and hyperinflation of the lungs (slide #24).

Slide #24: R.J.'s chest xray



R.J. is admitted to the hospital and given supplemental oxygen and IV fluids. He improves over the next 2 days and is discharged.

1. What is the differential diagnosis of bronchiolitis in an infant? What is the most likely diagnosis in this case?
2. How would you make the diagnosis?
3. If R.J. had underlying cardiac or pulmonary disease or were more severely ill, what else could have been used in his treatment?
4. Is a vaccine available to prevent this infection? Is anything else available and in which populations should it be used?

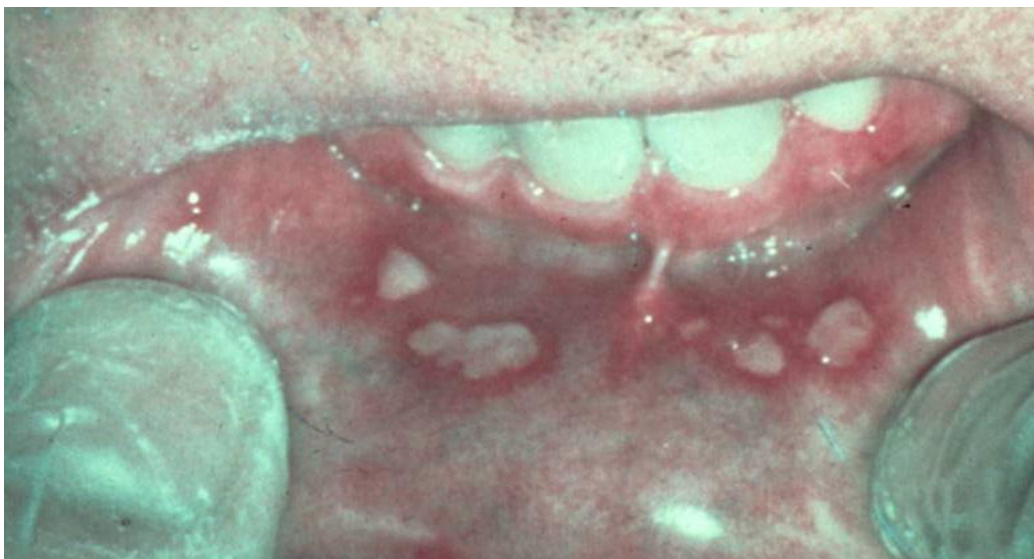
Session 7: HIV Infections

1) Janet J. has a rash and swollen glands

Janet J., a 20 year old college junior, returns from a vacation in San Diego and two weeks later develops fever, malaise, headache, mild neck stiffness, sore throat, “swollen glands” and a non-pruritic (not itchy) rash. She went kayaking, camping and also had unprotected sex with a new male partner during the trip. Her previous health was excellent and she takes no medications.

Physical examination in her physician’s office reveals a temperature of 101°F, a maculopapular rash on the torso, oral ulcers (see slide #25), mild neck stiffness, and enlarged cervical lymph nodes.

Slide #25: Janet’s oral exam



Hemoglobin 13.5 gm/dL, WBC 3,100 (mildly low) with 66% PMNs, 35% lymphocytes, 9% atypical lymphocytes, aspartic aminotransferase (AST) 47, alanine aminotransferase (ALT) 50. The AST and ALT, measures of liver enzyme function, are both mildly elevated. Electrolytes, blood urea nitrogen, creatinine, blood glucose and urinalysis are normal. A lumbar puncture is performed and reveals the following: 30 WBC’s (99% lymphocytes) (too many cells), protein 50 mg/dL (mildly elevated), glucose normal. A Gram stain of the cerebrospinal fluid (CSF) is negative.

1. What is your differential diagnosis?
2. Does the presence of the neck stiffness and the CSF profile help you? What do these abnormalities indicate?
3. How would you approach trying to pin down the diagnosis?

A diagnosis of acute HIV infection is made. (Specific test results will be provided.)

4. Why is it important, in terms of personal benefit and public health, to make this diagnosis?

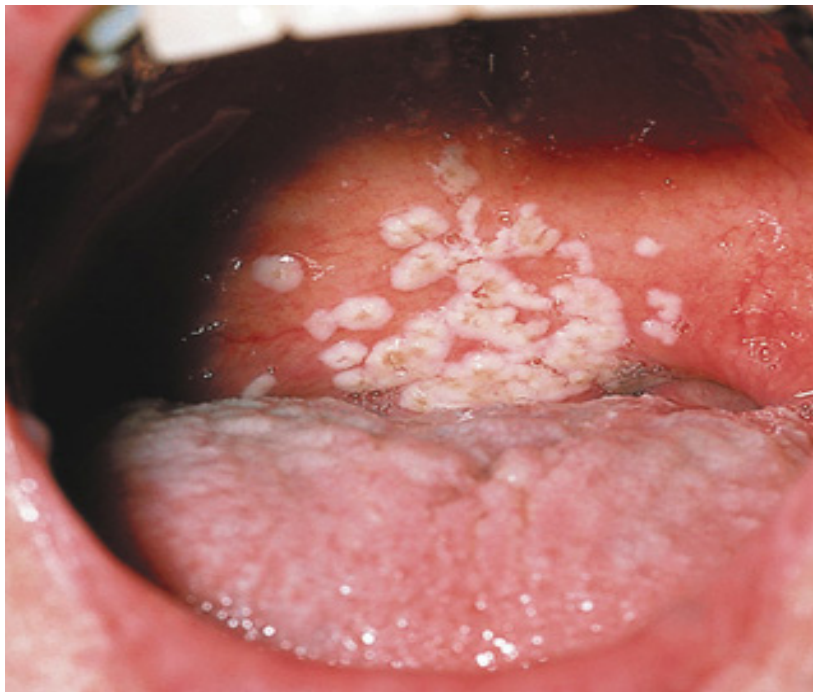2) **Fever and cough in a woman from the Dominican Republic**

Gloria R., a previously healthy 28-year old woman who emigrated from the Dominican Republic three years ago, appears in her local physician's office with low grade fevers and a mild dry cough of one week's duration. The physician hears some "noise in her chest" and prescribes a five day course of azithromycin. She initially feels somewhat better but the symptoms never entirely resolve. Over the next two weeks, she develops recurrent fevers to 101-102 degrees, fatigue, anorexia, worsening dry cough and shortness of breath with exertion. She feels like she "can't take a deep breath". She reports a mild headache when her temperature is up but she denies photophobia or neck stiffness. She has had no nausea or vomiting but has had some modest diarrhea. On questioning she reveals that she has lost 15 pounds in the past six months and hasn't "been feeling herself".

She has been married for 8 years and has been monogamous. There are two children at home who have been well.

Physical examination reveals a fatigued appearing woman who gets short of breath with mild exertion. Blood pressure 100/60, pulse 110, respirations 30, temperature 101.5°F degrees orally. The pharynx reveals whitish plaques on the tongue and buccal mucosa (slide #26) and linear, vertical, white streaks on the sides of the tongue.

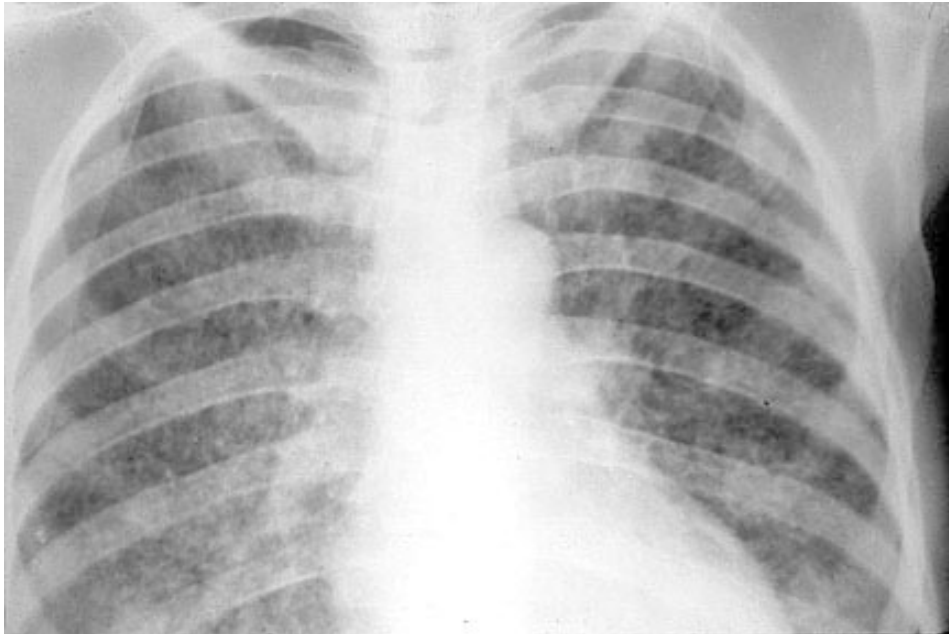
Slide #26: Gloria's oropharynx



Cervical, axillary and inguinal lymph nodes are palpable but mostly <1 cm in diameter. The neck is supple. Lungs are clear to auscultation and percussion. Cardiac, abdominal, extremity and neurologic exams are normal. She has a 1.5 cm painful ulcer in the vaginal introitus.

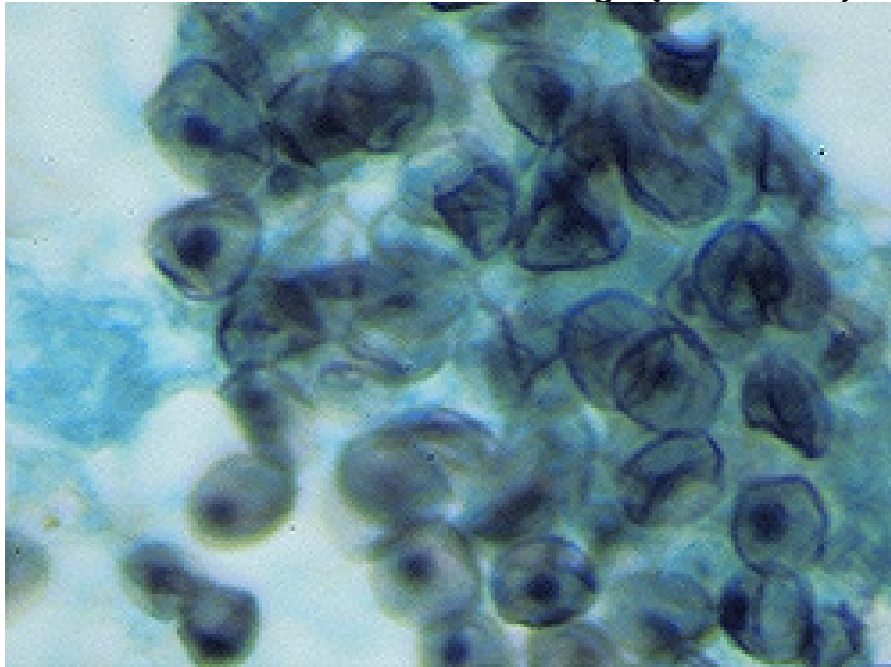
Initial laboratory studies reveal a Hgb of 11.5 gm/dL, a white blood cell count of 3,000 with 80% polys, 3% bands, 7% monocytes and 10% lymphocytes. Aspartate aminotransferase (AST) and alanine aminotransferase (ALT) are 45 and 50, respectively (mildly elevated). Renal function and electrolytes are normal. Oxygen saturation is 91% on room air, dropping to 85% after walking up and down the hall (abnormal). An arterial blood gas reveals a pO₂ of 65 on room air (quite low). Electrocardiogram shows sinus tachycardia. Chest x-ray shows bilateral, interstitial infiltrates (slide #27).

Slide #27: Gloria's chest xray



The patient is admitted to CPMC for evaluation and treatment. A bronchoscopy is performed and reveals *Pneumocystis jiroveci* organisms (slide#28).

Slide #28: Gloria's bronchial lavage (silver stain)



An HIV antibody test, drawn on admission, turns out to be positive.

1. Now that you know the patient is HIV antibody positive, what other tests would you do to characterize her stage of disease?
2. The patient is found to have pneumocystis pneumonia (PCP) which is known as an opportunistic infection. What is meant by the term opportunistic infection? What is the usual presentation of PCP in a patient with AIDS? She is treated with both trimethoprim-sulfamethoxazole and methylprednisone. Why was a steroid used in this case?
3. Her CD4 cell count is found to be $30/\text{mm}^3$, and the HIV RNA level is 350,000 copies/ml. Are you suspicious that any other processes are going on in this patient? If so, what might some of them be?

The patient responds to treatment. On the 7th hospital day, a phlebotomist suffers a needle stick after drawing blood from the patient.

4. What is the risk of HIV transmission from a needle stick from a known HIV positive source?
5. What are the factors that contribute to a higher risk of transmission?
6. What other viruses besides HIV would you be worried about being transmitted by needle stick?
7. What should the phlebotomist do?
8. If Gloria decides to have another child what can be done to decrease the risk of transmission of HIV to her baby?

Session 8: Viral Infections

1) Maddy S. gets confused

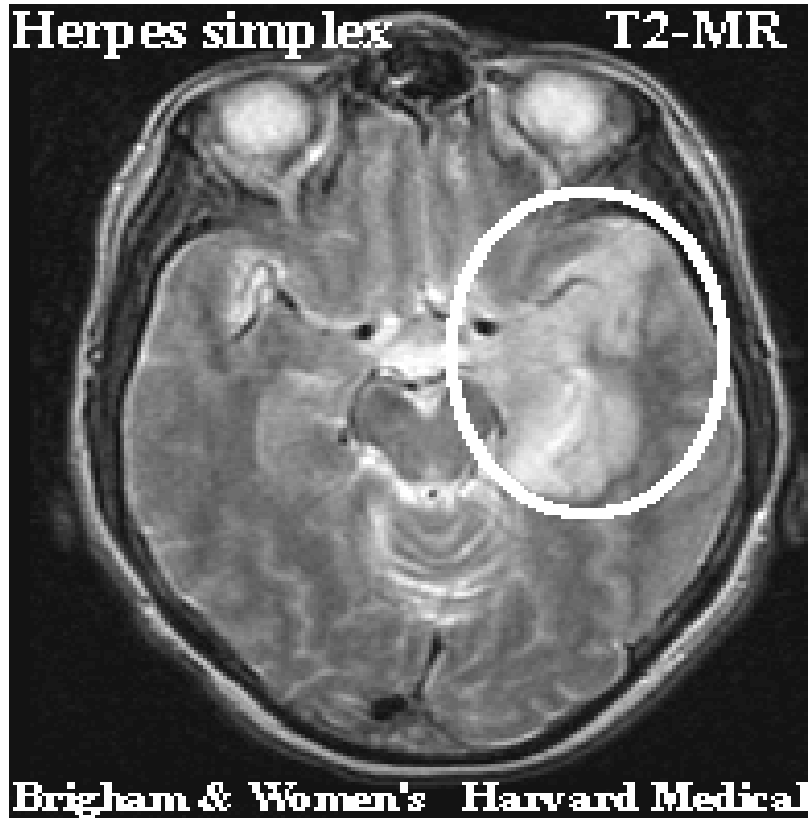
Maddy S., a 45 year old previously healthy housewife, awakens at 3 in the morning, makes the bed, showers, dresses and goes to the kitchen to make breakfast. At six in the morning, her husband awakens and is surprised to find that his wife has gone through her usual routine daily activities at such an odd hour. He asks her why she behaved like this but she doesn't think anything is abnormal. She describes "hearing something" when she woke in the middle of the night but can't remember the details. She states she feels "OK" except for a left sided headache. The husband notes that his wife appears to be having trouble finding words and is somewhat halting in her speech pattern. He is concerned and wishes to take his wife to the doctor but she doesn't want to go. Twelve hours later, however, his wife is witnessed to have a seizure which initially involves the right upper extremity but evolves into a generalized tonic-clonic seizure with depressed consciousness. The husband calls 911 and his wife is brought to the Columbia Presbyterian Emergency Room.

In the ER, the wife is noted to have a temperature of 102°F, a blood pressure of 140/90, a pulse of 90 and a respiratory rate of 22. She is arousable but lethargic, and appears to be speaking unintelligibly in response to questions. There is no rash. The neck has some mild resistance to passive motion but not impressively so. There is no lymphadenopathy and the heart, lung, abdomen and extremity exams are normal. The neurologic exam reveals the mental status as noted, intact cranial nerves, symmetric deep tendon reflexes, and an equivocal left Babinski response. She cannot cooperate with detailed motor, sensory and cerebellar exams but she appears to withdraw her extremities symmetrically to noxious stimuli.

Initial laboratory data in the ER reveal a Hgb of 13.0 gm/dL, a white blood cell count of 7,000 with a normal differential, normal platelet count, normal electrolytes, blood urea nitrogen, creatinine and blood sugar, and normal liver enzymes. Blood and urine cultures are sent. An astute medical resident immediately starts a medication intravenously and sends the patient for an emergency head CT scan (with contrast).

The result is negative but an MRI is obtained (slide #29) and reveals increased signal in the left frontal and anteromedial temporal region (consistent with edema).

Slide #29: Maddy's MRI



No mass effect is seen so a lumbar puncture is performed. This reveals an opening pressure of 140 mm of water, a white cell count of 55 with 60% lymphocytes, 40% PMNs, a protein of 70 mg/dL and a normal sugar. Gram stain does not show any bacteria.

1. What is your differential diagnosis?
2. Is there any other history that you would like to obtain from the patient or her husband?
3. What are the important clues in her available history, initial ER examination and laboratory data?
4. How would you characterize the pathogenic process that is likely occurring in this patient?
5. What additional diagnostic tests might you order?

2) The Wedding Party

A worried family called their local Public Health Department because of an outbreak of “food poisoning”. The family, consisting of 2 children (ages 7 months and 7 years) and 8 adults, had been staying together in a guesthouse for an upcoming wedding. One week earlier the family had eaten at a local hamburger joint. That night the 7 year old child stayed up all night vomiting. She was noted to have a temperature of 102°F and was lethargic the next day; however, the vomiting episodes decreased in frequency. She was noted to have a few watery diarrheal stools but was generally much improved. The following night her baby brother began to vomit although he did not have a fever. The children’s father felt a little queasy the next morning, but attributed this to the bachelor party he had attended the night before. On the day of the wedding, 3 days after the first child became ill, her aunt, one of the bridesmaids, felt “carsick” on the way to the church. One hour later she began to vomit profusely and had non-bloody, watery diarrhea with abdominal cramping- symptoms that seriously interfered with her bridesmaid’s duties. She did not take her temperature but reported feeling “hot”. Her symptoms lasted approximately 24 hours but she felt weak for a few days. Approximately 6 hours after the onset of the aunt’s symptoms the children’s mother, grandmother and grandfather became ill. All had abdominal cramping and diarrhea. The grandfather also had vomiting. Their symptoms lasted approximately 24 hours. All resolved without sequelae and no hospitalizations were required. Two days later several extended family members who had been present at the wedding and had had contact with the family reported similar illnesses. Concerned that the outbreak had started at the hamburger joint and having heard about a lethal form of gastroenteritis associated with hamburgers, the children’s father called the local health department to report the outbreak. Upon questioning by the health department he recalled that he had taken his daughter to a seafood restaurant (she loved raw oysters) the day before she became ill and that they had gone swimming in a neighbor’s pool that afternoon.

1. Which features of this illness and outbreak make it more or less likely to be viral or bacterial in origin?
2. What are the likely microbiological culprits? Was the hamburger joint responsible? What about the swimming pool and raw oysters?
3. How could the diagnosis have been made?
4. What is the pathogenesis of this type of infection?