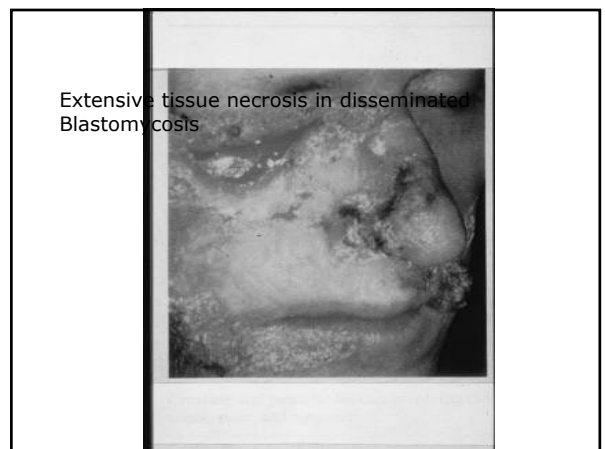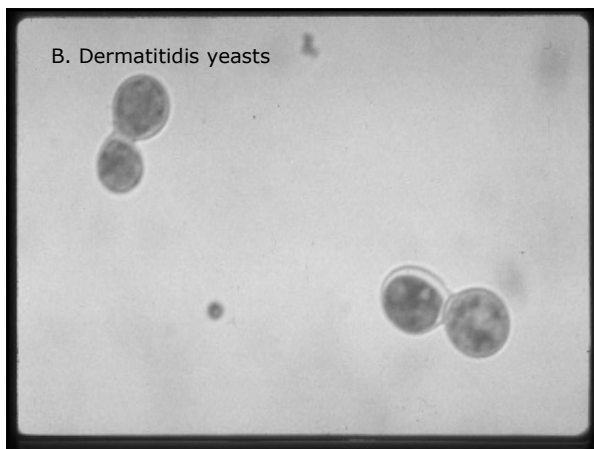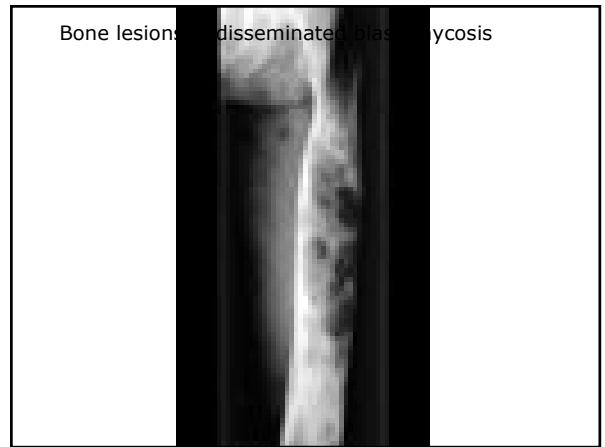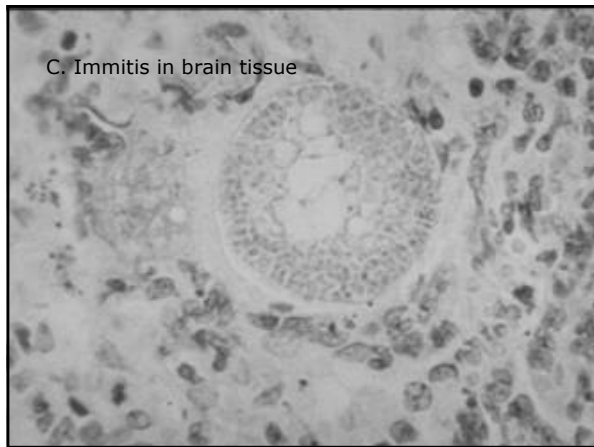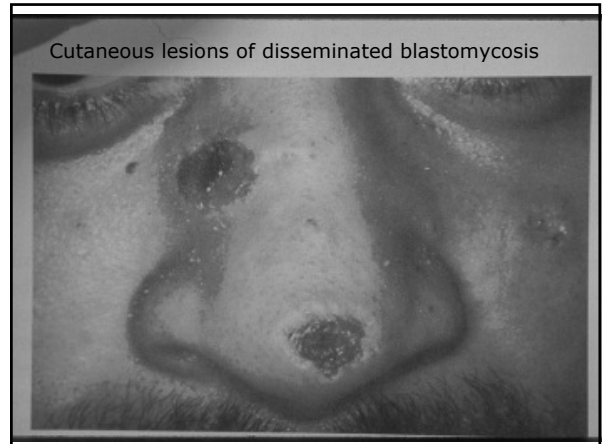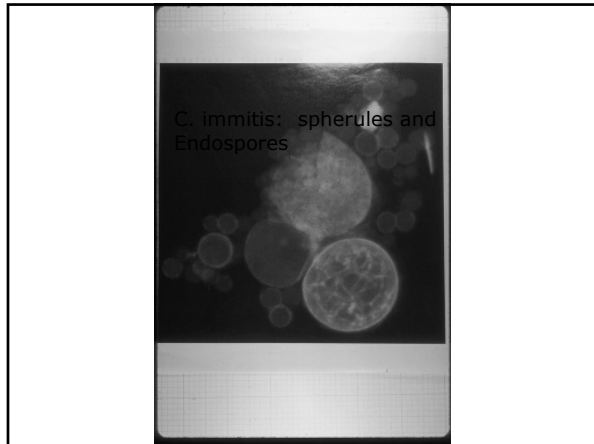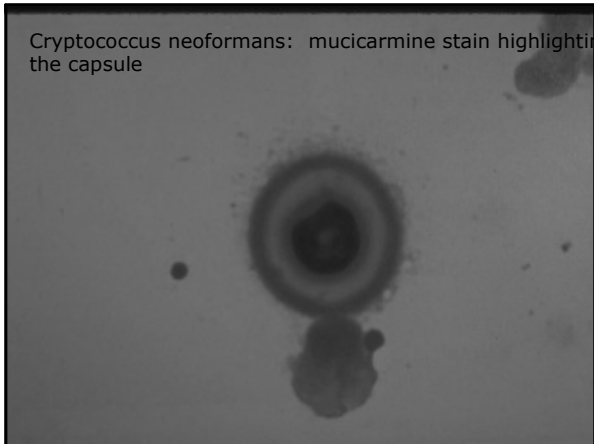
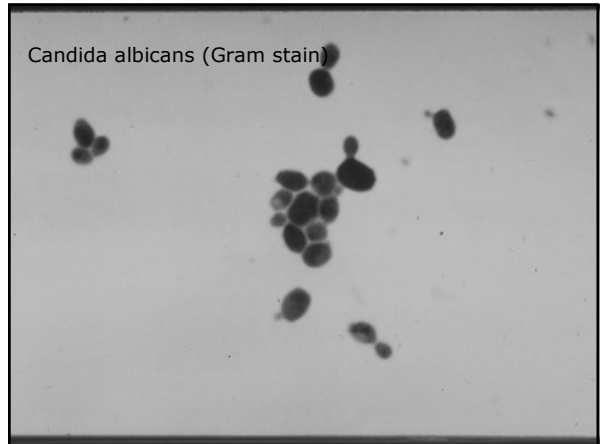


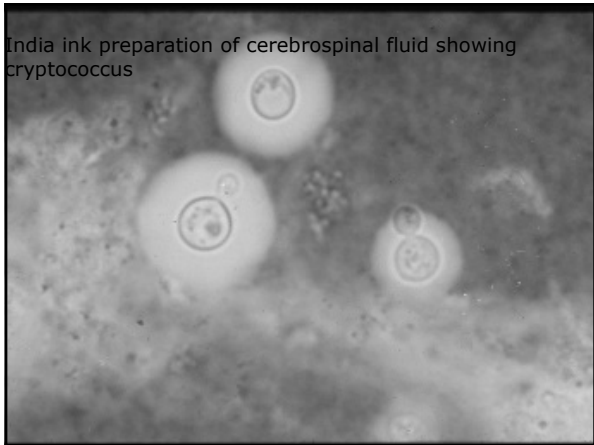
Cryptococcus neoformans: mucicarmine stain highlighting the capsule



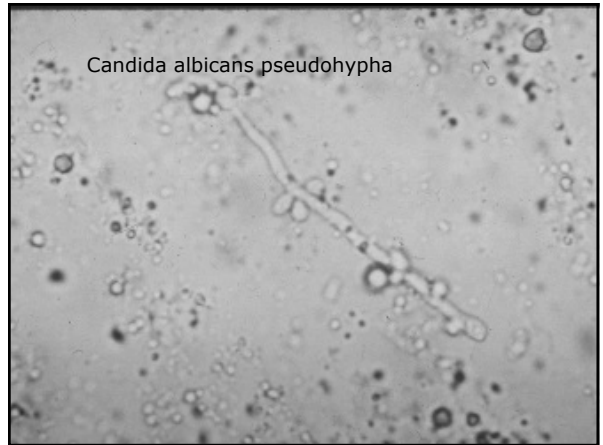Candida albicans (Gram stain)



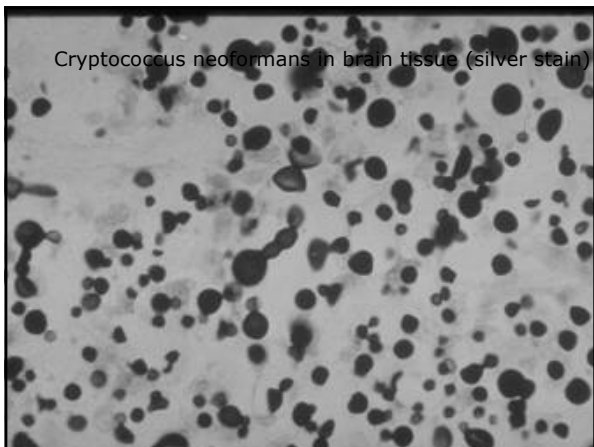
India ink preparation of cerebrospinal fluid showing cryptococcus



Candida albicans pseudohypha



Cryptococcus neoformans in brain tissue (silver stain)



Candida skin infection



