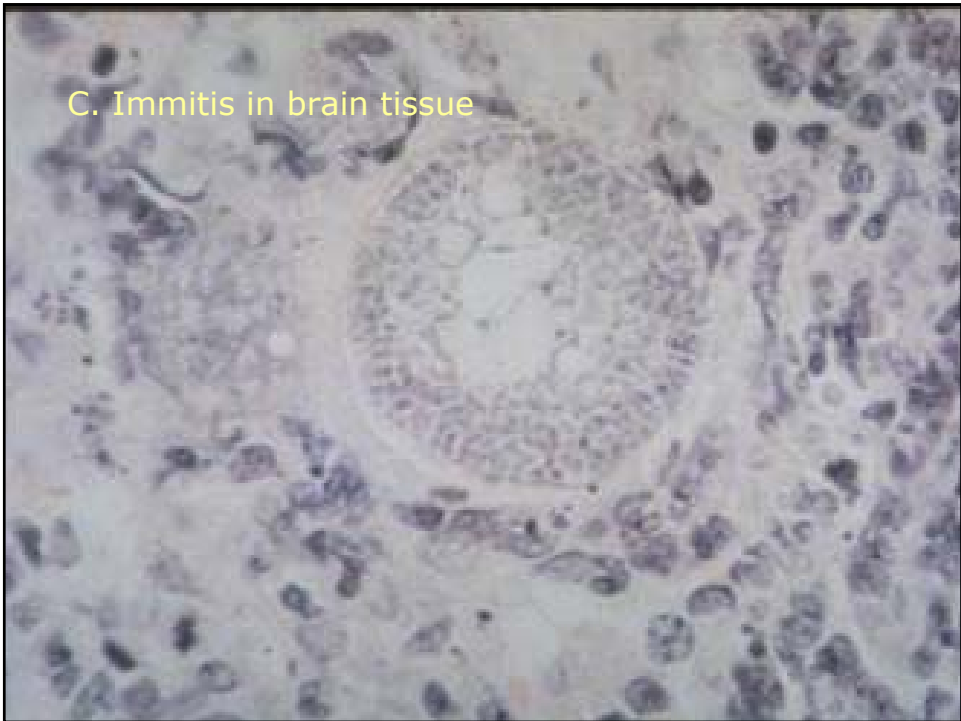
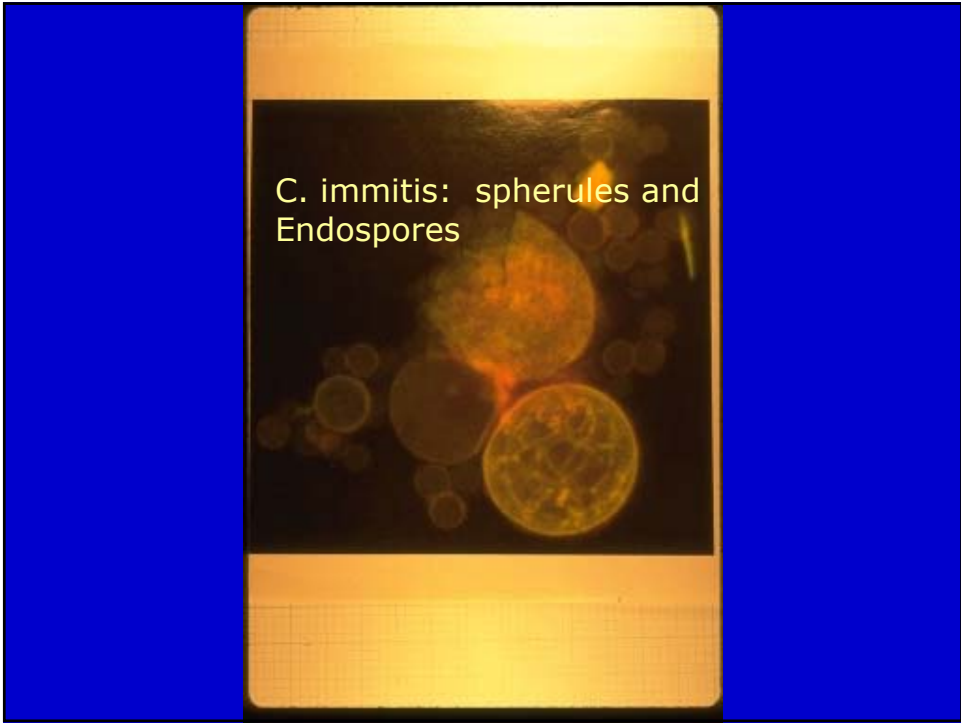
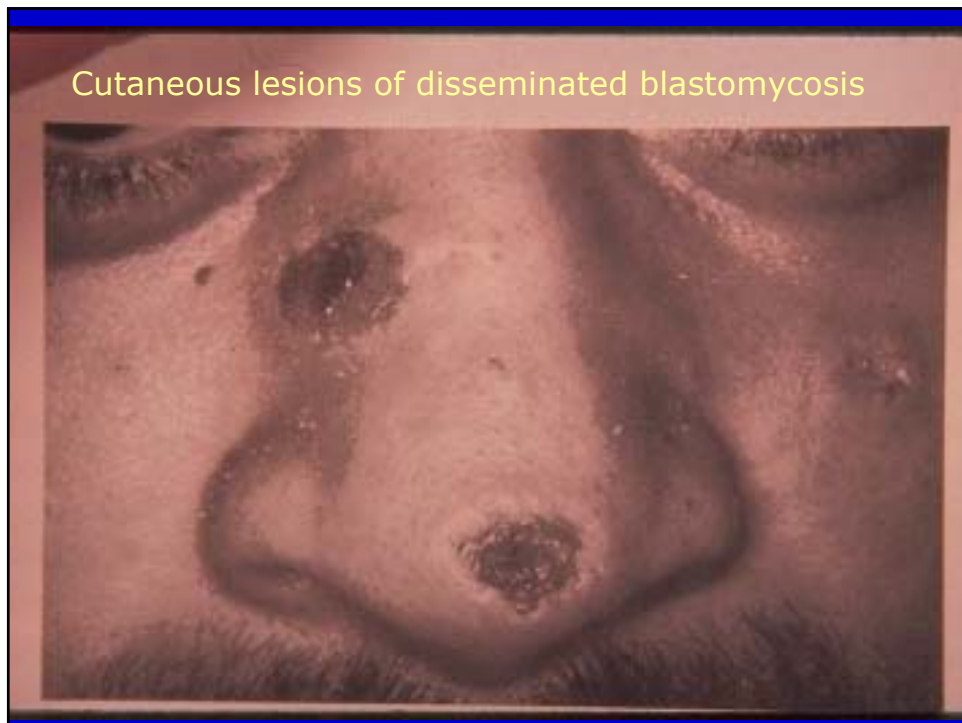
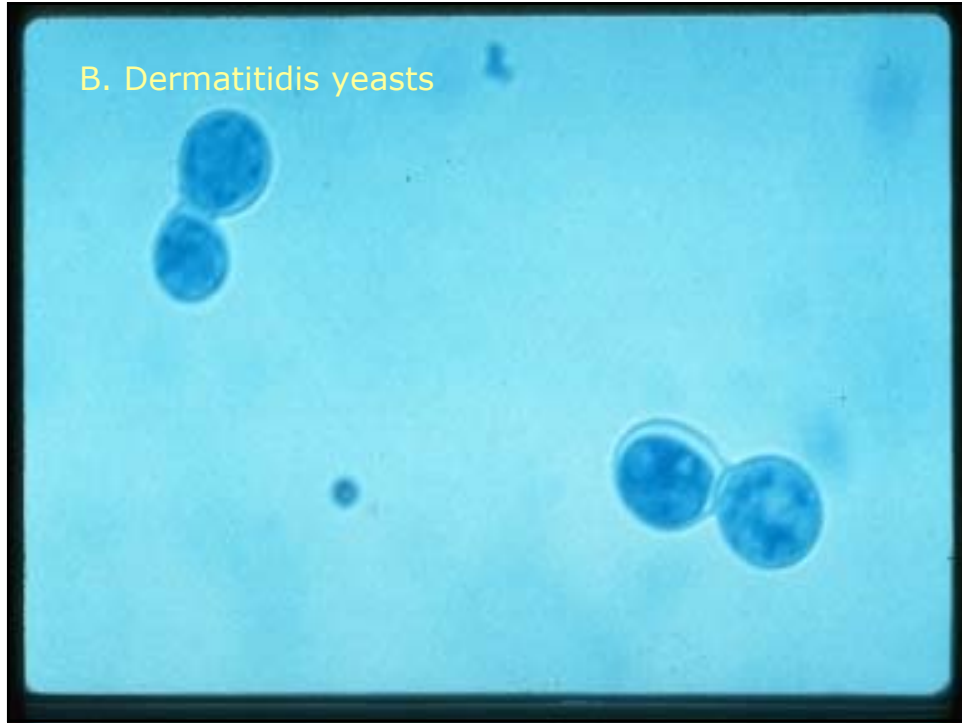
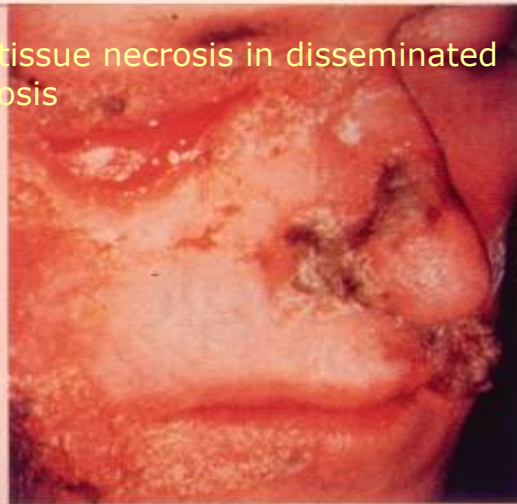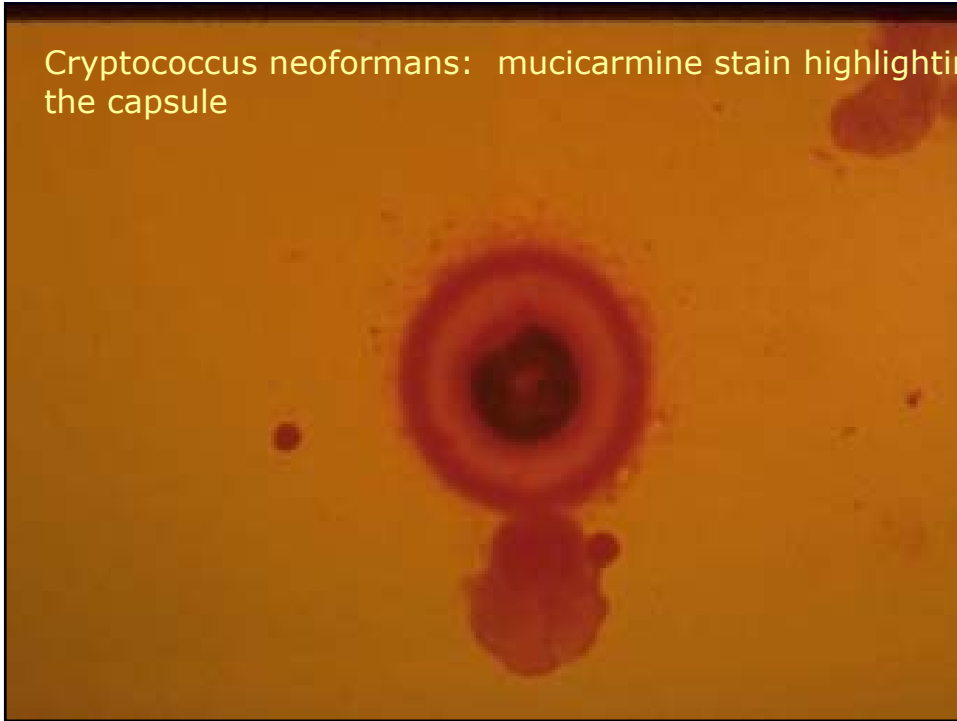Bone lesions in disseminated blastomycosis



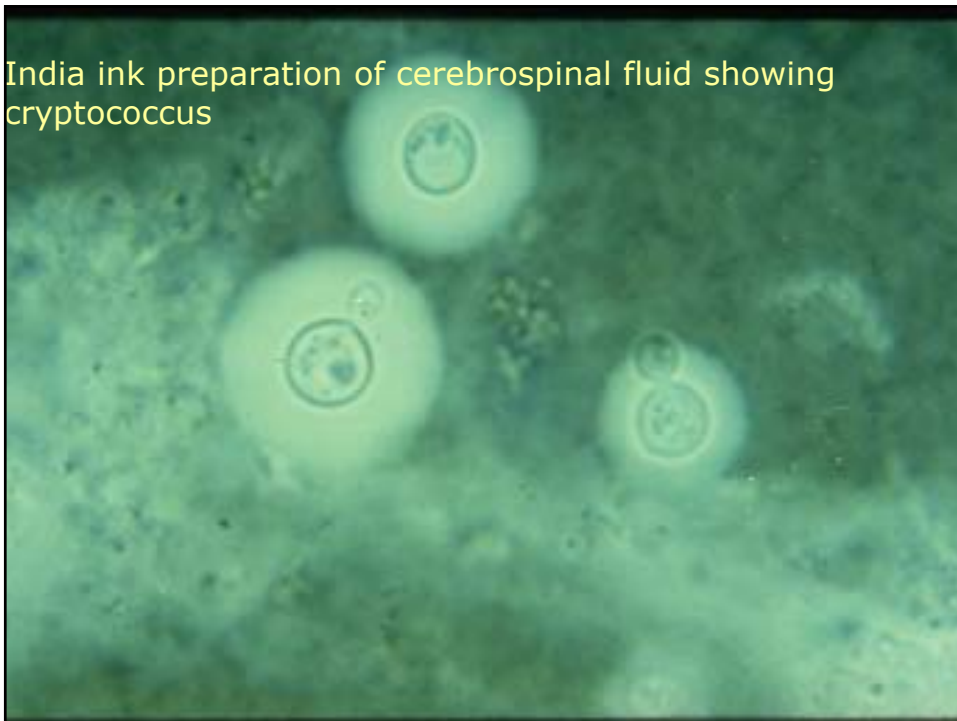
Extensive tissue necrosis in disseminated Blastomycosis

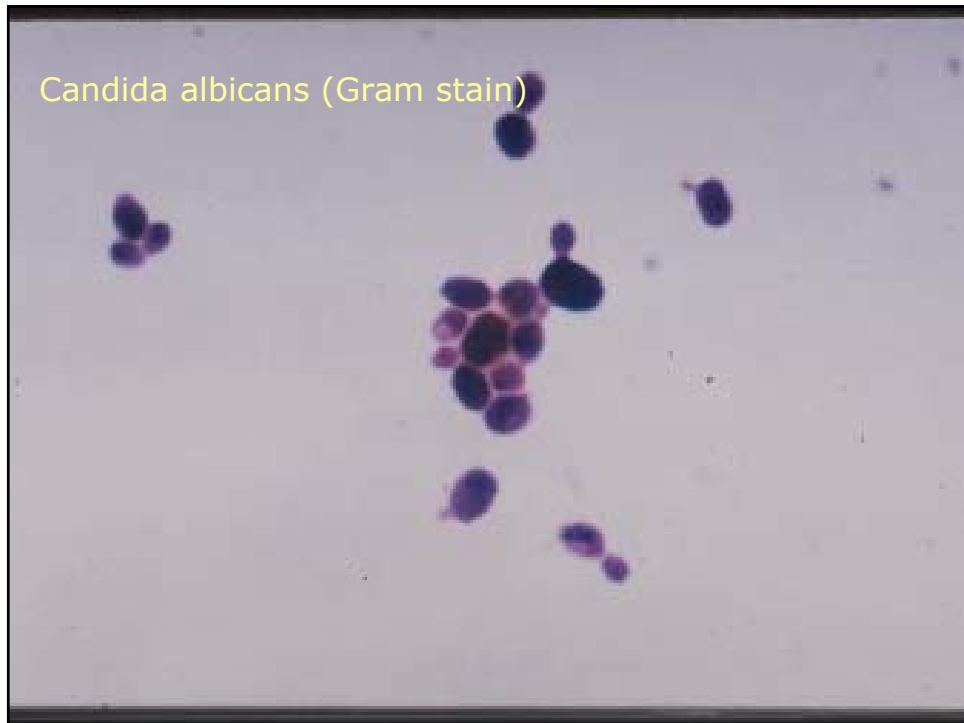
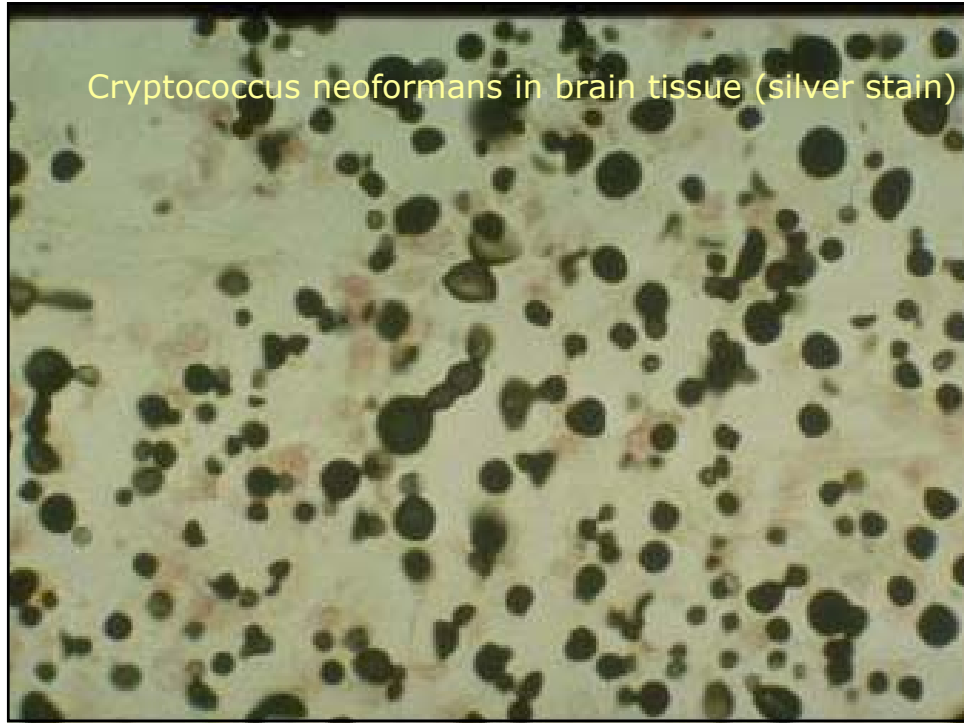

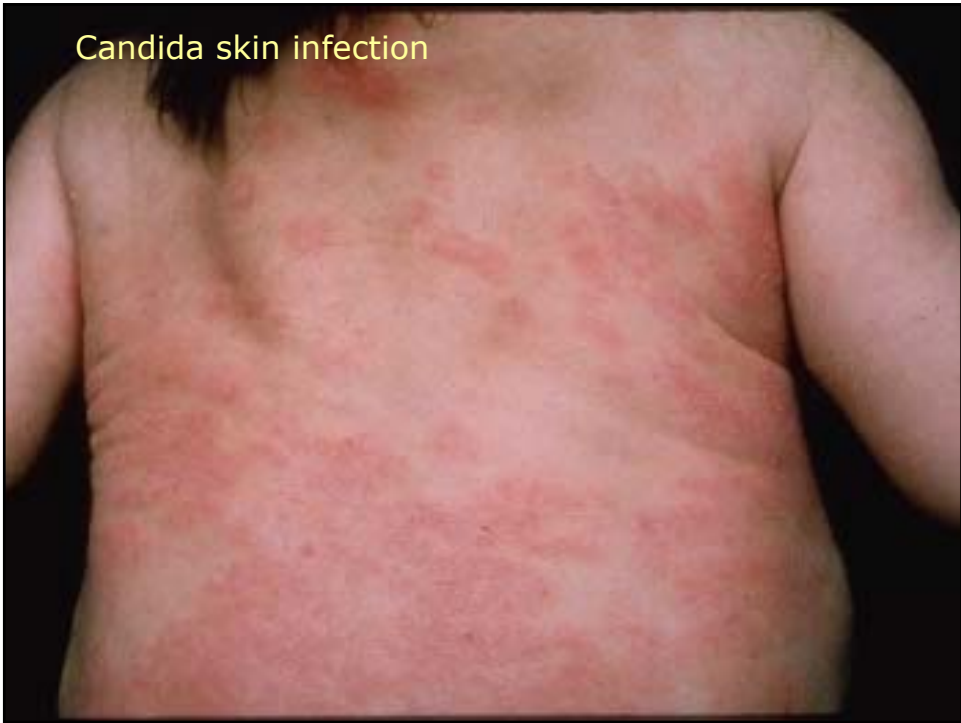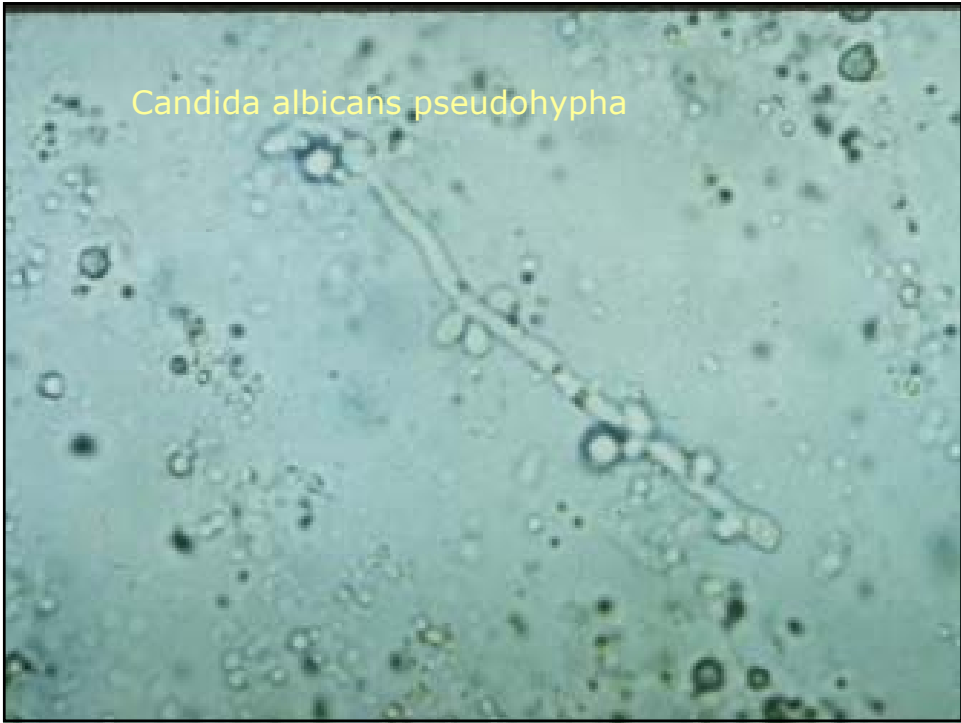Cryptococcus neoformans: mucicarmine stain highlighting the capsule



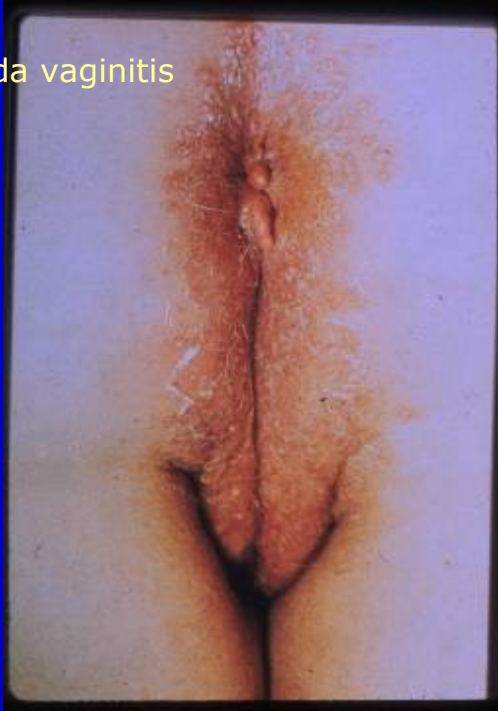India ink preparation of cerebrospinal fluid showing cryptococcus



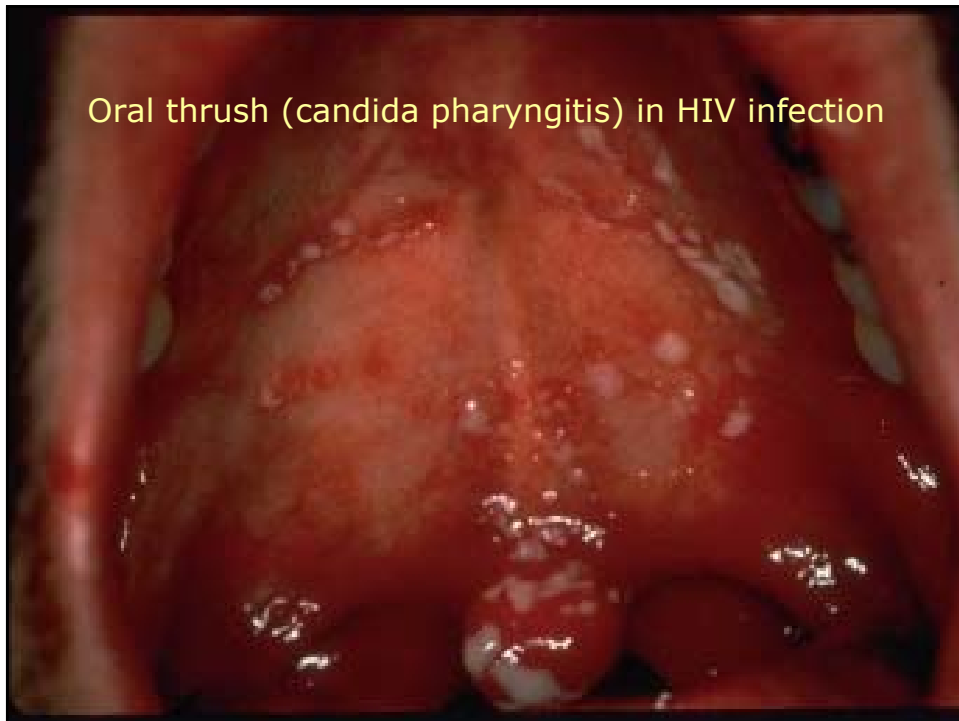




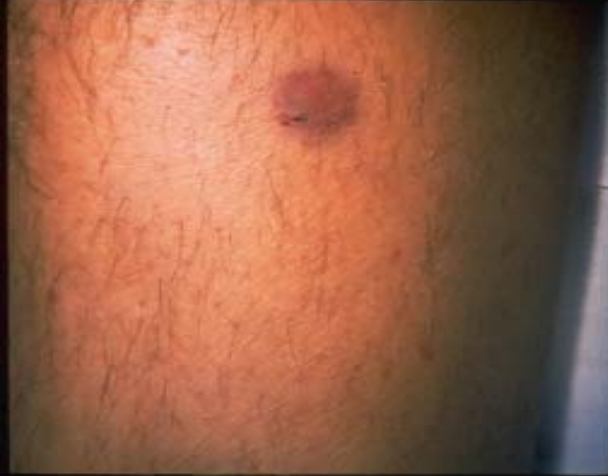Candida vaginitis



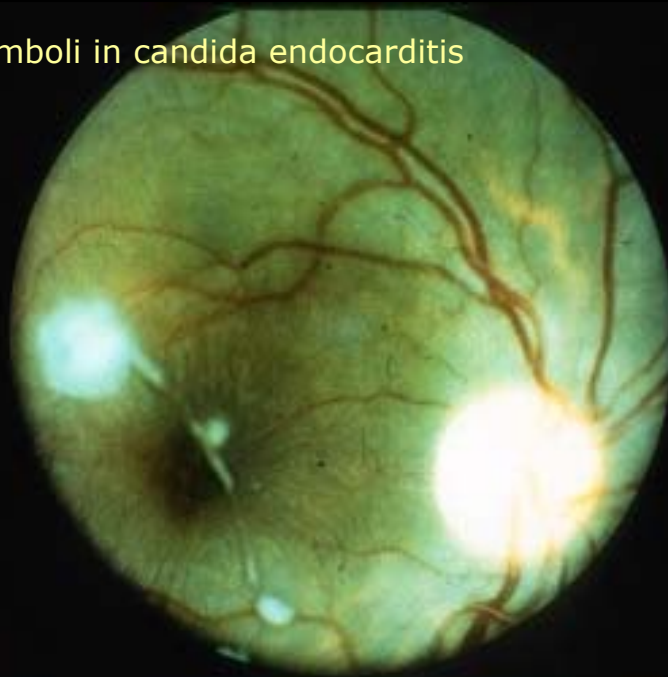
Oral thrush (candida pharyngitis) in HIV infection

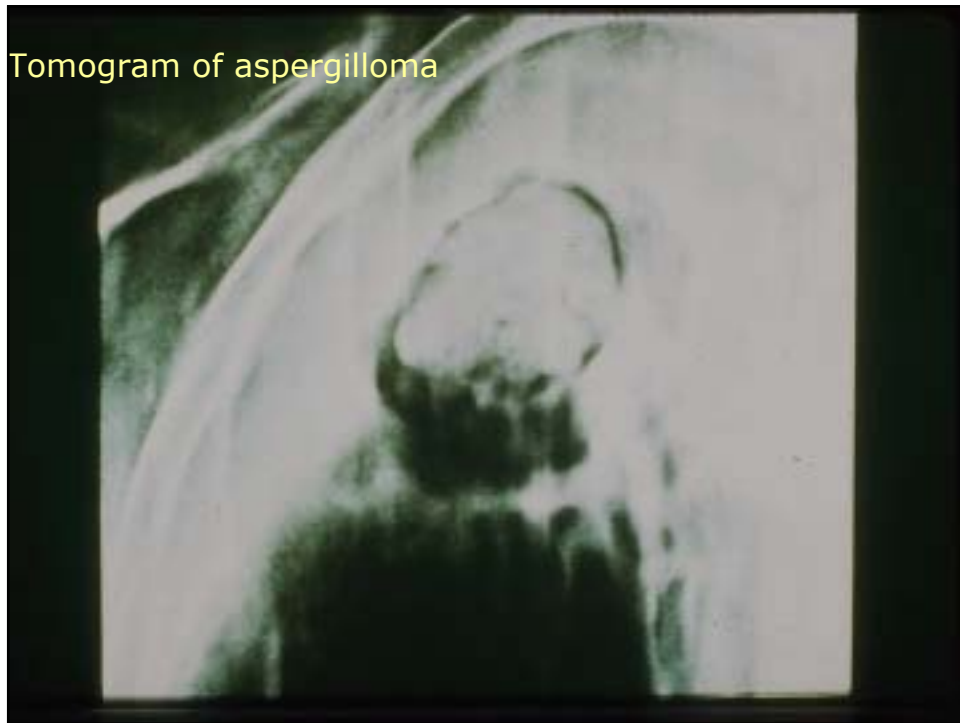
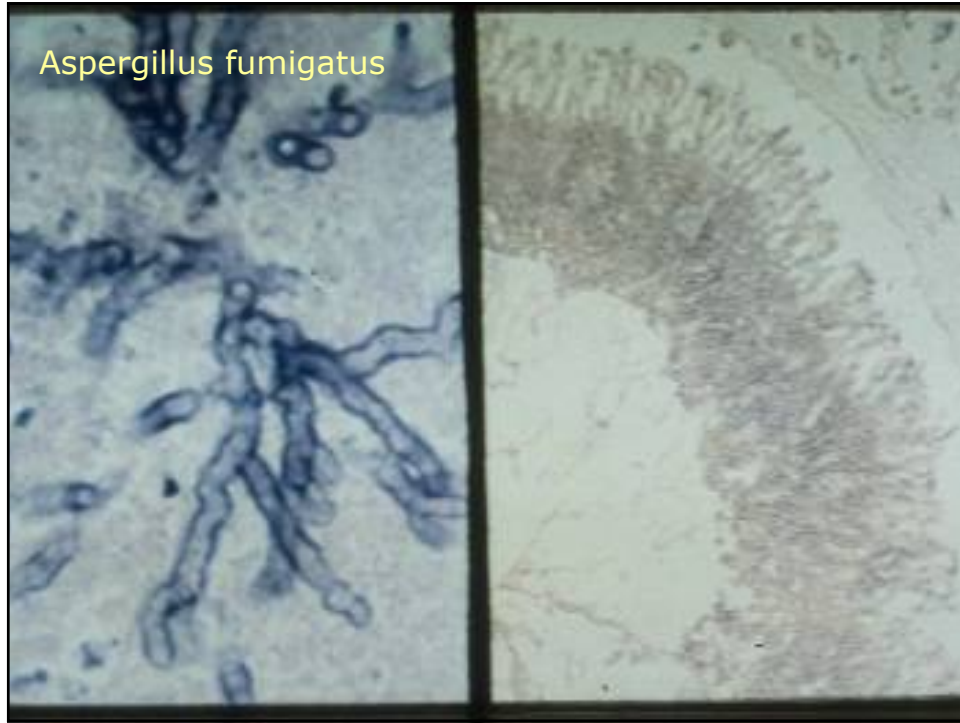


Embolic skin lesion in candida endocarditis

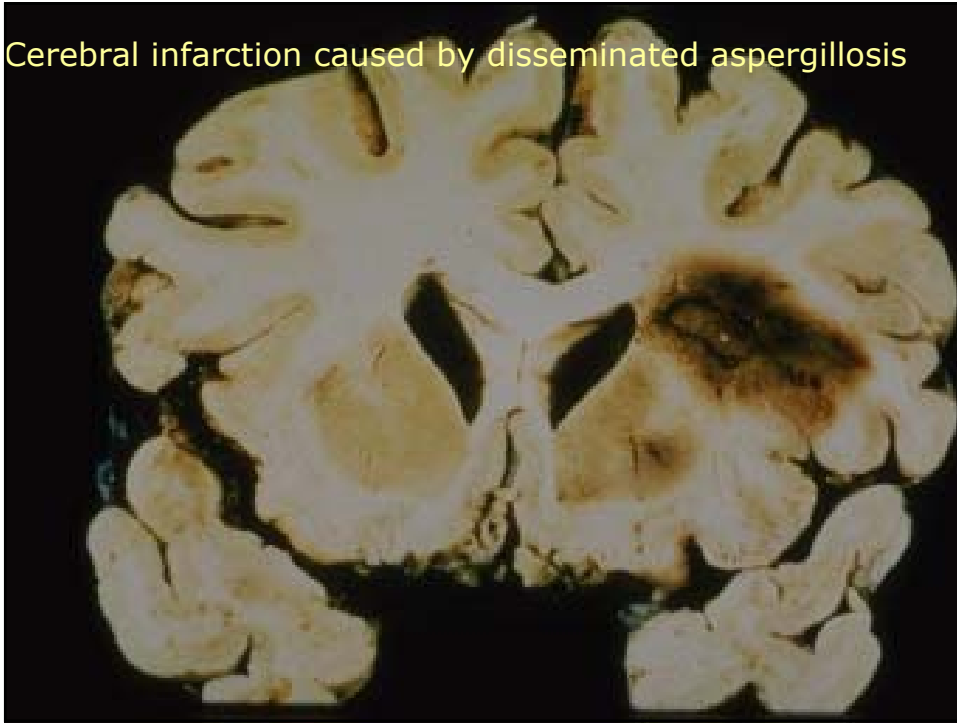


Retinal emboli in candida endocarditis

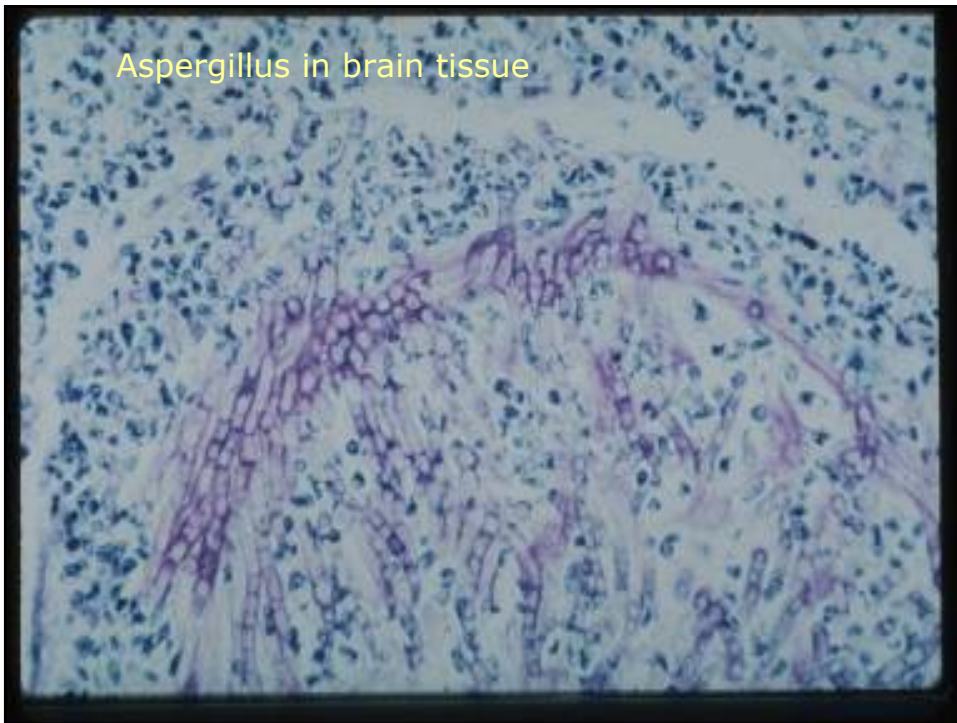




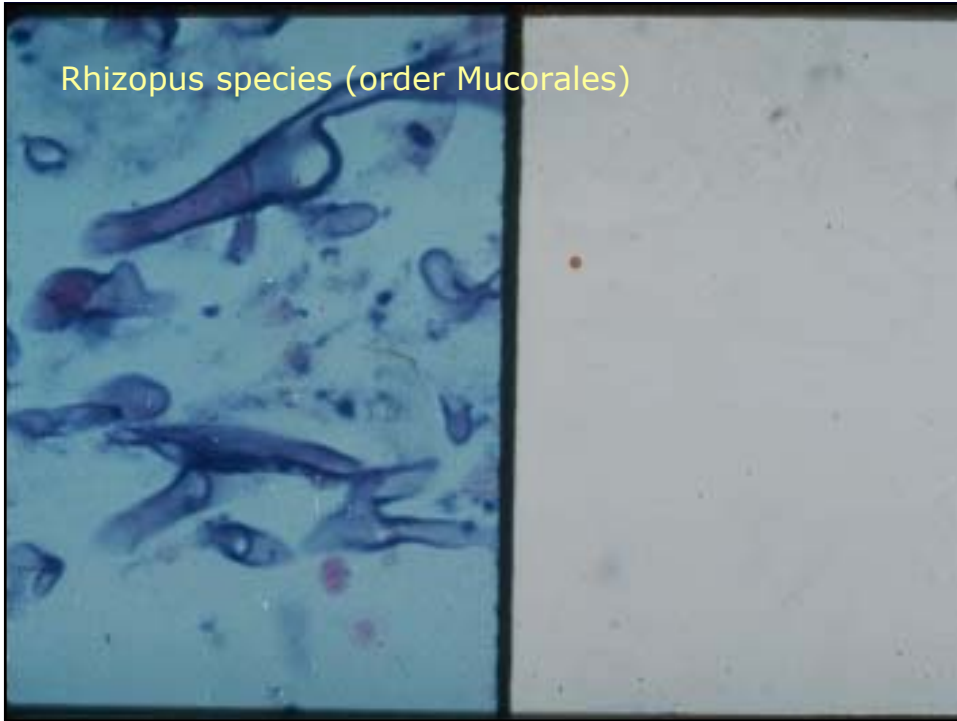Cerebral infarction caused by disseminated aspergillosis



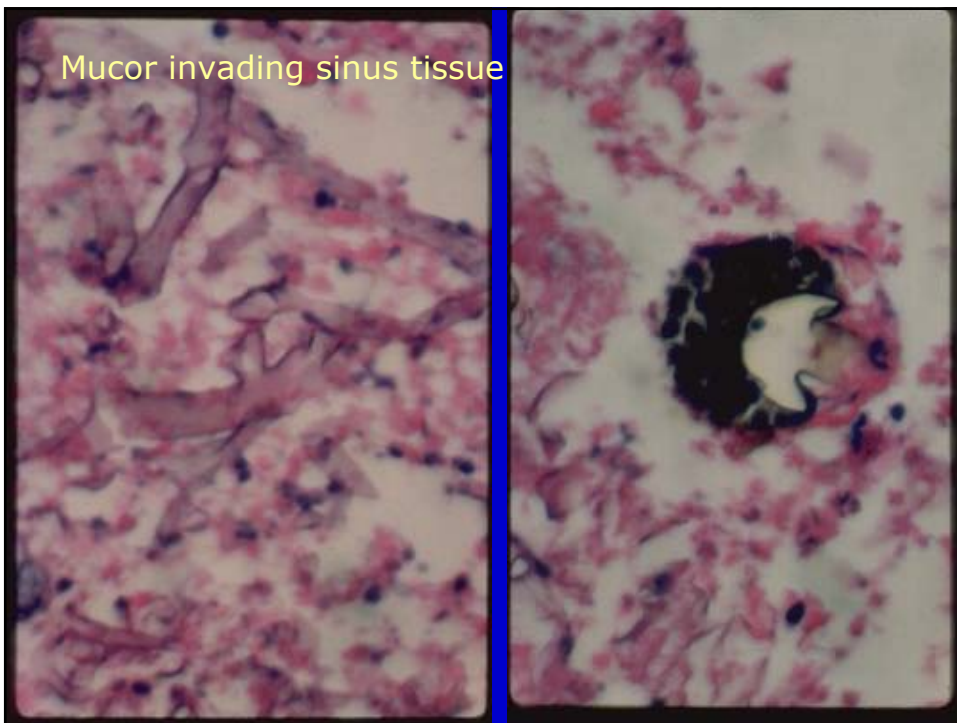
Aspergillus in brain tissue



Rhizopus species (order Mucorales)



Mucor invading sinus tissue



Mucor sinusitis, orbital cellulitis,
and brain abscess in diabetes

