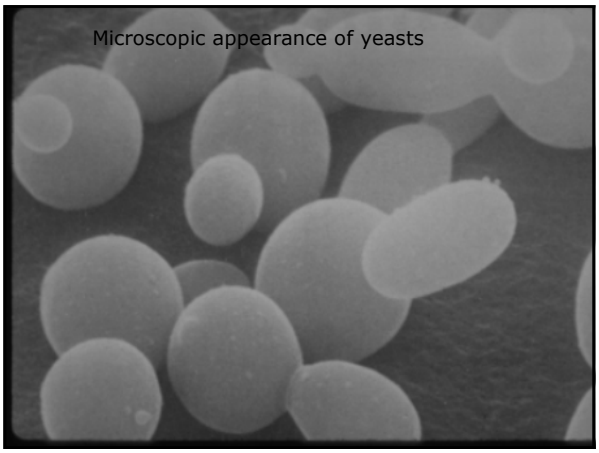
Microscopic appearance of yeasts

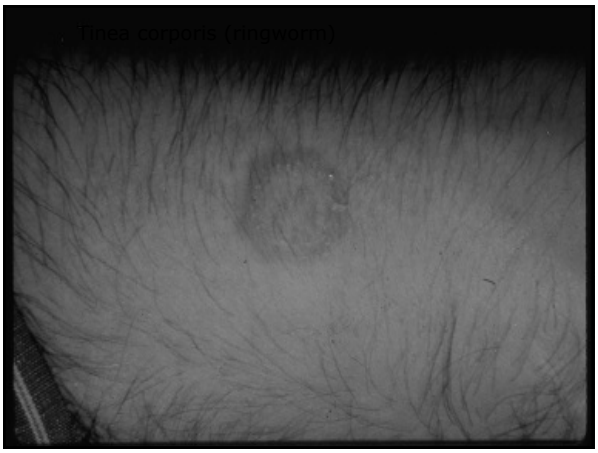
Tinea corporis (ringworm)

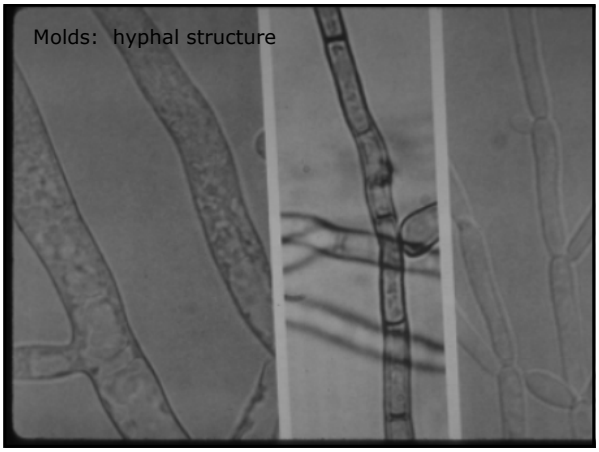
Molds: hyphal structure

Tinea corporis (ringworm) in HIV infection


Tinea corporis (ringworm)
Fig. 6.12. Ringworm of the trunk. A, Tinea imb

Tinea pedis (athletes' foot)

Tinea barbis

Tinea capitis

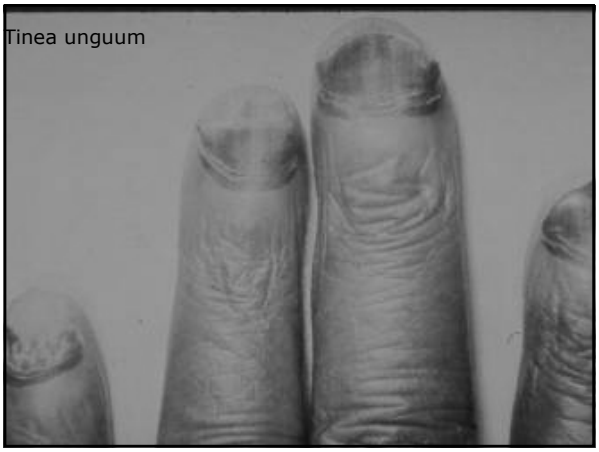
Tinea unguum

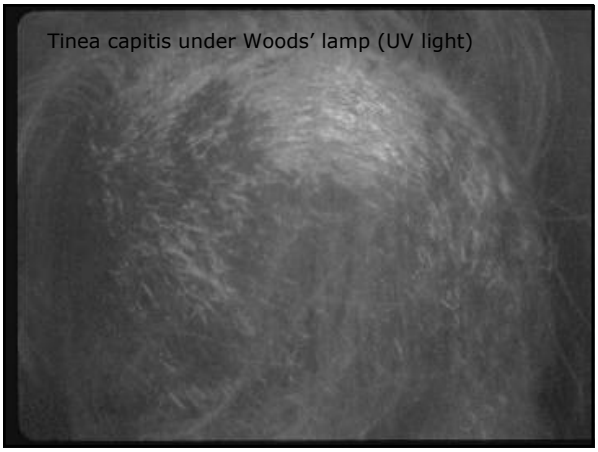
Tinea capitis under Woods' lamp (UV light)

Tinea unguum in HIV infection

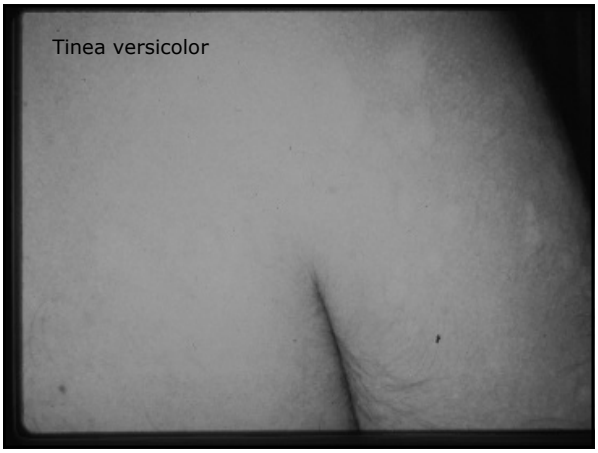
Tinea versicolor

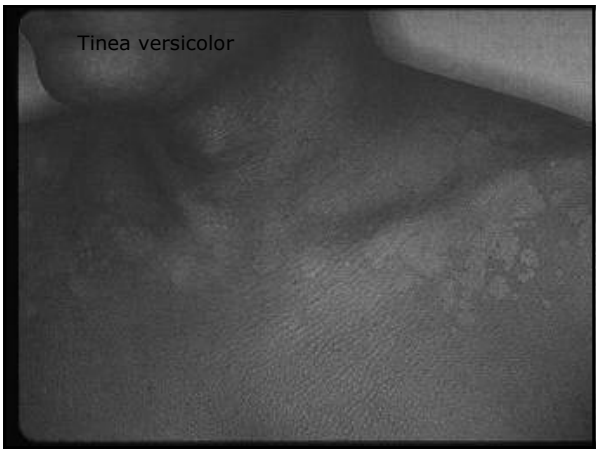
Tinea versicolor

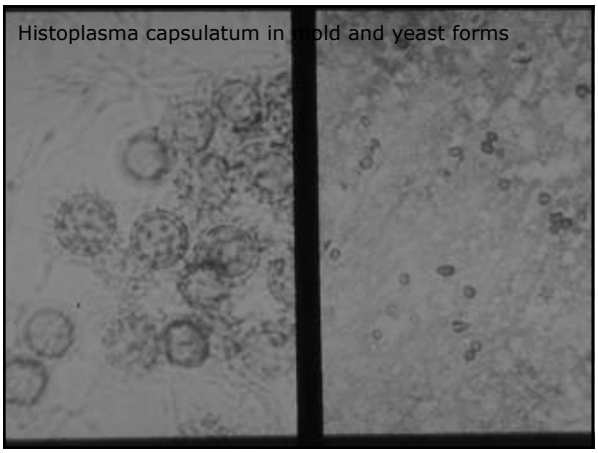
Histoplasma capsulatum in mold and yeast forms

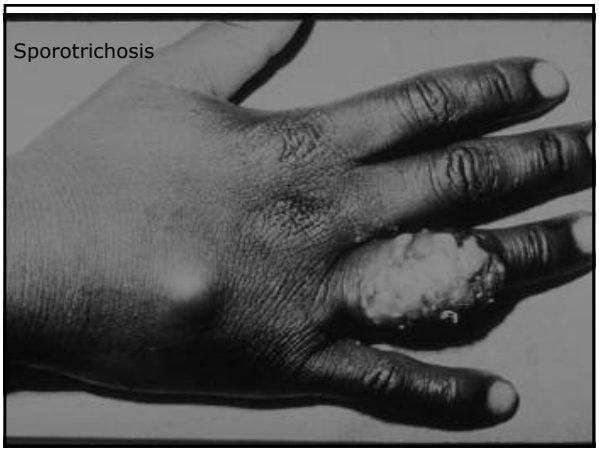
Sporotrichosis

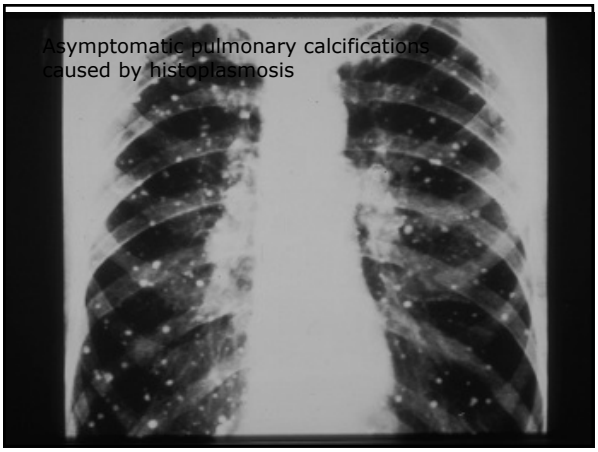
Asymptomatic pulmonary calcifications caused by histoplasmosis

Disseminated sporotrichosis in AIDS

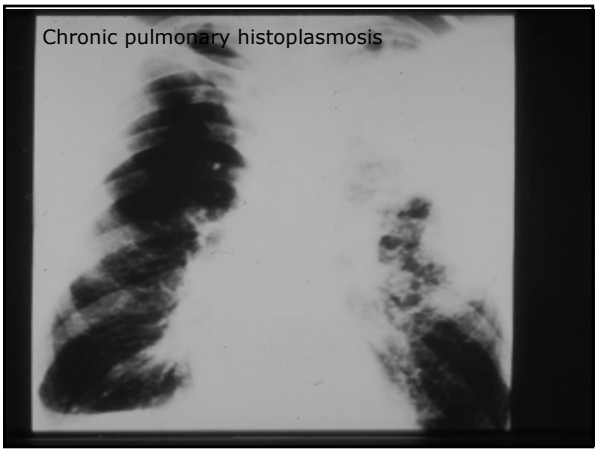
Chronic pulmonary histoplasmosis

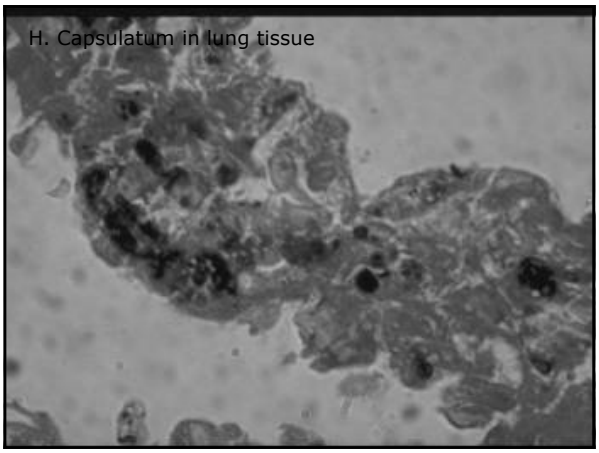
H. Capsulatum in lung tissue

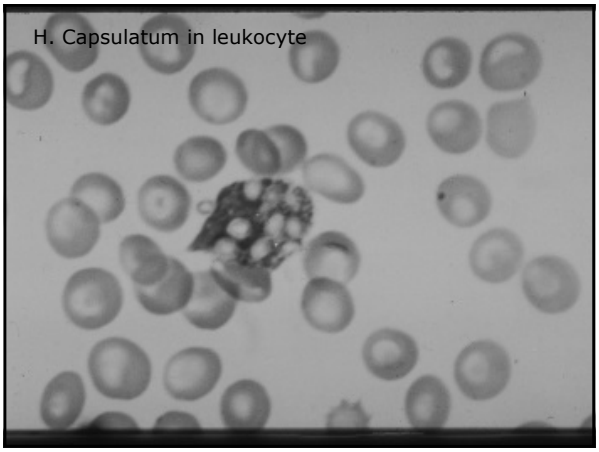
H. Capsulatum in leukocyte