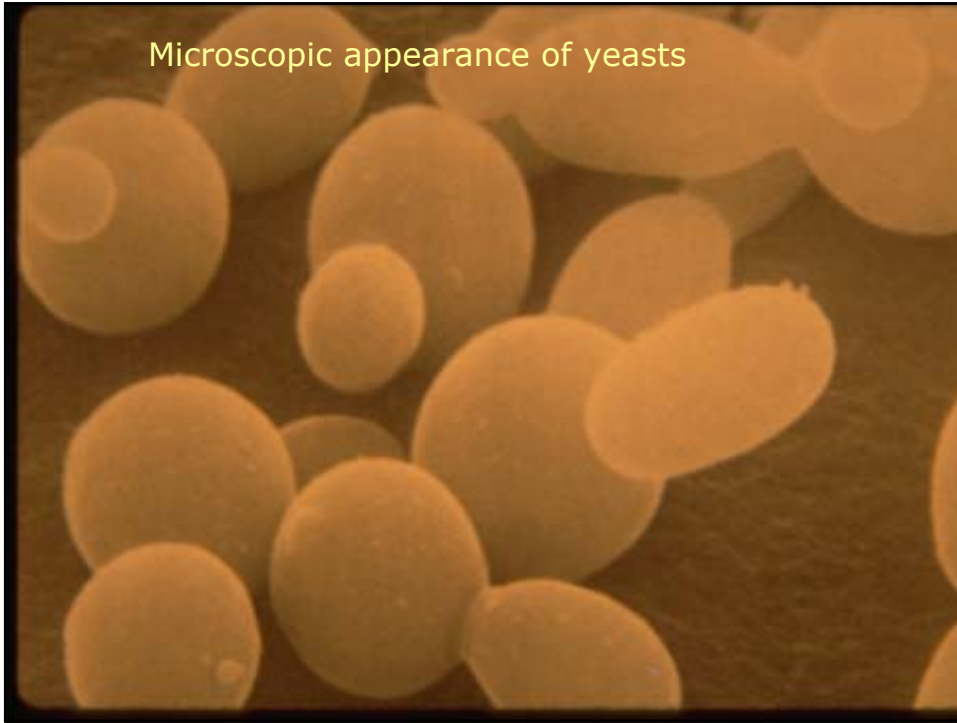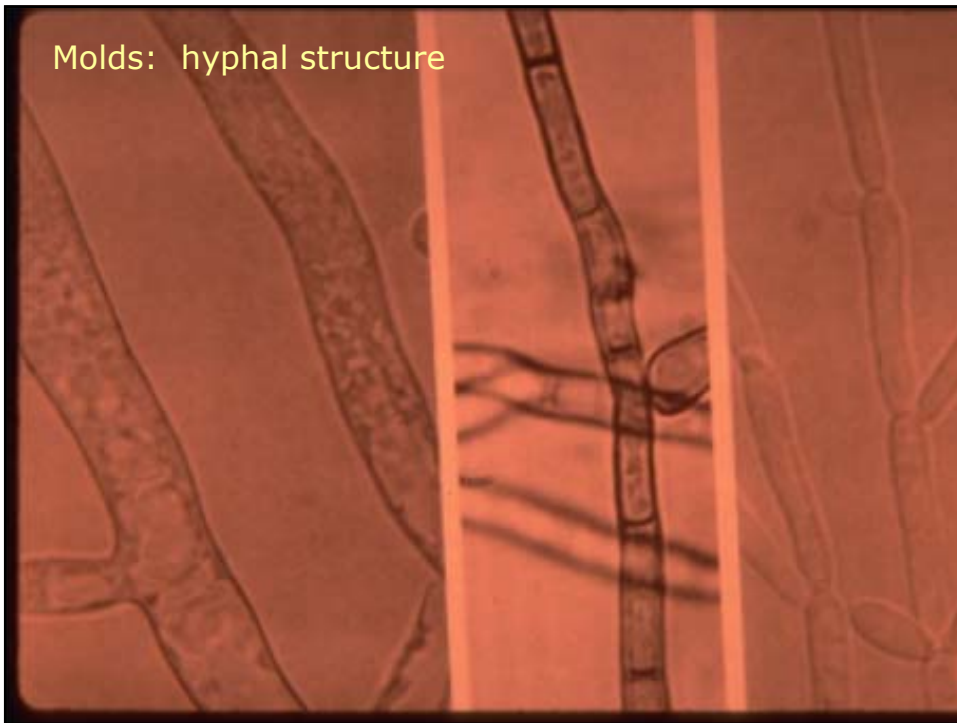


Microscopic appearance of yeasts



Molds: hyphal structure



Tinea corporis (ringworm)

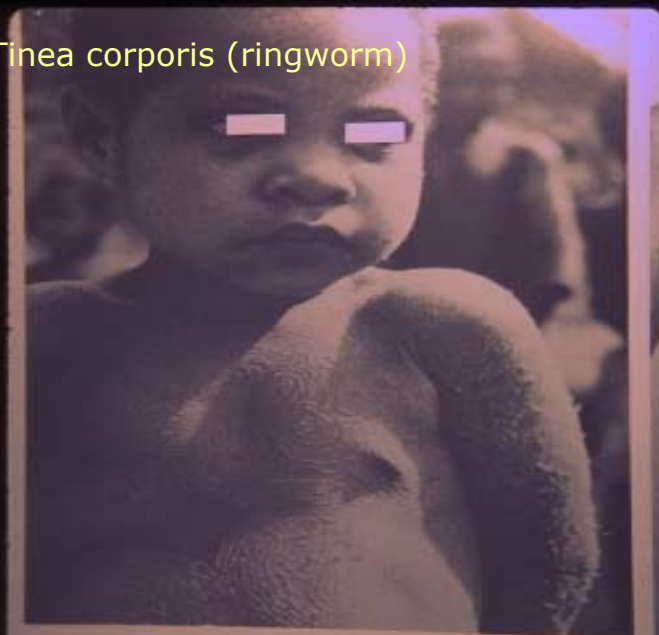
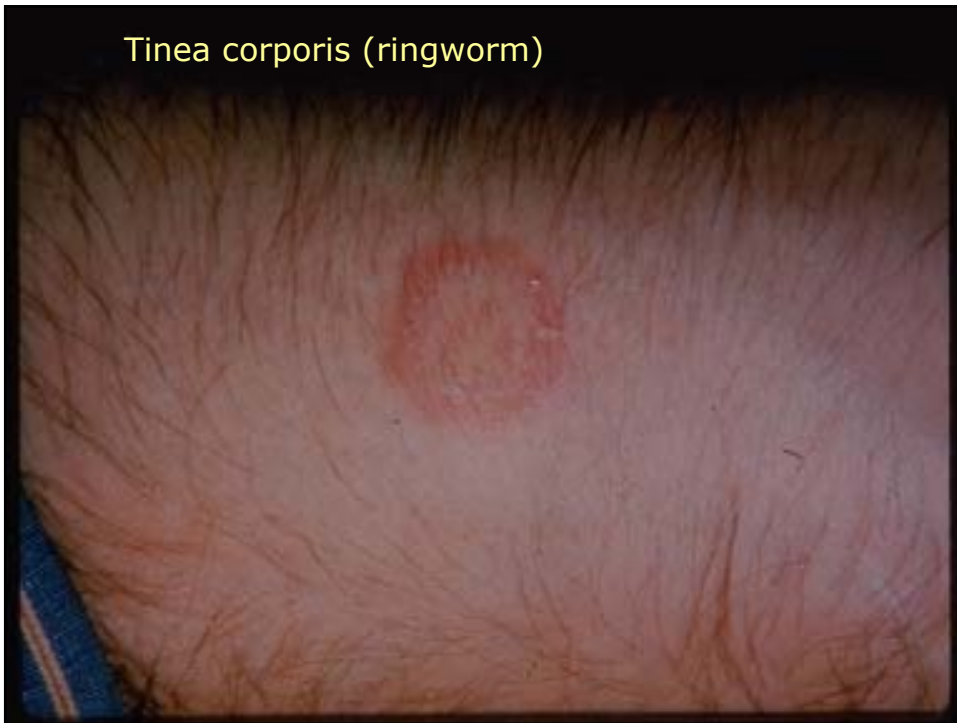
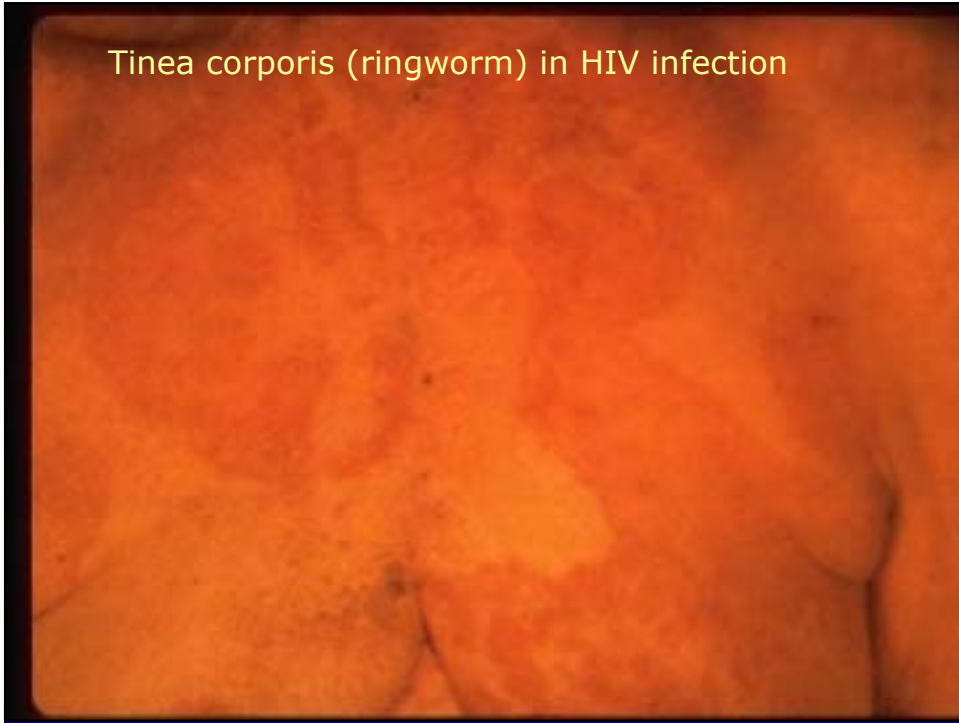Fig. 6.12. Ringworm of the trunk. A, *Tinea imbricata* showing concentric pattern of

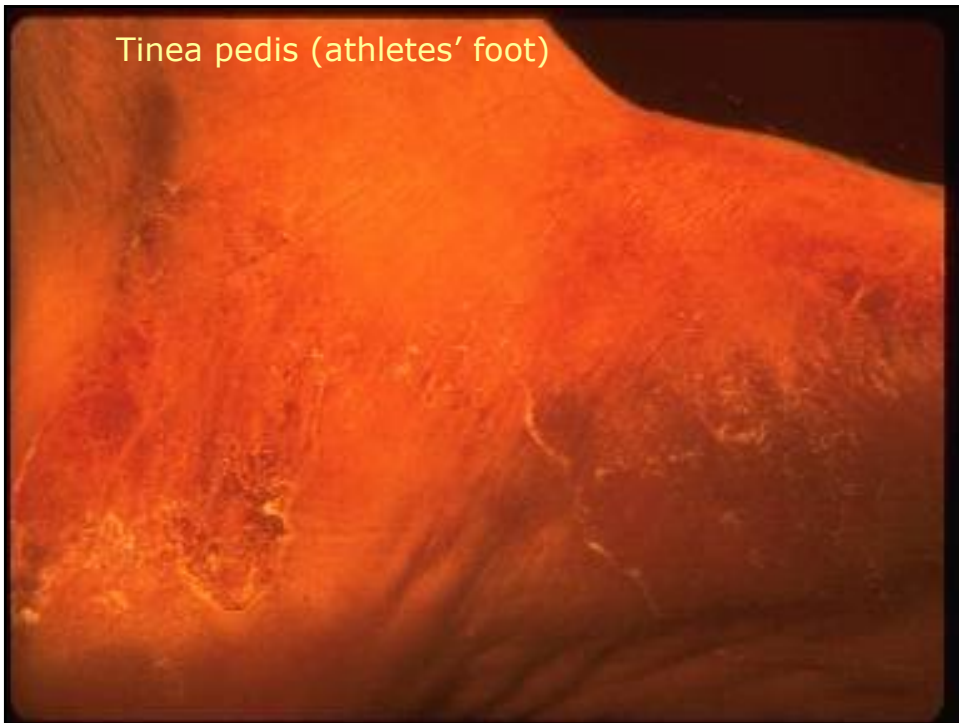Tinea corporis (ringworm)

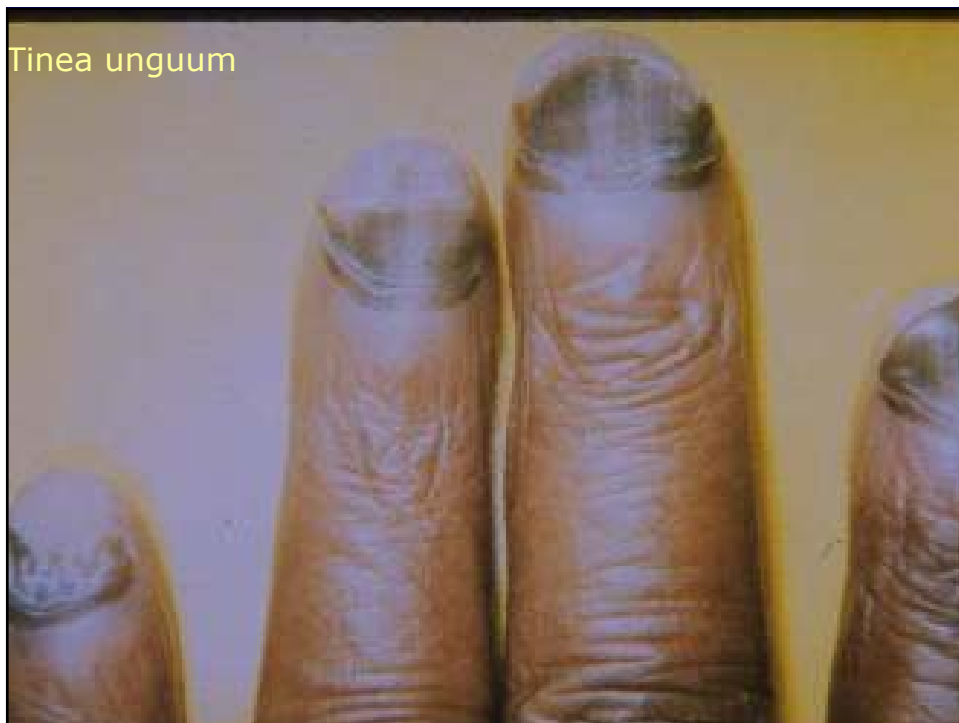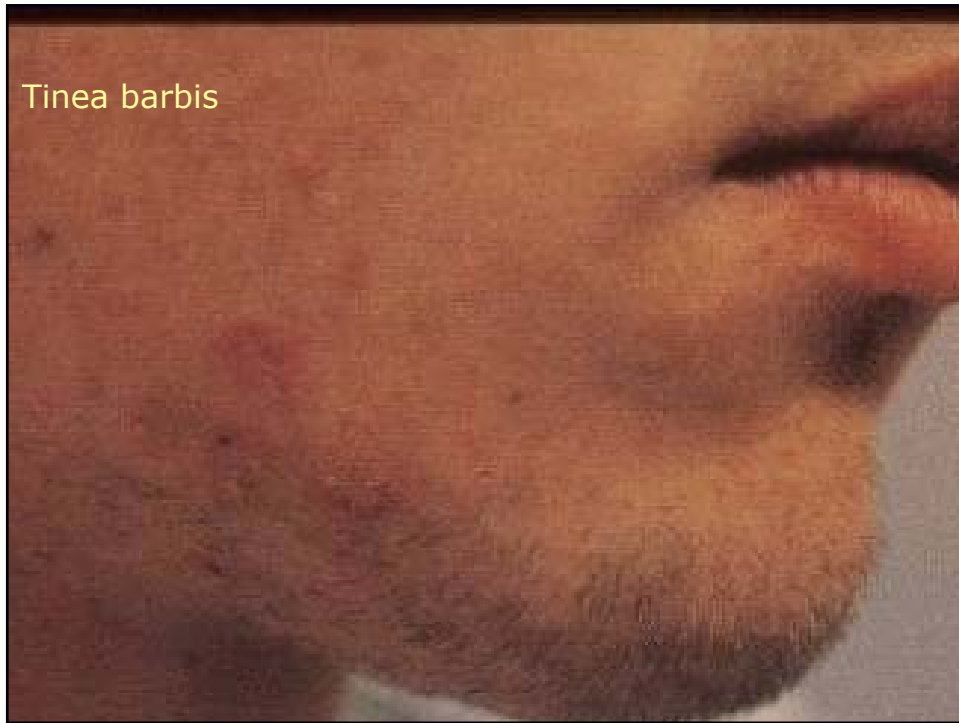


Tinea corporis (ringworm) in HIV infection

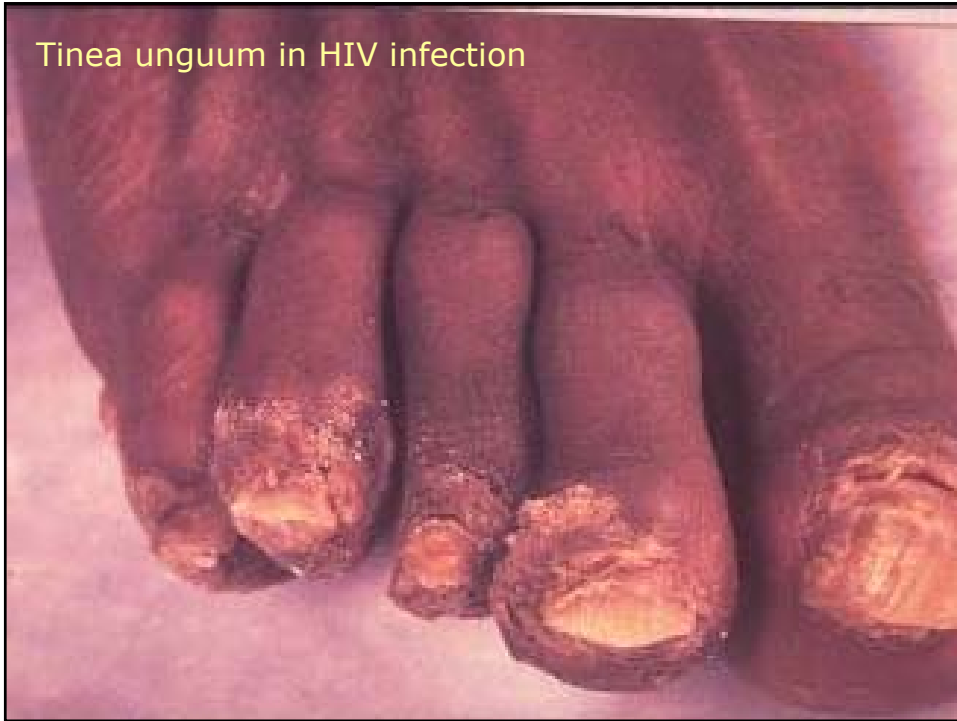

Tinea pedis (athletes' foot)

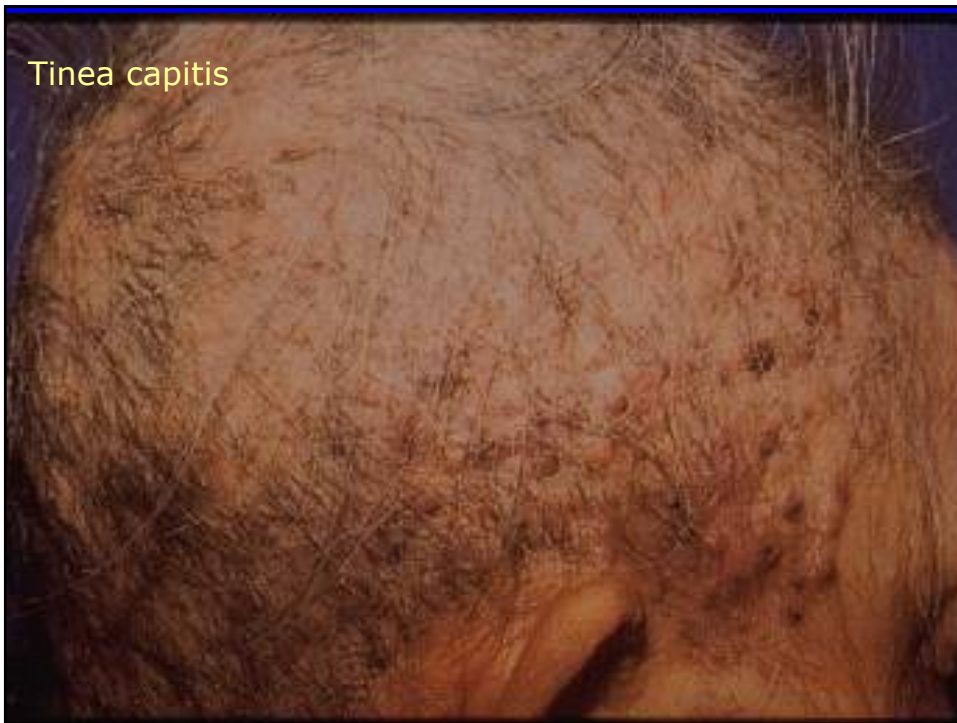





Tinea unguum in HIV infection



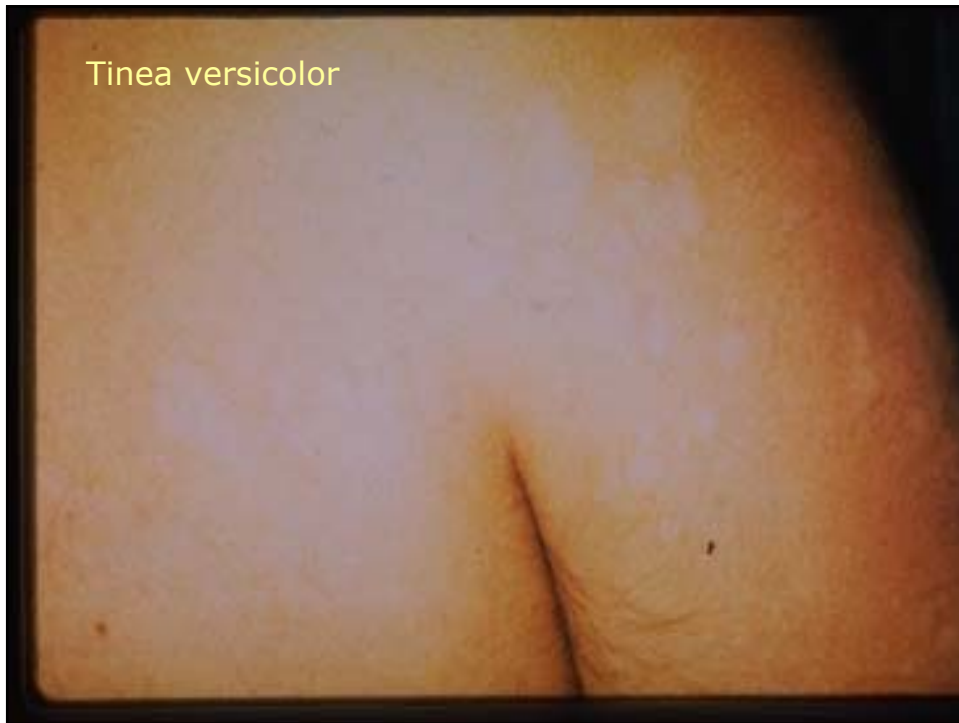Tinea capitis



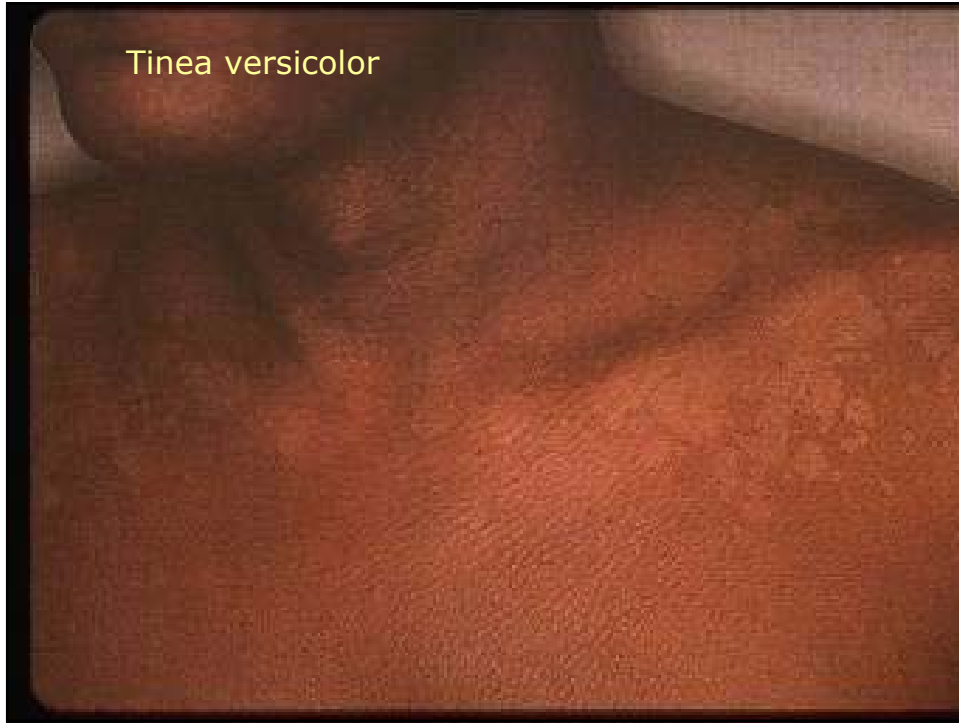Tinea capitis under Woods' lamp (UV light)



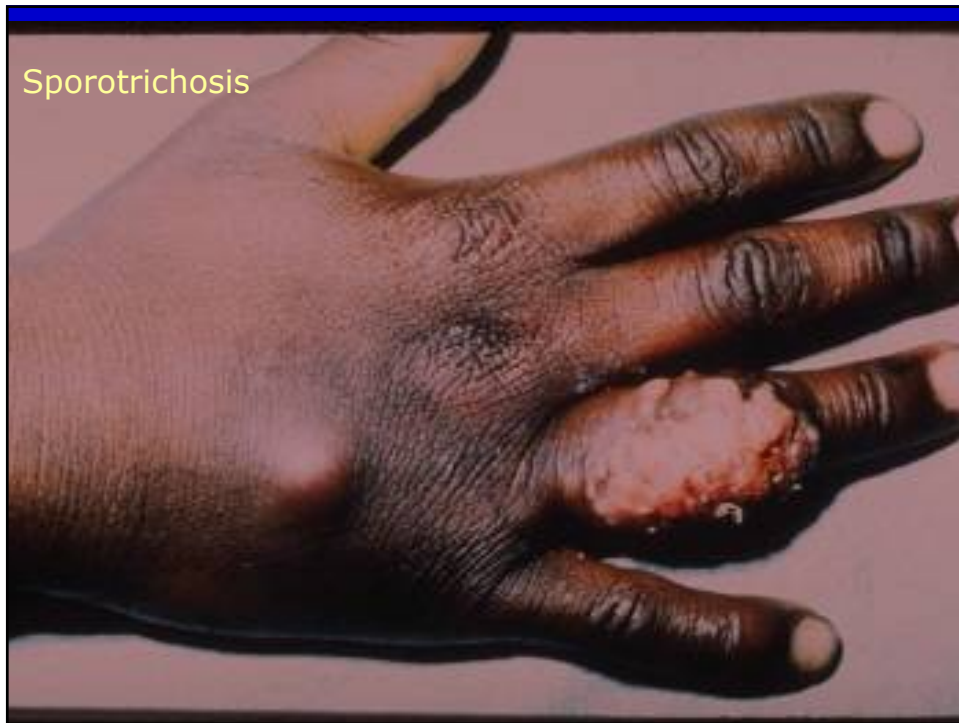Tinea versicolor



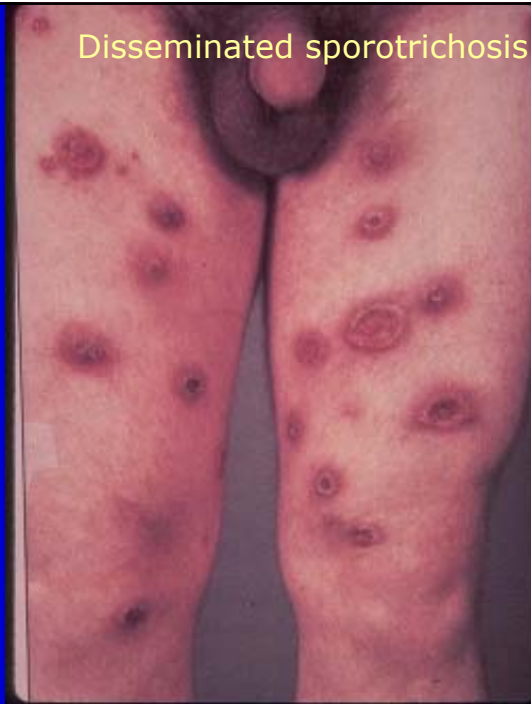Tinea versicolor



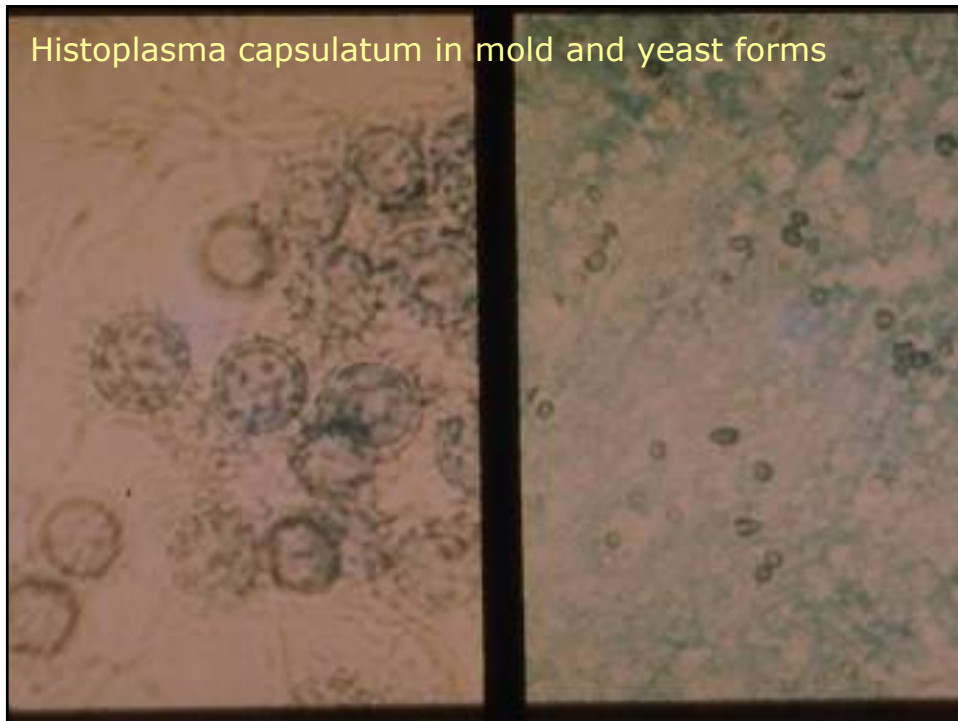
Sporotrichosis



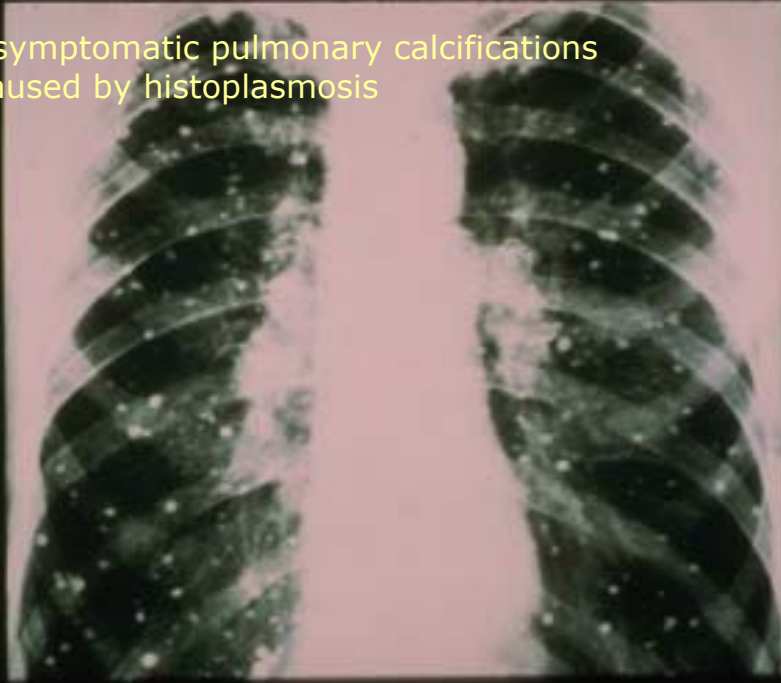Disseminated sporotrichosis in AIDS



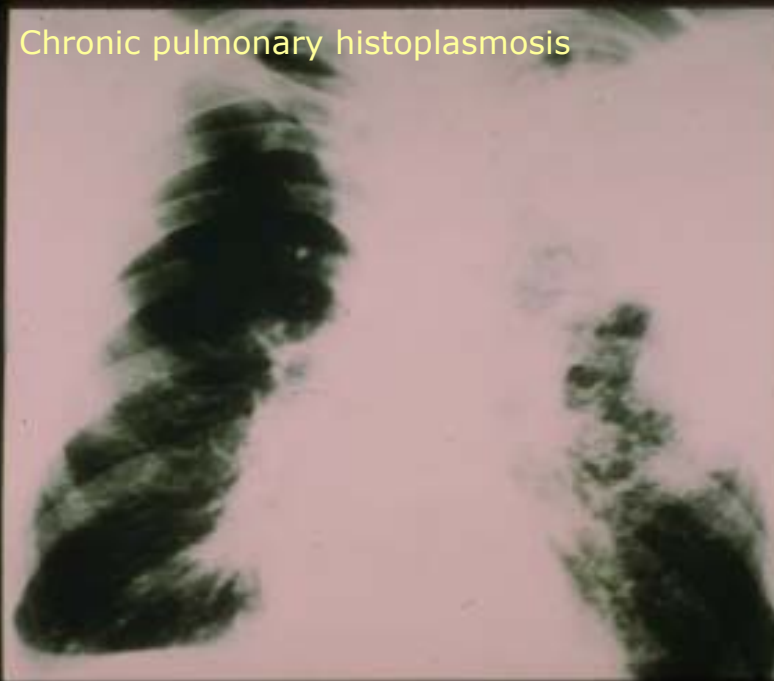Histoplasma capsulatum in mold and yeast forms



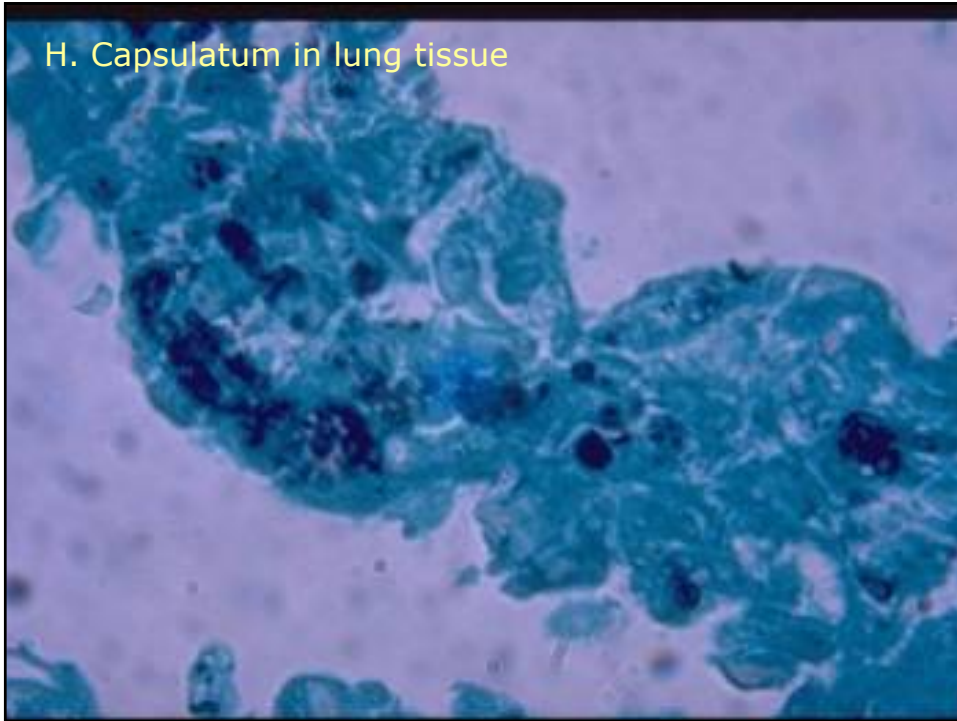
Asymptomatic pulmonary calcifications
caused by histoplasmosis



Chronic pulmonary histoplasmosis



H. Capsulatum in lung tissue



H. Capsulatum in leukocyte

