

Good Morning!

- Welcome to the Micro review session
- Pick up a keypad
- Please return the keypad at the end of the session!
- Good Luck

TEST QUESTION: Who is going to be the next president of the United States of America?

- 0% 1. Sarah Palin
- 0% 2. John McCain
- 0% ☺ 3. Barak Obama
- 0% 4. Dr. Garrett
- 0% 5. Dr. Lowy
- 0% 6. Since when is this a history course?



Channel Setting Instructions for *ResponseCard RF*

1. Press and release the "GO" button.
2. While the light is flashing red and green, enter the 2 digit channel code (channel 21 = 21).
3. After the second digit is entered, Press and release the "GO" button.
4. Press and release the "1/A" button. The light should flash yellow to confirm.

Team Scores

100 Team 4 – Dr. Natalie Neu

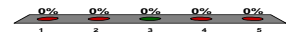
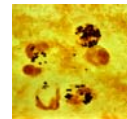
Please select a Team.

- 0% 1. Team 1 – Dr. Ellen Morrison
- 0% 2. Team 2 – Dr. Michael Yin
- 0% 3. Team 3 – Dr. Frank Lowy
- 0% 4. Team 4 – Dr. Natalie Neu
- 0% 5. Team 5 – Dr. Alice Prince
- 0% 6. Team 6 – Dr. Scott Hammer/Barbara Taylor
- 0% 7. Team 7 – Dr. Rachel Gordon
- 0% 8. Team 8 – Dr. Magda Sobieszczyk
- 0% 9. Team 9 – Dental Students

A 43-year old insulin requiring diabetic has a history of recurrent skin abscesses. He presents now with an infected joint. The Gram stain of his fluid is shown. Which of the following statements concerning his infection is correct?

10

1. A vaccination might have prevented this infection
2. Alpha toxin is responsible for the predilection of this bacteria for bones and joints
3. ✓ He was likely infected by the strain with which he was nasally colonized
4. The most important cell involved in host defense is the macrophage
5. He will develop lifelong immunity following treatment of this infection



A newly recognized infectious disease has been discovered. The pathogen cannot be cultured on conventional (or unconventional) media. On histopathological examination bacteria are however visible in the involved tissue. Which of the following approaches is most likely to help identify and characterize these new microorganisms?

10

0% 1. Gram stain of the involved tissue

0% ★ 2. 16S ribosomal analysis by PCR

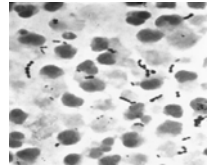
0% 3. Biochemical profile using the Microscan

0% 4. Serological screen of the patient's sera

0% 5. Pulsed field gel electrophoresis

The Gram stain below was isolated from an oropharyngeal abscess that complicated an episode of severe pharyngitis in a 7-year old boy. Which of the following statements concerning the pharyngitis is correct?

10



1. The most common nonsuppurative complication of this infection is glomerulonephritis

2. The organism responsible for this infection is often penicillin resistant

3. The organism causing this infection is both catalase and coagulase positive

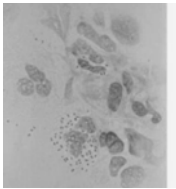
4. This organism is primarily spread by fomites

★ 5. Antibody directed against the M protein is strain specific

0% 0% 0% 0% 0%

The CSF Gram stain below was obtained from a 17-year old boy admitted to the hospital with nausea, vomiting and headache. Which of the following statements concerning his infection is correct?

10



1. Patients sitting in the ER when he was there should receive prophylaxis

2. Teichoic acid in the cell wall is primarily responsible for the host inflammatory response

3. No vaccination is available for this particular species

4. Penicillin can be used for treatment of and prophylaxis against this agent

★ 5. Transmission of this agent occurs primarily by respiratory secretions

0% 0% 0% 0% 0%

Team Scores

200 Team 4 – Dr. Natalie Neu

100 Team 2 – Dr. Michael Yin

A vaccine to prevent *Neisseria gonorrhoeae* infections has proved difficult to develop for which of the following reasons?

10

0% 1. The pilin proteins are relatively nonimmunogenic

0% 2. There is a significant risk that antibodies to pilin proteins will cross-react with cervical tissue and cause damage


0% 😊 3. The *Neisseria gonorrhoeae* chromosome contains multiple copies of the pilin genes which allows antigenic variation

0% 4. New pilin genes are acquired from *N. meningitidis* because both species are naturally competent and colonize the same sites

0% 5. Antibodies directed against pilin proteins are not neutralizing and therefore not protective

A forest ranger who has been working on the preservation of a beaver dam develops a nodule on his cheek that fails to respond to antibiotics. A biopsy grows the organism illustrated below. This is an example of which of the following pathogens?

10



1. Aspergillus fumigatus

★ 2. Blastomyces dermatitidis

3. Cryptococcus neoformans

4. Histoplasma capsulatum

5. Coccidioides immitis

0% 0% 0% 0% 0%

A 5 year old boy is bitten by a tick in Tennessee. A week later he develops flu-like symptoms and then develops a rash that involves the palms and soles. What is the most likely etiologic agent?

- 0% 1. *Treponema pallidum*
- 0% 2. *Rickettsia akari*
- 0% ★ 3. *Rickettsia rickettsii*
- 0% 4. *Borrelia recurrentis*
- 0% 5. *Borrelia burgdorferi*

10

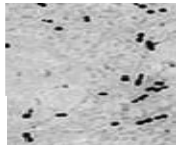
A 63-year-old man undergoes aortic valve replacement. Five days following surgery he develops fever and a new aortic valve insufficiency murmur. Blood cultures drawn at the time of his fever are positive. Which of the following pathogens is the most likely cause of this infection?

- 0% 1. *Escherichia coli*
- 0% 2. *Pseudomonas aeruginosa*
- 0% ★ 3. *Staphylococcus epidermidis*
- 0% 4. Viridans streptococcus
- 0% 5. *Enterococcus faecalis*

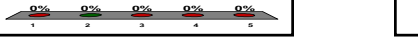10

A 77-year old man develops a fever with a productive cough and right-sided pleuritic chest pain. The Gram stain is shown. A chest X-ray reveals a lobar infiltrate. Which of the following statements concerning his infection is correct?

- 1. The peak incidence of this infection is in the 6 month to 7 year age group
- 2. The early mortality from this infection is not prevented by the administration of antibiotics
- 3. Infection usually results from hematogenous dissemination from another infected site
- 4. The organism is identified in the laboratory by its susceptibility to the bacitracin disk
- 5. The polysaccharide capsule causes the inflammation associated with this infection



10



Team Scores

- 300 Team 2 – Dr. Michael Yin
- 266.67 Team 4 – Dr. Natalie Neu
- 100 Team 6 – Dr. Scott Hammer/Barbara Taylor

A 29-year old HIV-infected male presents with shortness of breath and a diffuse interstitial infiltrate. You suspect that he has pneumocystis pneumonia and institute empiric therapy with an antibiotic that is a fixed combination of 2 drugs. What is the mechanism of action of the likely agent with which you choose to treat this infection?

- 0% 1. Blocks DNA synthesis
- 0% 2. Inhibits protein synthesis
- 0% ☺ 3. Inhibits folic acid synthesis
- 0% 4. Interferes with cell wall synthesis
- 0% 5. Disrupts the cytoplasmic membrane

10

A 7 year old girl develops bloody diarrhea followed by the onset of the hemolytic uremic syndrome. The infection followed ingestion of unpasteurized apple juice. Which of the following statements concerning the pathogen responsible for this illness is correct?

- 0% 1. The toxin elaborated by this pathogen is an example of an enterotoxin
- 0% 2. The toxin elaborated by this pathogen causes the accumulation of cyclic AMP
- 0% 3. A superantigen elaborated by the pathogen causes the hemolytic uremic syndrome
- 0% 4. The hemolytic uremic syndrome occurs more frequently in adults than children
- 0% ☹ 5. The Shiga toxin elaborated by this pathogen interferes with protein synthesis

10

A 75 year old man is diagnosed with *S. aureus* endocarditis. His isolate is resistant to penicillin and methicillin. The appropriate choice for treatment of his infection is which of the following antibiotics?

10

- 0% 1. A third generation cephalosporin
- 0% 2. Erythromycin (macrolide)
- 0% 3. Trimethoprim-Sulfamethoxazole
- 0% ★ 4. Vancomycin
- 0% 5. An aminoglycoside

A 48-year old paraplegic with an indwelling Foley (urinary bladder) catheter develops a recurrent UTI caused by a quinolone-resistant klebsiella. He has a history of renal disease and is penicillin allergic (hives!). Which of the following antibiotics would be a good choice to treat this infection?

- 0% 1. Vancomycin (a glycopeptide)
- 0% ☹️ 2. Aztreonam (monobactam)
- 0% 3. Gentamicin (an aminoglycoside)
- 0% 4. Ampicillin (a penicillin)
- 0% 5. Erythromycin (a macrolide)



A scientist identifies a new virulence determinant. He believes that it is transferred between species by conjugation. Which of the following would he need to demonstrate to prove this hypothesis?

- 0% 1. That a temperate phage must be present
- 0% ★ 2. That cell to cell contact is necessary
- 0% 3. That the recipient strain must be naturally competent
- 0% 4. That transfer is prevented by treatment with DNase
- 0% 5. That a single point mutation occurred



Team Scores

- 300 Team 2 – Dr. Michael Yin
- 300 Team 4 – Dr. Natalie Neu
- 300 Team 6 – Dr. Scott Hammer/Barbara Taylor

A 34 year old HIV infected male is admitted to your service with cough and upper lobe pulmonary infiltrates with cavities. His sputum acid fast stain is positive. Which of the following statements regarding his illness is correct?

- 0% ★ 1. This presentation would be most consistent with reactivation of an old focus of infection.
- 0% 2. The PPD (tuberculin) skin test is very helpful in making the diagnosis of this infection acutely.
- 0% 3. The chest x-ray appearance of this disease in HIV-infected persons always appears the same as in non-HIV infected persons.
- 0% 4. Pathogenesis of this infection involves aspiration of the patient's own normal oral flora.
- 0% 5. The organism causing his illness is a facultative anaerobe.



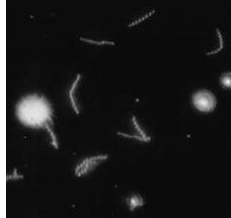A 44-year old man hospitalized for cholecystitis develops a vancomycin-resistant enterococcal infection following treatment with a cephalosporin. The mechanism of resistance for this isolate is an example of which of the following?

- 0% 1. Enzymatic breakdown of vancomycin
- 0% 2. Porin mutation preventing penetration of vancomycin to its bacterial target
- 0% ★ 3. Modification of the vancomycin target on the bacteria
- 0% 4. Mobilization of an efflux pump that removes vancomycin
- 0% 5. Insertion into cytoplasmic membrane and subsequent loss of potassium



A 21 year old sexually active male develops a painless ulcer on the shaft of his penis. A scraping of this lesion reveals the image below. Based on this information you would treat him with an antibiotic with which of the following mechanisms of action?

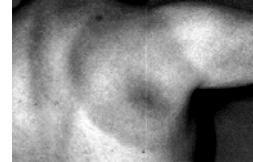- 0% 😊 1. Interferes with cell wall synthesis
- 0% 2. DNA gyrase inhibitor
- 0% 3. Inhibits protein synthesis
- 0% 4. Interferes with folic acid synthesis
- 0% 5. Damages bacterial cytoplasmic membranes



10

A 37-year old avid gardener develops the accompanying rash. Six weeks later he develops a left-sided facial palsy (Bell's palsy). Which of the following pathogens is responsible for his illness?

- 0% 1. *Rickettsia rickettsii*
- 0% 2. *Rickettsia akari*
- 0% 3. *Ehrlichia (Anaplasma phagocytophilum)*
- 0% 4. *Chlamydia psittaci*
- 0% 😊 5. *Borrelia burgdorferi*



10

A five month old infant is brought to the ER with paroxysmal coughing. The father tells you that during these episodes the baby turns "blue". The laboratory exam reveals an elevated WBC count with a marked lymphocytosis. The likely diagnosis is which of the following?

- 0% 1. *Legionella pneumophila*
- 0% 2. *Chlamydia trachomatis*
- 0% 3. *Streptococcus pneumoniae*
- 0% 4. *Mycoplasma pneumoniae*
- 0% ☆ 5. *Bordetella pertussis*

10

Team Scores

- 366.67 Team 4 – Dr. Natalie Neu
- 300 Team 2 – Dr. Michael Yin
- 300 Team 6 – Dr. Scott Hammer/Barbara Taylor

A 21-year old sexually active female develops a new urinary tract infection. This is the third infection that she has had in the past two years. There is no history of anatomic abnormalities of her genitourinary system. The most likely pathogen responsible for these infections is which of the following bacterial species?

- 0% 1. *Staphylococcus saprophyticus*
- 0% 2. *Klebsiella pneumoniae*
- 0% 😊 3. *Escherichia coli*
- 0% 4. *Pseudomonas aeruginosa*
- 0% 5. *Enterococcus faecalis*



A 33 year old female is empirically treated for neutropenic (low white count) fever with a third generation cephalosporin. She improves on therapy, however five days later she has a new fever and her blood cultures are positive. Which of the following bacterial pathogens should you consider in deciding on your new empiric therapy?

- 0% 1. *Hemophilus influenzae*
- 0% ✓ 2. *Enterococcus faecalis*
- 0% 3. *Escherichia coli*
- 0% 4. *Helicobacter pylori*
- 0% 5. *Viridans streptococci*



A second year medical student decides that she needs a vacation after just passing her MID course. She goes to Cancun with friends. Three days into her stay she develops explosive, watery diarrhea. She has no fever and is otherwise fine. Which of the following statements concerning her illness is true?

- 0% 1. Histologically you would expect to see erosions in her large bowel
- 0% 2. The pathogen responsible for this infection spreads from cell to cell by mobilizing intracellular actin
- 0% 3. Only a relatively small number of organisms (e.g., 10-100) are generally needed to cause infection
- 0% ☺ 4. Her symptoms result from the mobilization of water out of cells by a toxin that functions in a manner similar to the cholera toxin
- 0% 5. Examination of her stool is likely to reveal numerous white blood cells



A 30-year-old medical resident tries some home canned mushrooms brought to her by a clinic patient. She develops difficulty speaking, followed by a descending paralysis. The toxin mechanism responsible for this is which of the following?

- 0% 1. Toxin causes illness by directly stimulating neural receptors and also stimulating peristalsis
- 0% 2. Toxin binds directly to the MHC class 2 receptor and the T cell receptor releasing large quantities of cytokines
- 0% ➔ 3. Toxin binds to the neuromuscular junction and prevents acetylcholine release
- 0% 4. Toxin blocks the postsynaptic inhibition of spinal motor reflexes
- 0% 5. Toxin binds a GTP binding protein that results in the accumulation of cyclic AMP



Much to everyone's surprise the medical student grows out a Gram negative rod from her stool. It is a nonlactose fermenter that is also oxidase negative and H₂S positive. The likely pathogen is which of the following?

- 0% 1. *Escherichia coli*
- 0% 2. *Pseudomonas aeruginosa*
- 0% ✓ 3. *Salmonella typhimurium*
- 0% 4. *Klebsiella pneumoniae*
- 0% 5. *Clostridium difficile*



Which of the following bacterial components or products is unique to Gram negative bacteria?

- 0% 1. Spores
- 0% 2. Mitochondria
- 0% 3. Capsules
- 0% ☺ 4. Porins
- 0% 5. Biofilms



A two day old neonate develops a stiff neck and a fever. He has a lumbar puncture that reveals a high CSF protein, a low CSF glucose and Gram positive cocci in chains. Biochemical tests reveal that the organism is catalase negative, optochin and bacitracin disk negative. The organism is likely to be which of the following?

- 0% 1. Group A streptococcus (*S. pyogenes*)
- 0% 2. Viridans streptococcus
- 0% 3. *Streptococcus pneumoniae*
- 0% ☆ 4. Group B streptococcus (*S. agalactiae*)
- 0% 5. *Enterococcus faecalis*

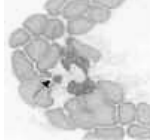


Team Scores

600 Team 2 – Dr. Michael Yin
 500 Team 6 – Dr. Scott Hammer/Barbara Taylor
 433.33 Team 4 – Dr. Natalie Neu

The following is found on your father-in-law's peripheral smear after he presents with 'the flu' in August. He has low platelets and a low white count. Assuming you wanted to recommend effective treatment, what is the mechanism of action of the preferred antibiotic for this infection?

- 0% 1. Interferes with DNA synthesis
- 0% 2. Interferes with cell wall synthesis
- 0% 3. Forms free radicals that damage bacterial DNA
- 0% 4. Disrupts the bacterial cell membrane
- 0% ☺5. Interferes with protein synthesis



Fast forward: you are now a doctor. A 27-year old woman (your friend) calls you in the middle of the night because she has dysuria and urinary frequency. She begs you to call her in a prescription, which you do. A week later she is in the intensive care unit with Stevens Johnson Syndrome. Which antibiotic is most likely responsible?

- 0% 1. Linezolid
- 0% 2. Tetracycline
- 0% 3. Erythromycin
- 0% ★4. Trimethoprim-sulfamethoxazole
- 0% 5. Clindamycin

10

A 53-year old alcoholic is admitted with nausea, vomiting, and abdominal pain. Temperature is 101.5 F, heart rate is 120 bpm, respirations are 25/min and BP is 130/70 mmHg. WBC is 15,000. A source of infection has not been identified. Describe his condition:

- 0% ☺1. Systemic Inflammatory Response Syndrome
- 0% 2. Sepsis
- 0% 3. Severe sepsis
- 0% 4. Septic Shock
- 0% 5. At death's door

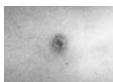


Despite the previous scenerio, you are still a doctor. Your fiance has a large (~5 cm) axillary abscess with surrounding cellulitis. This time you send him to another doctor who performs an incision and drainage and actually performs a culture. It grows methicillin-resistant *Staphylococcus aureus*. If the doctor were to prescribe an antibiotic, which of the following might be appropriate?

- 0% ☺1. Trimethoprim-sulfamethoxazole
- 0% 2. Cephalexin (first generation cephalosporin)
- 0% 3. Aztreonam (monobactam)
- 0% 4. Daptomycin (lipopeptide)
- 0% 5. quinupristin-dalfopristin (streptogramin)



A 16-year old NYC male (never traveled) presents with an eschar (see below), a vesicular/papular rash, and fever. He has poor living conditions. Which vector is responsible for his infection?



- 0% 1. Mouse
- 0% 2. Louse
- 0% ☺3. Mite
- 0% 4. Tick
- 0% 5. Deer



LAST QUESTION:

A farmer is treating his chickens with tetracycline to enhance their rate of growth. A food inspector comes by to report that the farmer's chickens are now colonized with *Escherichia coli* that are resistant to the tetracycline as well as to a number of other antibiotic families. Which of the following is the most likely explanation for this?

- 0% 1. Development of a new permeability barrier
- 0% 2. Enzymatic modification of multiple antibiotic families
- 0% 3. Alteration of the antibiotic target for multiple drug families
- 0% 4. Induction of a multidrug efflux pump
- 0% 5. Mutation of a porin protein that mediates entry of several antibiotic families



Team Scores

800	Team 2 – Dr. Michael Yin
700	Team 6 – Dr. Scott Hammer/Barbara Taylor
566.67	Team 4 – Dr. Natalie Neu