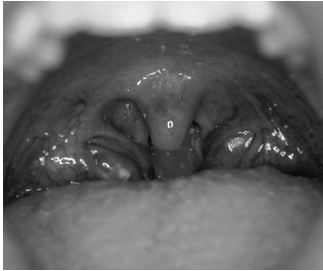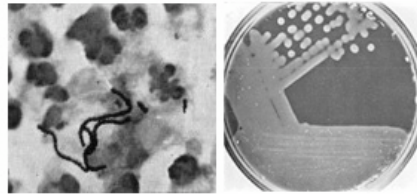


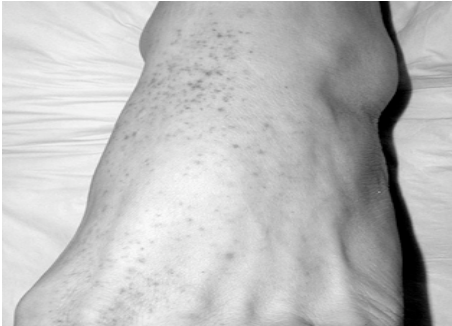Slide #1: Joey's sore throat



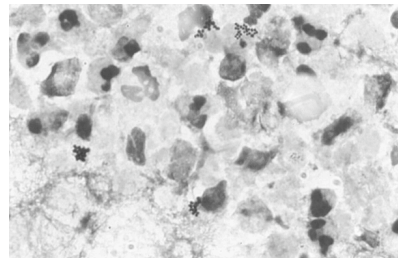
Slide #2: Joey's throat culture and Gram stain



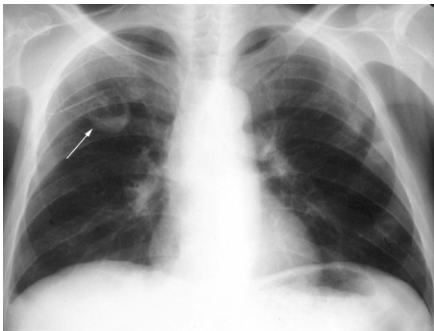
Slide #3: George W.'s rash



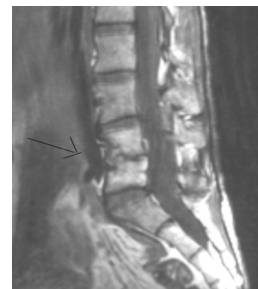Slide #4: George W's sputum Gram stain



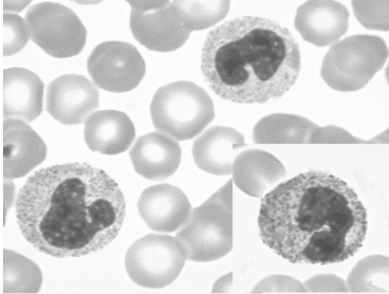
Slide #5: George W.'s chest xray



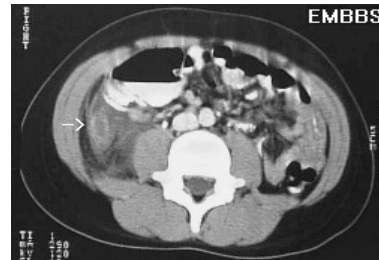Slide #6: George W.'s spine MRI



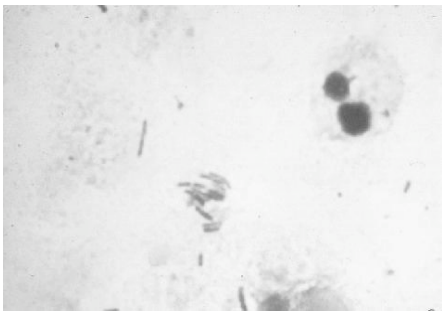
Slide #7: Sharon B.'s smear



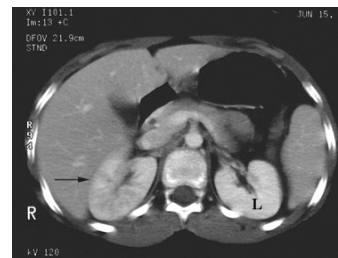Slide #8: Sharon's abdominal CT scan



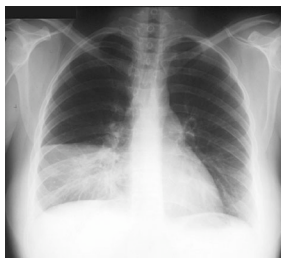Slide #9: Sally's urine Gram stain



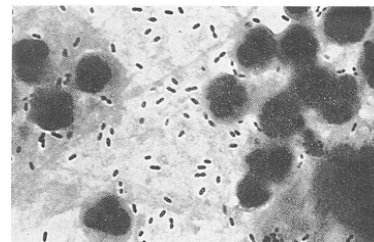
Slide #10: Sally's abdominal CT scan (Right sided pyelonephritis)



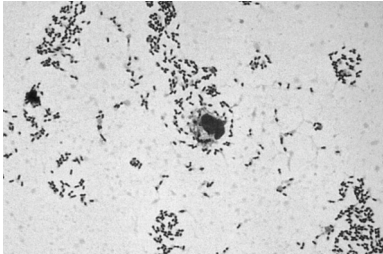
Slide #11: S.H.'s chest xray



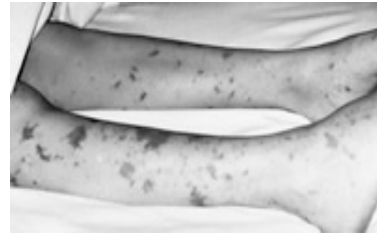Slide #12: S.H.'s sputum Gram stain



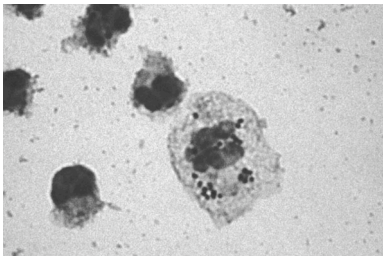
Slide #13: Mr. Seagram's CSF  
Gram stain



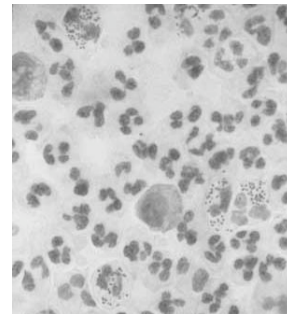
Slide #14: Junior's rash



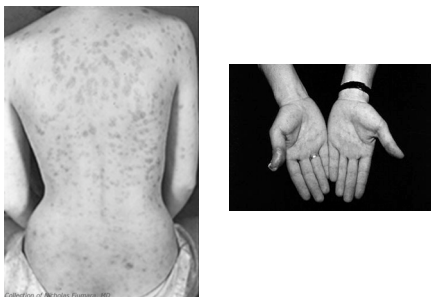
Slide #15: Junior's CSF Gram  
stain



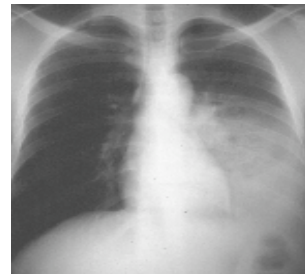STD-TBL Slide 1



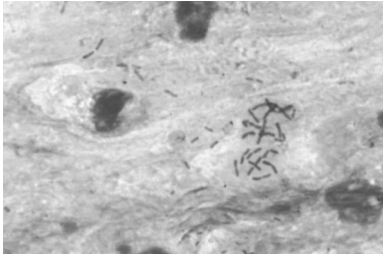
STD PBL-Slide 2



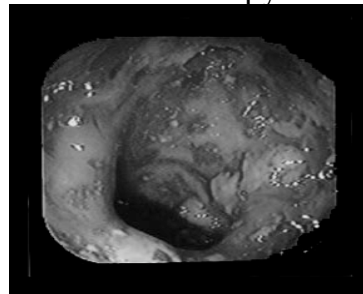
Slide #16: Mr. Gold's Chest  
X-ray



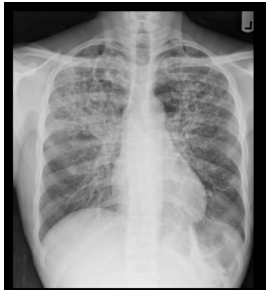Slide #17: Mr. Gold's sputum Gram stain



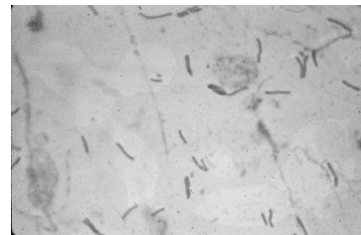
Slide #18: Mr. Gold's Colonoscopy



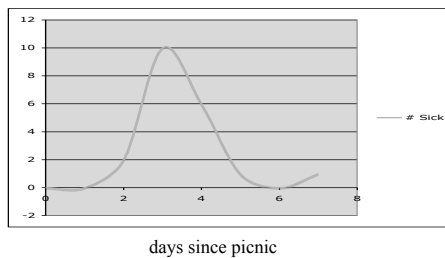
Slide #19: T.J.'s Chest X-ray



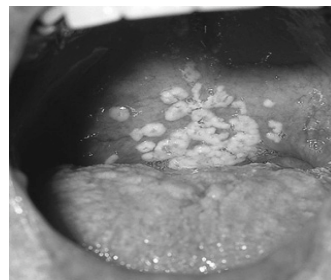
Slide #20: T.J.'s Sputum (acid fast stain)



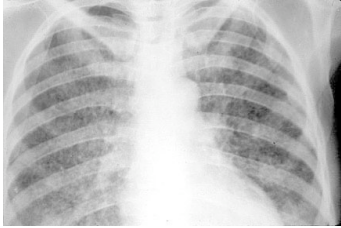
Medical School Picnic  
for faculty



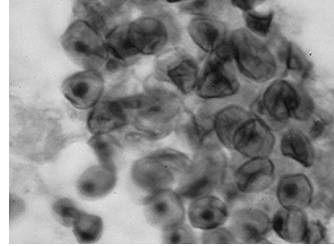
Slide #21: Gloria's Oropharynx



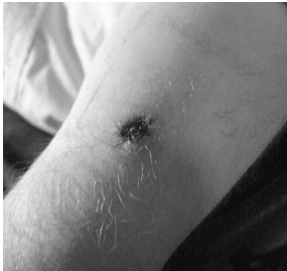Slide #22: Gloria's Chest X-ray



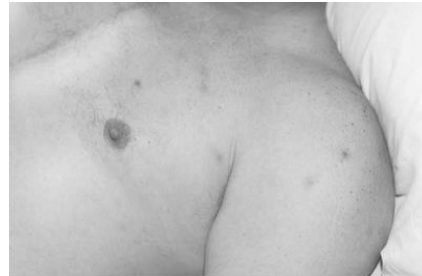Slide #23: Gloria's Bronchial Lavage (silver stain)



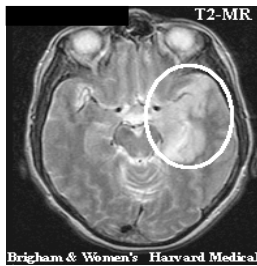Slide # 24: Initial Skin Lesion



Slide # 25: Later Onset Skin Rash



Slide #26: Maddy's MRI



Slide #27: Papules on Face

