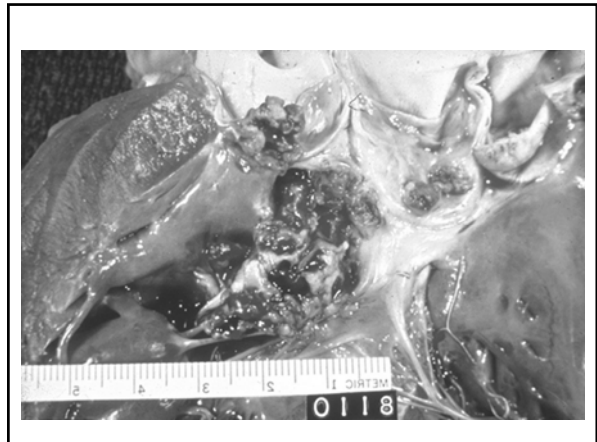
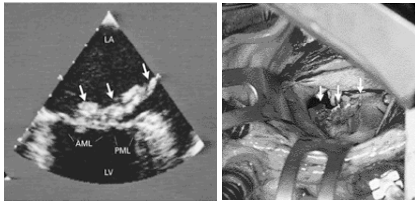


Infective Endocarditis



Infective Endocarditis

- Definitions and Historical Perspective
- Epidemiology
- Pathogenesis
- Clinical Presentation and Diagnosis
- Therapy
- Prevention

Historical Perspective



Sir William Osler

- "... A concretion larger than a pigeon's egg; contained in the left auricle." Burns, 1809
- Osler's Gulstonian lectures provided the 1st comprehensive overview of the disease
- Lewis and Grant (1923) were the first to link a transient bacteremia with deformed valves as the two predominant risk factors for infection
- The introduction of penicillin marked the first successful therapy for this otherwise fatal infection

Infective Endocarditis: Definitions

- A microbial infection of a cardiac valve or the endocardium caused by bacteria, fungi, or chlamydia
- Often categorized as acute or subacute based on the rapidity of the clinical course
 - Alternatively described by type of risk factor *e.g.*, nosocomial, prosthetic valve, intravenous drug use - associated
- Pathological findings include the presence of friable valvular vegetations containing bacteria, fibrin and inflammatory cells. There is often valvular destruction with extension to adjacent structures.
 - Embolic lesions may demonstrate similar findings

Epidemiology of Endocarditis

- Incidence the same or slightly increased
 - 1.7-6.2/100,000 depending on the population
- The age of subjects with endocarditis has increased over the past 60 years (30-40 to 47-69)
- There has been a major shift in nature of underlying valvular disorders
- There has also been a change in the microbiology of cases
 - Increasing incidence of staphylococci

Epidemiology of Endocarditis

- There has been an increasing incidence of nosocomial endocarditis - both native and prosthetic valve
- There is an increased risk of IE among injecting drug users, patients on long-term hemodialysis, patients with intravenous catheters, diabetics and HIV-infected patients
 - Among injecting drug users the incidence is as high as 150-2000/100,000 person years

Risk Factors for Specific Pathogens that Cause Infective Endocarditis

- Dental procedures, poor dental hygiene - viridans streptococci, nutritionally variant streptococci, HACEK
- Prosthetic valves
 - Early: coagulase negative staphylococci, *S. aureus*
 - Late: coagulase negative staphylococci, viridans streptococci
- Gastrointestinal or genitourinary procedures - enterococci or *S. bovis* (colon carcinoma)
- Nosocomial - *S. aureus* (including MRSA), Gram negatives, Candida species

Brouqui and Raoult, Clin Microbiol Rev, 2001

Incidence of Underlying Heart Disease in Infective Endocarditis*

	Pre-Antibiotic Era	Present
Rheumatic	++++ [^]	+
Congenital	+	+
Degenerative	+	++
Mitral valve prolapse	+	+++
Normal valves	+	++

*Incidence varies with population studied

[^]Relative incidence

Pathogenesis of Endocarditis

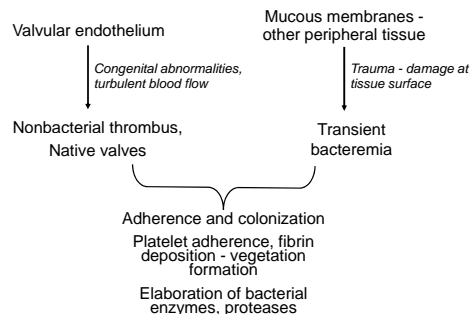
- Inoculation of bacteria colonizing a mucosal (e.g., oral mucosa) or peripheral tissue site into the bloodstream
- Transient bacteremia of a serum-resistant pathogen capable of adhering to a cardiac valvular surface
- Turbulent blood flow across the valve
- Bacterial adherence to cardiac valvular surface
- Pathogen - host tissue interaction resulting in vegetation formation and local tissue damage
 - Bacterial persistence
- Dissemination of infection to other tissue sites and elicitation of systemic findings

Microbiology of Infective Endocarditis Prospective International Cohort Study

Organisms	Percent Cases
<i>Staphylococcus aureus</i>	32
Coagulase-negative staphylococci	10
Viridans group streptococci	18
<i>Streptococcus bovis</i>	6
Other streptococci	5
<i>Enterococcus spp.</i>	11
Gram negatives (including HACEK)	4
Fungi	2
Polymicrobial	1
Culture negative	8

Fowler, et al., JAMA 2006

Pathogenesis of Infective Endocarditis



Factors Contributing to the Pathogenesis of Endocarditis

- Hemodynamics - blood flow patterns
- Bacterial properties
- Host factors

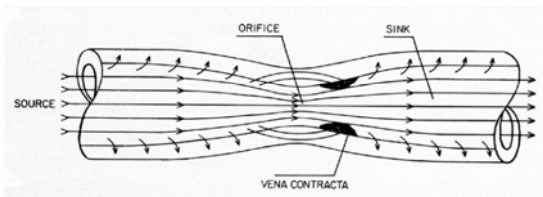
Bacteremia of Endocarditis

□ Patient 3: Colonies per cubic centimeter in blood from femoral artery and antecubital vein.

Time	Femoral artery	Antecubital vein
<i>p.m.</i>		
1:00	266	228
1:03	264	251
1:05	300	285
1:07	358	256
1:08	399	397
1:11	340	358
1:13	397	344
1:15	298	318
1:17	332	342
1:20	552	533
1:23	671	534

Beeson et al., JEM, 1945

Hemodynamics of Endocarditis

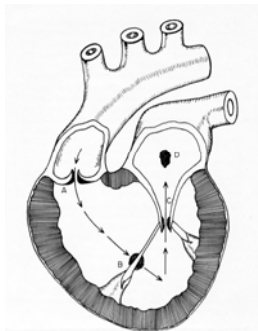


Rodbard, Circulation, 1963

Bacterial Factors Involved in the Pathogenesis of Infective Endocarditis

- Serum resistance - *i.e.* complement
 - Gram positives tend to be complement resistant
- Bacterial adhesins mediate binding to the nonbacterial thrombus and to endothelial cells: dextran, fibrinogen-binding proteins
- Invasive potential of bacteria
 - Ability to elaborate extracellular proteases
 - Capacity for metastatic seeding
- Stimulation of tissue factor activity

Hemodynamics of Endocarditis



Weinstein, Schlesinger NEJM, 1974

Host Factors Involved in the Pathogenesis of Infective Endocarditis

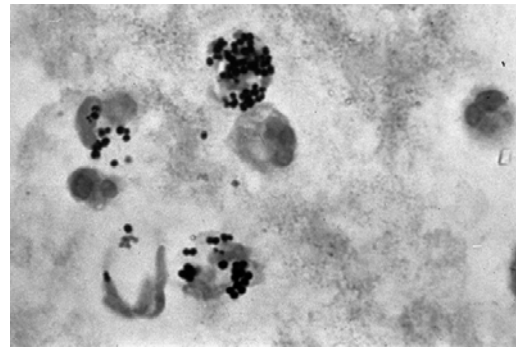
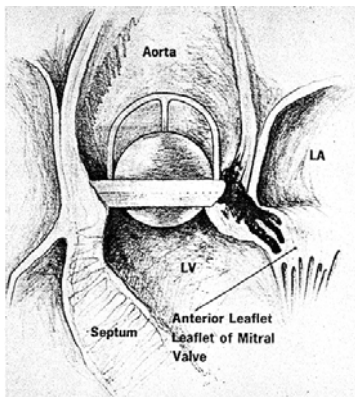
- Valvular surfaces
 - Nonbacterial thrombus forms on damaged valves
 - Direct adherence to the endovascular surface of normal valves
 - Suture line, valve surface of prosthetic valves
- Platelets dual role
 - Platelet microbicidal proteins (α -granules)
 - Bacteria induce platelet aggregation
 - Part of nonbacterial thrombus surface
- Leukocytes, complement, cytokines
 - More limited role

Immunologic Manifestations of Infective Endocarditis

- Hypergammaglobulinemia; both antigen specific and polyclonal B cell activation (e.g., rheumatoid factor)
 - May block IgG opsonic response, accelerate microvascular damage or stimulate phagocytosis
- Vasculitis
 - Circulating immune complexes
 - Hypocomplementemia
- Clinical syndromes: "Lumpy-Bumpy" glomerulonephritis with deposition of complexes plus complement, Osler's nodes

Case 1: One Sick Dude

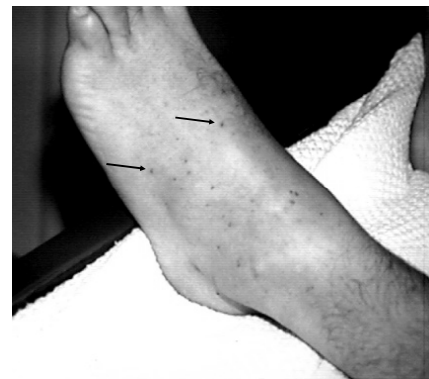A 33 year-old recreational drug user develops fever, chills and pleuritic chest pain 48h after injecting heroin. He appears acutely toxic with a temperature of 104°, rapid respirations and agitation. His sputum is purulent and bloody. His cardiac exam is unremarkable except for his sinus tachycardia. Examination of his skin reveals a petechial rash and a small soft tissue abscess at his injection site.



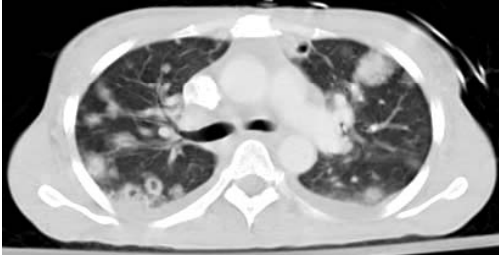
The Pathogenetic Basis for the Clinical Manifestations of Infective Endocarditis

- Valvular destruction and local intracardiac complications
- Bland or septic embolization of vegetations
- Sustained bacteremia
- Immunologic phenomena

Osler, *Gulstonian Lectures, Lancet*, 1885
Weinstein and Schlesinger *NEJM*, 1974



CT Scan of the Lung

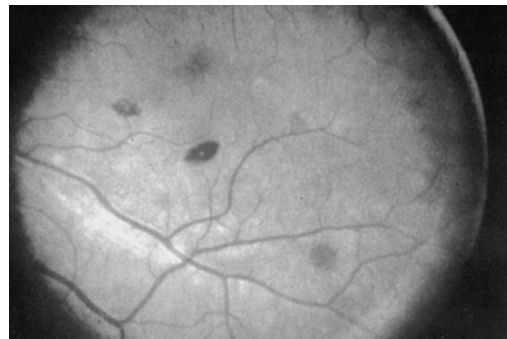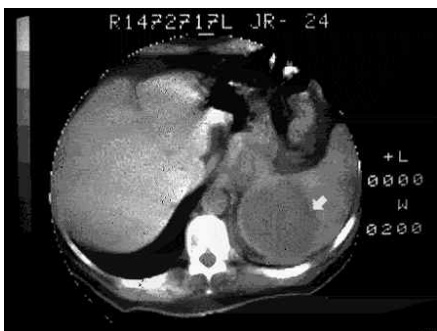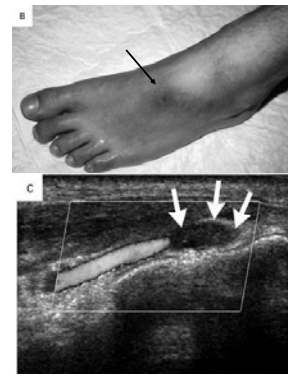


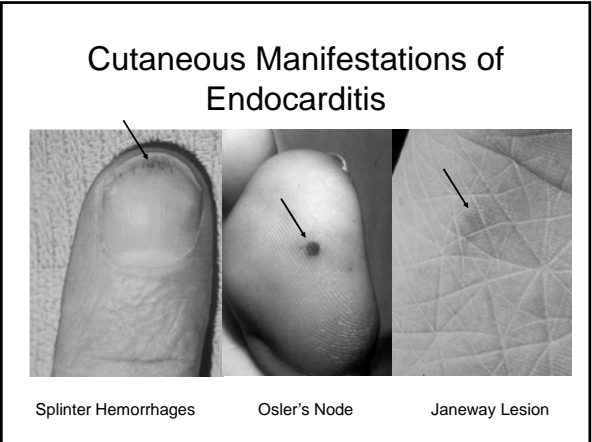
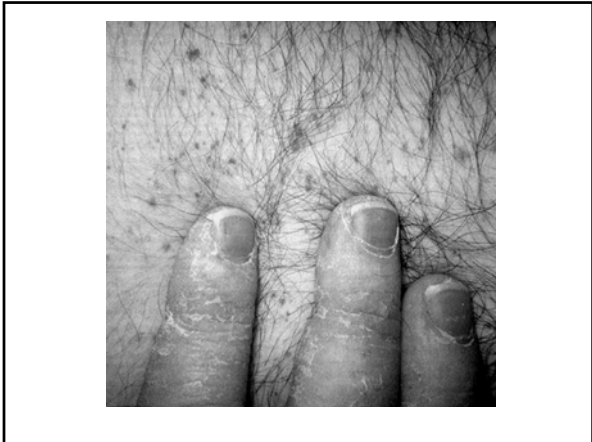The Sluggish Doc

A 65 year old female physician has noted increasing fatigue and malaise for the past 1-2 months. When she takes her temperature she is surprised to find that it is 100.6°. She also notes some new lesions on her arms and nails. She is too busy to see her own physician. What finally brings her to medical attention is the development of red, painful swelling on the dorsum of her left foot. Her physician notes Roth spots in both eyes and a loud mitral insufficiency murmur. Of note, she has a longstanding history of mitral valve prolapse.

Case 1: One Sick Dude

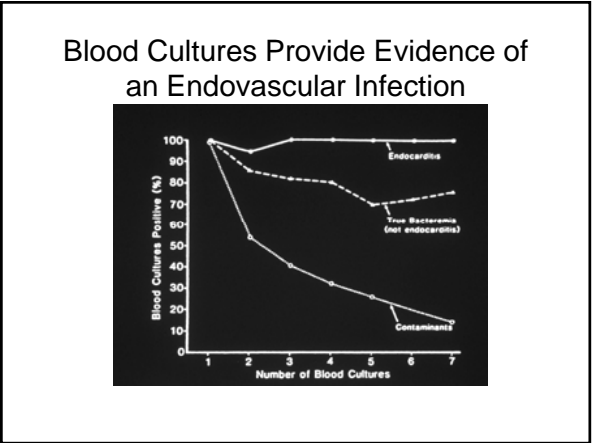
His blood cultures are positive for *S. aureus* within two days. One week into therapy he is feeling better, however he has noticed some increased left upper quadrant pain and on examination you are able to palpate his spleen. He also has developed a soft systolic murmur at his left lower sternal border that is increased with inspiration.





The Sluggish Doc

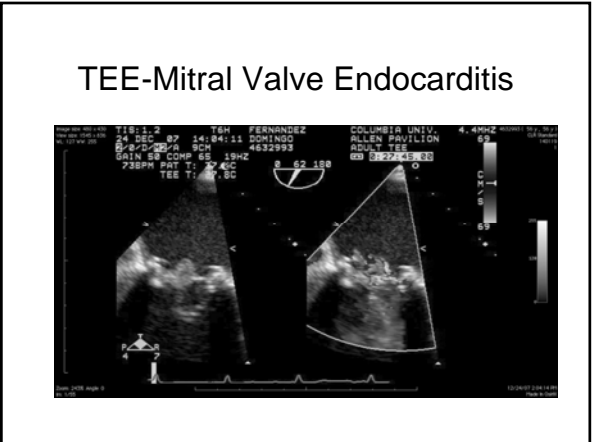
Multiple blood cultures grow viridans streptococcus. Her laboratory studies reveal anemia of chronic disease and a positive rheumatoid factor test. Despite antibiotic therapy, she develops refractory heart failure and requires mitral valve replacement

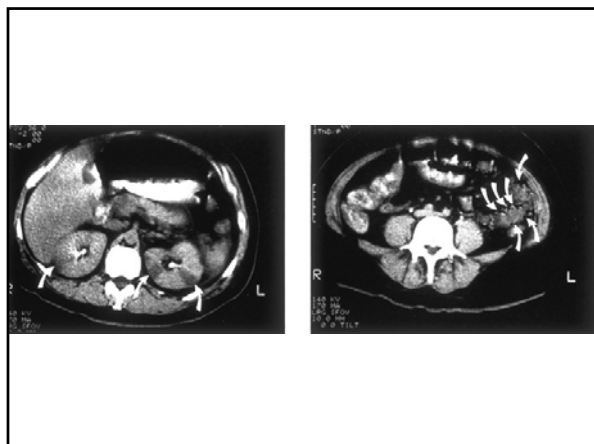


Diagnosis of Endocarditis

- History and physical - the "old fashioned way"
- Laboratory studies -
 - Microbiology - sustained positive blood cultures
 - Other studies - hematologic, rheumatologic, renal
- Echocardiography
 - Transesophageal echocardiography

AHA Diagnosis and Management of IE and Its Complications, Circulation 98:2936, 98

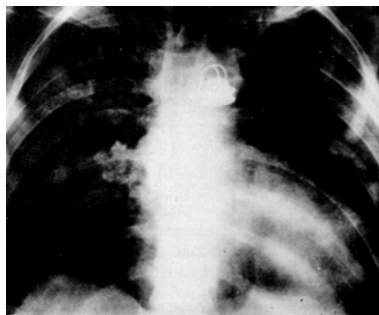




Mimics of Infective Endocarditis

- Atrial myxoma
- Marantic endocarditis
- Left atrial thrombus
- Acute rheumatic fever with carditis
- Collagen vascular disease (SLE)
- Neoplasms (carcinoid)

What's Wrong with this Picture?



Principles of Therapy

- Bactericidal antibiotics must be used
- Prolonged therapy is necessary (weeks)
- Treatment is best started after multiple sets of blood cultures have been taken.
- Urgency in the initiation of therapy is required for acute but not subacute endocarditis.
- Synergistic combinations of antibiotics are used when available.

Duke Criteria for the Diagnosis of Endocarditis

- Definite:
 - Pathologic criteria are histological or culture confirmation of vegetation or emboli.
 - Clinical criteria are 2 major, 1 major plus 3 minor or 5 minor criteria (e.g. positive blood cultures or echocardiogram, new regurgitant murmur)
- Possible:
 - **1 major, 1 minor; or 3 minor criteria**
- Rejected:
 - Alternate diagnosis, resolution of infection with brief therapy, no pathologic evidence of endocarditis

Durack et al. AJM, 1994; Li et al. Clin Infect Dis, 2000

Antimicrobial Prophylaxis of Endocarditis – Potential Mechanisms

- Bactericidal activity
- Reduce bacterial adherence
- Reduce bacterial density in the wound at the time of surgery (for prosthetic valves)

Problems with Prophylaxis for Infective Endocarditis (IE)

- Most cases of IE not preventable with prophylaxis (absent history of a lesion)
- No controlled studies of efficacy
- Most cases not associated with procedure warranting prophylaxis
- Dental treatment **not** a risk factor in population - based, case-control study (*Strom et al.*, AIM '98)
 - Prosthetic valves, antecedent endocarditis major risk factors

What Do I Need to Know?

- What are the major epidemiologic features of endocarditis and how have they changed?
- Which bacteria are associated with which types of exposure in the development of endocarditis?
- What is the pathogenesis of endocarditis and what is its correlation with the different clinical presentations?
- How is endocarditis diagnosed?
- What are the basic principles of therapy and prophylaxis?

Prevention of Infective Endocarditis

- High risk**
 - Prosthetic valve
 - Complex congenital heart disease
 - Previous endocarditis
 - Cardiac transplantation with valvulopathy
- Moderate risk
 - Acquired valvular dysfunction (e.g. rheumatic valve)
 - Mitral valve prolapse with regurgitation
- Negligible risk
 - Mitral valve prolapse without regurgitation
 - Rheumatic fever without valvular dysfunction

** NB: Only group where prophylaxis is still recommended

AHA Recommendations, Circulation, 2007

Prophylaxis Recommended (or Not)!

- Dental procedures that involve manipulation of gingival tissue
- Respiratory tract, infected skin or skin structures
- Prophylaxis not recommended for gastrointestinal or genitourinary procedures

AHA Recommendations, Circulation, 2007