

Case 10

A 13-year-old boy was first admitted to the hospital with complaints of recurrent draining cervical, sub-mandibular and axillary lymph nodes due to *S. enteritidis*, *S. paratyphi*, and *S. typhi* since the age of 5 years. He was given multiple antibacterial drugs, (e.g., ciprofloxacin, cephalosporines and sulbactam ampicillin) with partial responses. Histopathological examination of a lymph node which developed in the axillary region 2 weeks after BCG vaccination did not show any features compatible with tuberculous lymphadenitis, though a granulomatous appearance was observed without caseification necrosis. Although he was not given anti-mycobacterial treatment no progression occurred and the lesion healed. His parents were cousins. The patient's sister died of disseminated BCG infection at the age of two. Physical examination revealed multiple left cervical lymph nodes of 1.5×1 cm in diameters, and microlymphadenopathies in the inguinal and axillary regions, as well as scar tissue on cervical, submandibular, pre- and post-auricular and axillary areas, due to previous infections. Routine immunological work up was normal. A *Salmonella* agglutination test was positive for group B. Peripheral blood mononuclear cells were isolated and subjected to flow cytometry using an antibody against the IL-12 receptor p40 subunit; no staining was apparent, despite obvious staining for this receptor subunit in mononuclear cells obtained from a control (**Fig. 1**).

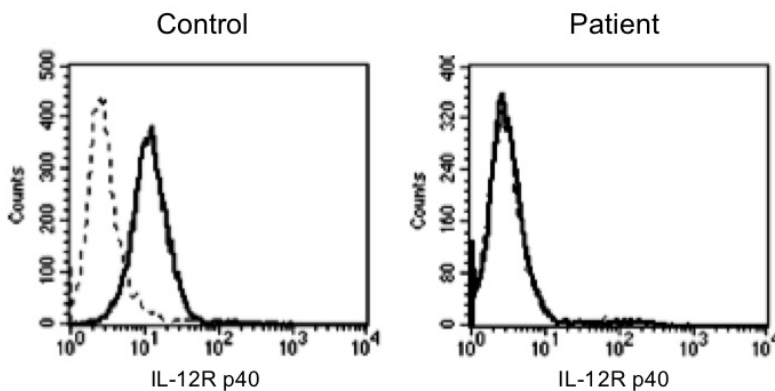


Fig. 1 Flow cytometry of blood mononuclear cells from indicated subject stained with a FITC-conjugated mAb against IL-12R p40.

Questions for Case 10

- (1) Although the clinical presentation of this patient was one of disseminated salmonellosis, given the flow cytometry results, what other infections might this patient be expected to develop? What other cytokines might this individual fail to respond to and how might this manifest itself clinically? What other immune deficiencies might be expected to present in a similar fashion?
- (2) Although deficiencies of the IL-12R p40 have been reported, there have been no reported deficiencies of IL-12 p35. Provide a plausible explanation for this observation.
- (3) Describe the initial events following the ingestion of live *S. enteritidis*. To which cells in the gut do these bacteria initially bind and how does the immune system respond to bacterial invasion.

(4) *Salmonella* is one of many microbial pathogens that have evolved strategies to evade the host immune system (in fact, this is why they are pathogenic). Other pathogens that resemble *Salmonella* in the pathways that they evade include *Toxoplasma*, *Legionella*, and *Mycobacterium tuberculosis*. Describe the events immediately following interaction of *Salmonella* with host antigen-presenting cells, such as macrophages or dendritic cells. After minutes to hours, what event normally occurs in the APC that helps insure the death of other bacteria more susceptible to killing by the host?

(5) Many cytokines have been implicated in *Salmonella* immunity. Among these are IL-1 and IL-18. How does signaling via IL-1 and IL-18 differ from classical cytokine signaling?

(6) Although humoral (antibody-mediated) immunity is important in immunity to *Salmonella*, the development of cytotoxic lymphocytes (CTL) is crucial. Why is this the case?

(7) Early in the course of a *Salmonella* infection there is a rapid local elaboration of IL-12 and IFN- γ . What are the likely cellular sources of these cytokines?