

Case 24

M.B. is a 52 year- old former advertising executive who was well until 8 years ago when she noted the onset of Raynaud's phenomenon (Fig. 1) followed by marked fatigue and puffiness of both hands with tightness of the overlying skin. A skin biopsy was obtained (Fig. 2). Over the following year the skin tightness spread to involve the entire body, and the patient found it difficult to walk because of stiffness of her ankles.

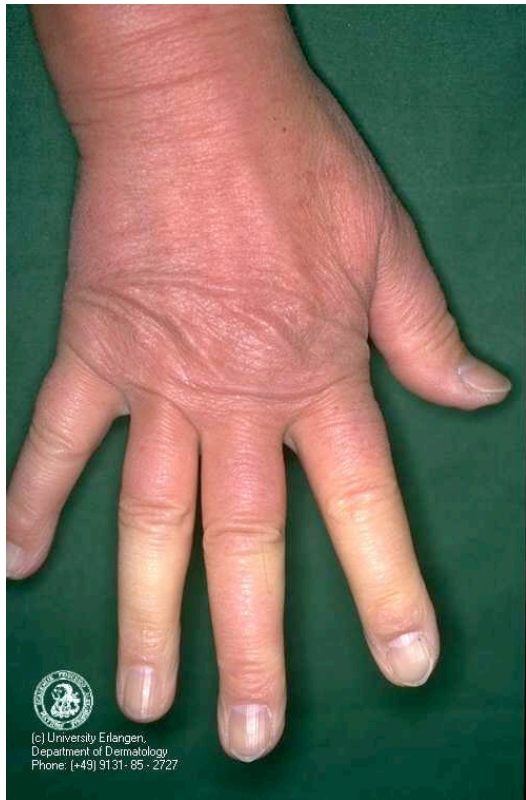

Fig. 1. Raynaud's phenomenon

Six years ago she presented to CPMC because of dysphagia with solid food but not liquids, heartburn, abdominal distention and constipation alternating with diarrhea. About the same time she first noted mild exertional dyspnea without cough, chest pain or palpitations. She denied muscle pain or weakness, rash, or fever. Physical examination was notable for taut, shiny and indurated skin over her entire body with areas of hyper- and hypo-pigmentation. She had scattered telangiectasias over the face and hands. There was no lymphadenopathy. Heart and lung exams were normal. Her abdomen was mildly distended without organomegaly, masses or tenderness. Rectal exam was normal with heme-negative stool. The patient had decreased motion of fingers, wrists, knees and ankles with shiny, tight overlying skin. Crepitations of extensor tendons of fingers and ulcerations over extensor surfaces of proximal interphalangeal joints were present. There was no onycholysis and no joint swelling. Her muscle strength was normal. Laboratory data revealed a normal CBC, ESR, serum chemistries and urinalysis. A test for anti-centromere antibodies was negative. However, a screening test for antibodies against extractable nuclear antigens (ENA) was positive; of the following extractable nuclear antigens (Sm/RNP, Sm, SSA, SSB, Scl-70, Jo-1) antibodies only to Scl-70 (a breakdown product of topoisomerase I)

were detected. Cryoglobulins were negative and serum hemolytic complement was normal. Electrocardiogram was normal. A chest x-ray revealed bibasilar fibrosis. Pulmonary function tests were normal except for a decreased diffusion capacity. Upper gastrointestinal series demonstrated diminished esophageal motility with hypotonia; normal stomach and duodenum. An evaluation for malabsorption was recommended but refused by the patient. Penicillamine 250 mg/day was added and slowly increased to 750 mg/day. Over the following year, her skin gradually became more supple except for that on her fingers. However, the Raynaud's phenomenon persisted.

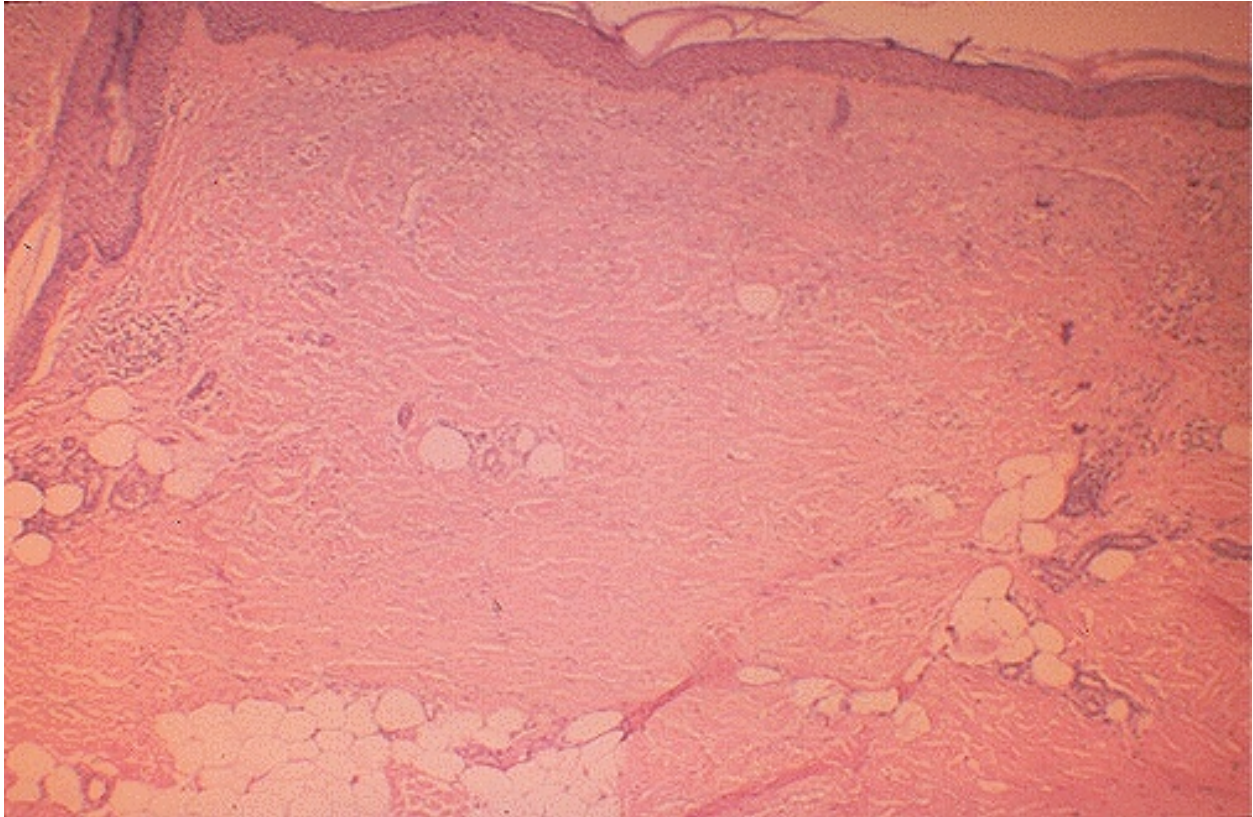


Fig. 2. At low magnification, the collagen of the dermis is increased. Chronic inflammatory cells are sparse, unlike SLE.

Over the past 6 months, she developed a productive cough with increased dyspnea but no chest pain or fever. Chest x-ray showed increased pulmonary fibrosis. Pulmonary function tests gradually deteriorated and on present exam she has bibasilar râles. Urinalysis and renal function had remained normal. However, her ANA became positive at 1/320 with a speckled pattern (Fig. 3).

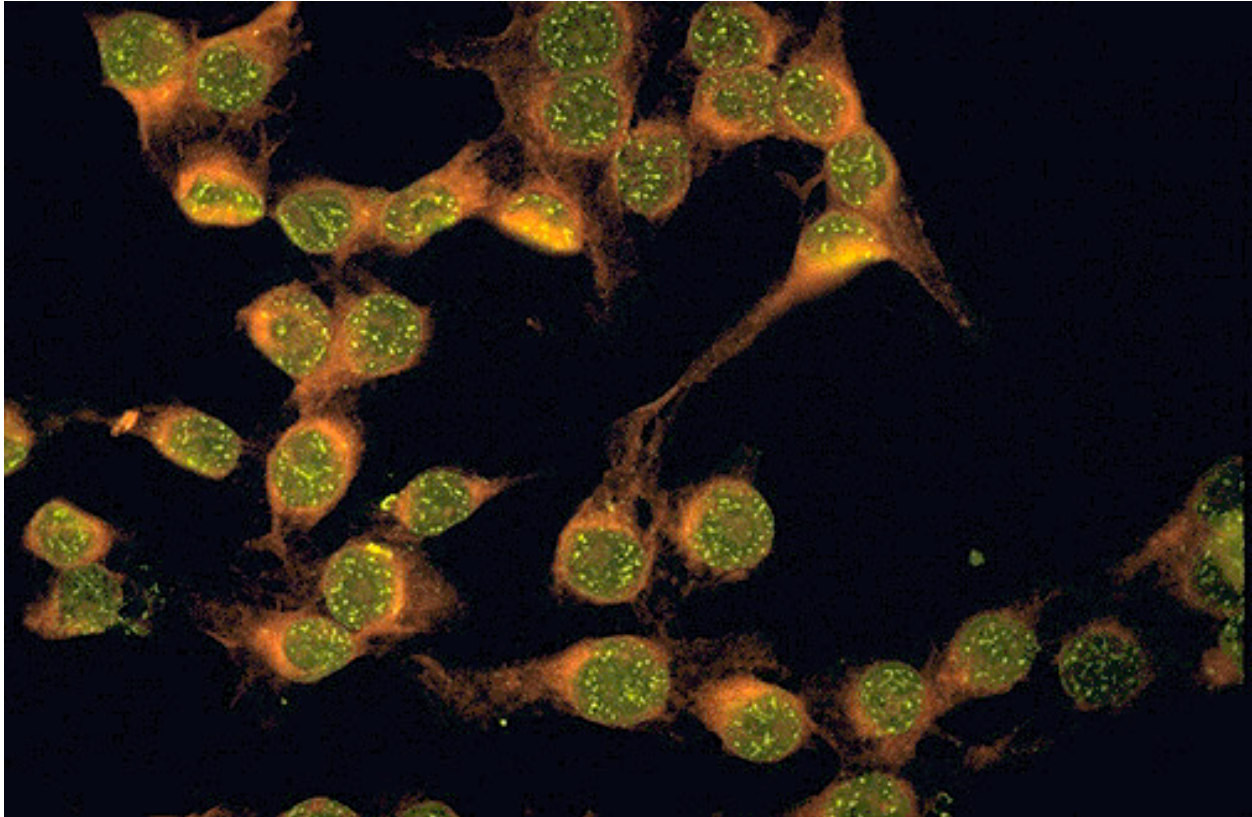


Fig. 3. This is the so-called "speckled" pattern of ANA staining which is more characteristic of the presence of autoantibodies to extractable nuclear antigens, particularly ribonucleoprotein. This pattern is not very specific.

Questions for Case 24

- (1) What is Raynaud's phenomenon? What is its prevalence in scleroderma and in the general population? What vascular abnormality is associated with this syndrome? What is sclerodactyly?
- (2) Describe the clinical features of the major subtypes of systemic sclerosis and their prognosis.
- (3) What is the clinical significance of:
 - (a) anti-centromere antibodies?
 - (b) anti-Scl-70 (topoisomerase I) antibodies?
 - (c) The patient's positive ANA?
- (4) The role of T-cells in the pathogenesis of scleroderma is controversial.. A recent study detected oligoclonal T cell expansion in the skin of patients with scleroderma. What is the potential significance of this finding in the pathogenesis of the disease?
- (5) What role do B cells play in scleroderma?

(6) Mention some therapeutic options for scleroderma.

(7) Recent experiments have suggested that lesions from patients with scleroderma have markedly reduced expression of Smad7 and enhanced accumulation of phospho-Smad2 and 3. What does this mean and how might TGF- β contribute to fibrotic diseases, in general.