

### Case 3

An 11-month-old boy from Qatar, the product of a first cousin marriage, was referred for evaluation and management of immunodeficiency, fevers, and failure to thrive. Pregnancy and delivery were uneventful, and he received routine immunizations on his first day of life. From 6 weeks of age he experienced multiple infections, including an *Escherichia coli* urinary tract infection; *Staphylococcus epidermidis* and *E. cloacae* sepsis; oral and cutaneous candidiasis (yeast infection); and severe diarrhea. Laboratory examination revealed a lymphocyte count of 150 cells/ $\mu$ l (normal for an infant is  $>3000$  cells/ $\mu$ l) and a chest X-ray that revealed absence of a thymic shadow (Fig. 1). Additional laboratory tests revealed:

- (1) Diminished numbers of cells positive for CD2, CD3, CD4, or CD8
- (2) Decreased numbers of B-cells
- (3) Abnormal phytohemagglutinin (PHA) and mixed lymphocyte responsiveness (tests of T cell function)
- (4) Decreased pokeweed mitogen (PWM)-induced T-cell dependent Ig synthesis of his peripheral lymphocytes.
- (5) Normal levels of red cell adenosine deaminase (ADA) and purine nucleoside phosphorylase
- (6) Negative HIV test

He was begun on bi-weekly doses of gamma globulin and was placed on a waiting list for a bone marrow transplant.

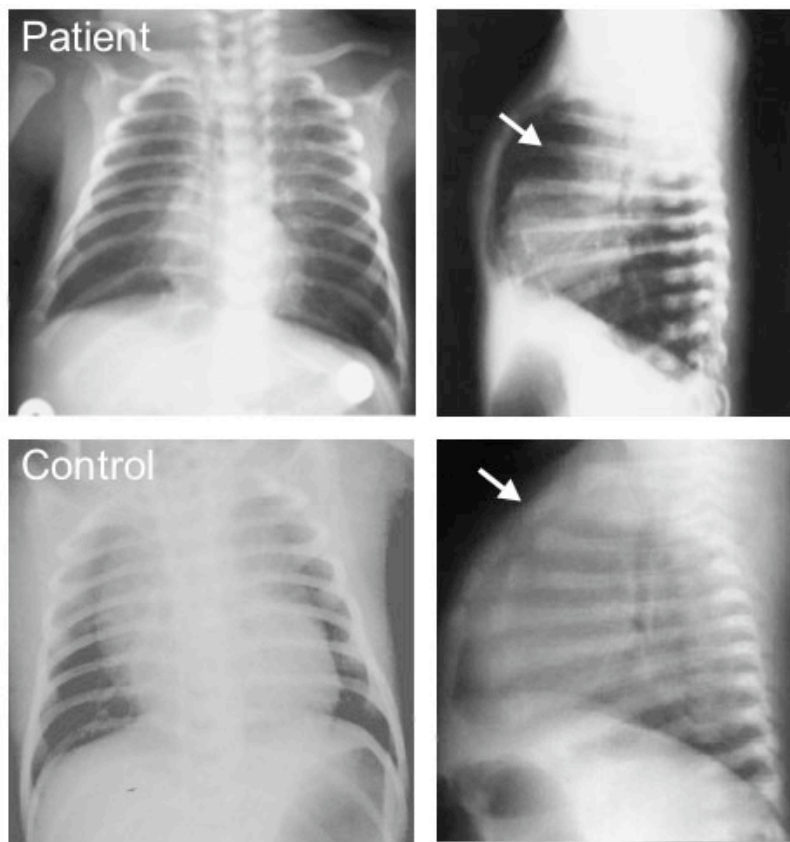


Fig. 1. Chest X-ray (AP and lateral views) of patient and normal infant control. Arrows indicate border of heart shadow in patient (*upper right panel*) and thymic shadow in control (*lower right panel*).

**Questions for Case 3**

- (1) What immunologic parameters indicate severe immunodeficiency?
- (2) What are some causes of inherited T-cell or combined T-cell/B-cell deficiencies?
- (3) The requirement for T cells in the PWM-driven induction of B cell Ig secretion is the demonstration that B cells require help for differentiation. What is the molecular basis for this help?
- (4) Describe the likely natural history of chicken pox in this child.
- (5) What types of vaccination should not be given to this child?
- (6) If this patient required blood transfusions, what special procedure should be performed on the transfused cells?