

Case 7

A 65 year-old accountant was brought to the emergency room by his wife after he collapsed on the street 20 minutes after a penicillin injection had been administered in a physician's office.

He had a past history of angina and cardiac catheterization revealed advanced atherosclerosis.¹ He had no history of allergic rhinitis (hay fever), asthma, or atopic dermatitis. He had received penicillin 4 or 5 times in the past for respiratory infections without any adverse reaction until the last time during which time he noted a rash consistent with urticaria (hives), which resolved spontaneously (Fig. 1). The day prior to admission he awoke with a sore throat and fever. On the morning of admission he was brought by his wife to his family physician. After examining him he prescribed an injection of a "penicillin." This was administered by the office nurse. The patient immediately left the office with his wife and started walking home. About 10-15 minutes later, he began to feel weak and became diaphoretic.¹ He complained of difficulty breathing and chest pain and slid to the ground. His wife hailed a passing taxi and brought him to the emergency room in a trip lasting less than 10 minutes.

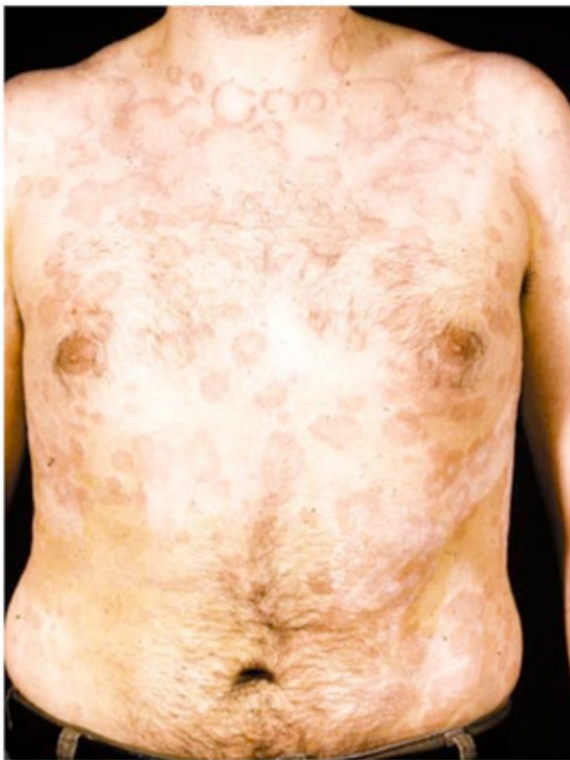

Fig. 1. Urticarial rash in patient following ingestion of penicillin.

On examination, he was ashen in appearance and had cold, clammy skin. He had a thready pulse of 160 and a systolic blood pressure of 50. Her respiration was labored and there was wheezing throughout both lung fields. The remainder of his physical examination was negative. He was immediately given a subcutaneous injection of epinephrine and two wide-bore intravenous lines were inserted to administer fluids. He also received diphenhydramine (benadryl), an antihistamine. An ENT consultant was called, but a tracheotomy was not deemed necessary (Fig.

Case 7, cont'd

2). Within 20 minutes, her blood pressure and respiration had improved and over the course of the next few hours returned to normal levels. He was given additional diphenhydramine; oral prednisone was later instituted. An ECG (electrocardiogram) revealed new T-wave inversions²

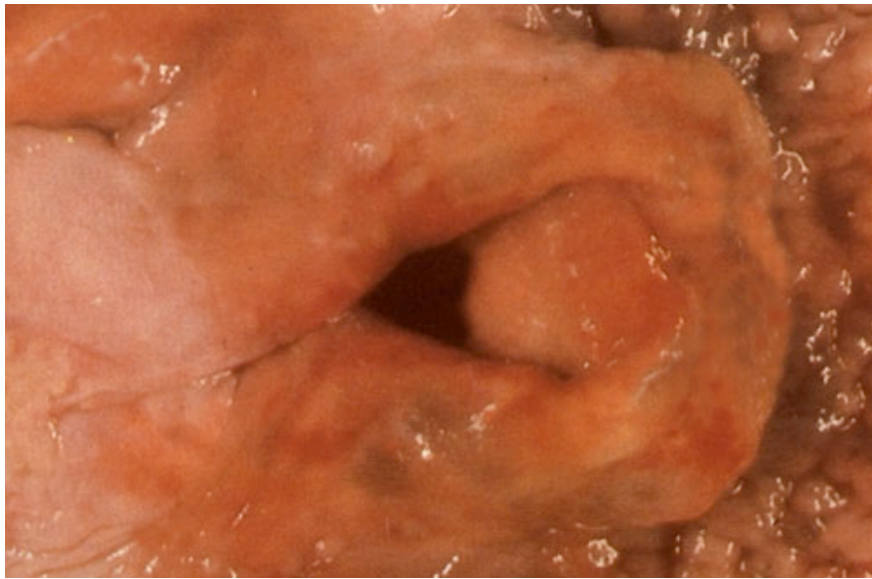


Fig. 2. Acute laryngeal edema in a patient who died from an anaphylactic reaction to penicillin. An emergent tracheotomy might have been life-saving in this instance.

and the patient ultimately sustained a small myocardial infarction. He had an uncomplicated post-myocardial infarction course. On the fifth hospital day, he had negative skin tests to benzyl penicilloyl-polylysine, potassium, benzylpenicillin and sodium benzylpenicilloate. He was discharged the following day.

¹Profuse sweating

²Electrocardiographic abnormality often reflecting myocardial ischemia or infarction

Questions for Case 7

- (1) Should he have received penicillin? Could the allergic reaction have been predicted or anticipated? Should he have been allowed to leave the doctor's office so promptly?
- (2) What were the immunological events leading to this reaction? Why hadn't he reacted to penicillin when he first received it? Based on the structure of penicillin (Fig. 3), how might this molecule hapten to induce an allergic reaction?

Questions for Case 7, cont'd

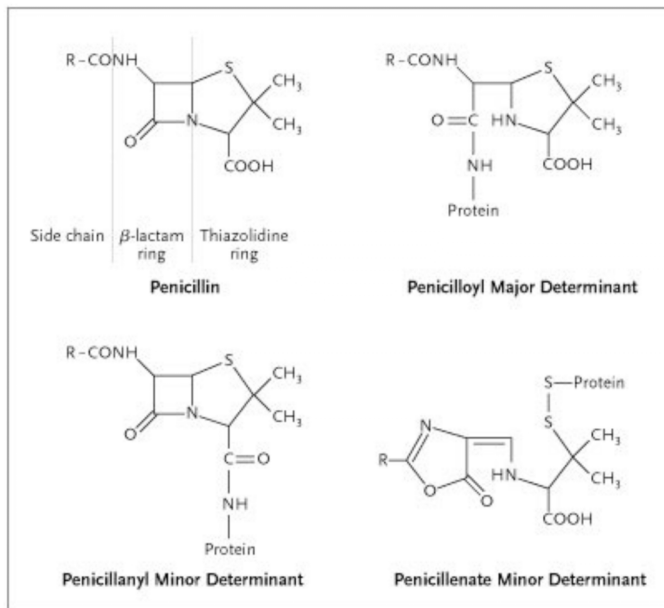


Fig. 3. Chemical structure of penicillin and its various determinants.

- (3) The patient received epinephrine, a potent vasoconstrictor, even though he had a history of ischemic heart disease. Was this a wise choice? Which of the therapeutic agents (i.e., Benadryl, prednisone, epinephrine) administered to the patient was critical in saving her life? Should prednisone have been given earlier?
- (4) Were any other allergic reactions apt to occur after the first day? What other types of rashes and allergic reactions can penicillin cause?
- (5) Why were her skin tests negative? Would later skin testing give the same result?
- (6) If the patient later manifested subacute bacterial endocarditis due to a penicillin-sensitive organism resistant to other antibiotics, could he receive penicillin? Would another β-lactam containing antibiotic (e.g., a cephalosporin) be an appropriate alternative?
- (7) What are some other causes of urticaria?
- (8) Individuals who give no atopic history can develop severe “anaphylactoid” reactions to radiocontrast media (RCM). Although the incidence of these severe reactions has been estimated to be 0.2%, milder systemic reactions occur in up to 4-12% of individuals receiving traditional RCM and 1-3% of those receiving non-ionic low-osmolality formulations of RCM. Treatment for anaphylactoid reactions to RCM is directed at mast cells despite the failure to demonstrate specific IgE against RCM in these individuals. Why might this be the case?