

# Vasculitis

Edward Dwyer, M.D.

Division of Rheumatology

- VASCULITIS is a primary inflammatory disease process of the vasculature

## Determinants of the Clinical Manifestations of Vasculitis:

- Target organ involved
- Size of vessel involved
- Pathobiology of the inflammatory process of involved vasculature

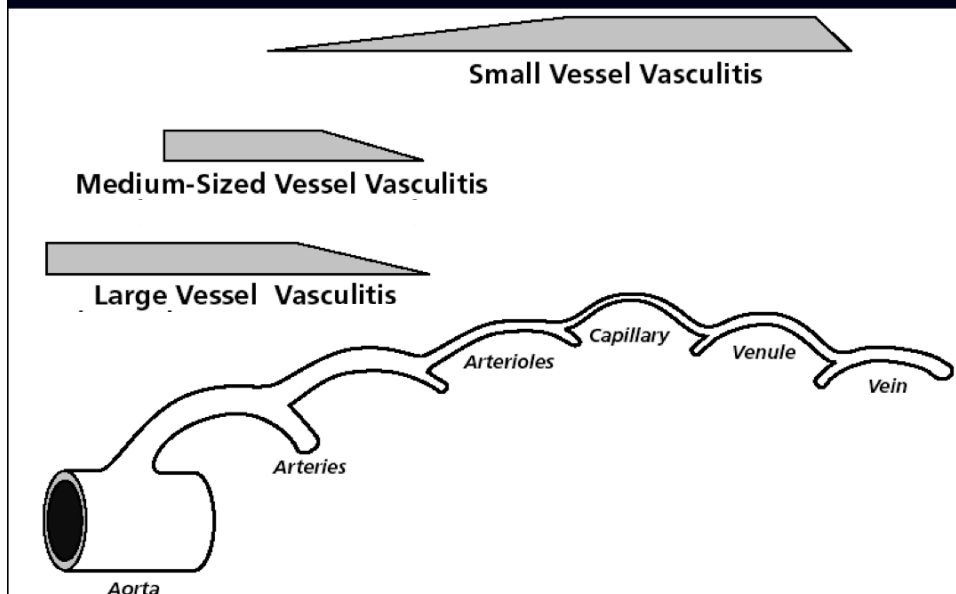
## Classification of Vasculitis

- Large-sized Vessels
  - Giant Cell Arteritis
  - Takayasu's Arteritis
- Medium-sized Vessels
  - Polyarteritis Nodosa
  - Kawasaki's Disease
- Small-sized Vessels
  - Anti-Neutrophil Cytoplasmic Ab Associated
    - Wegener's Granulomatosis
    - Microscopic Polyangiitis
    - Churg-Strauss Syndrome

# Classification of Vasculitis

- Small-sized Vessels(cont.)
  - Immune Complex mediated:
    - Cryoglobulinemia
    - Henoch-Schonlein purpura
    - Hypocomplementemic Urticarial Vasculitis
    - Vasculitis associated with SLE, Rheumatoid arthritis, or other autoimmune diseases
    - Serum-sickness or drug-induced vasculitis

# Classification of Vasculitis



## Sequelae of Vasculitis

- Stenosis and/or occlusion of involved vasculature resulting in organ ischemia or infarction
- Necrosis of vessel wall resulting in aneurysmal dilatation/rupture or intravascular thrombosis causing organ ischemia or infarction

## Diagnostic Approaches

- Biopsy of involved organs
- Radiographic evaluation of involved vessels
  - Conventional Angiography
  - CT Angiography
  - MR Angiography
- Serology (e.g., autoantibodies)

# Giant Cell Arteritis (Temporal Arteritis)

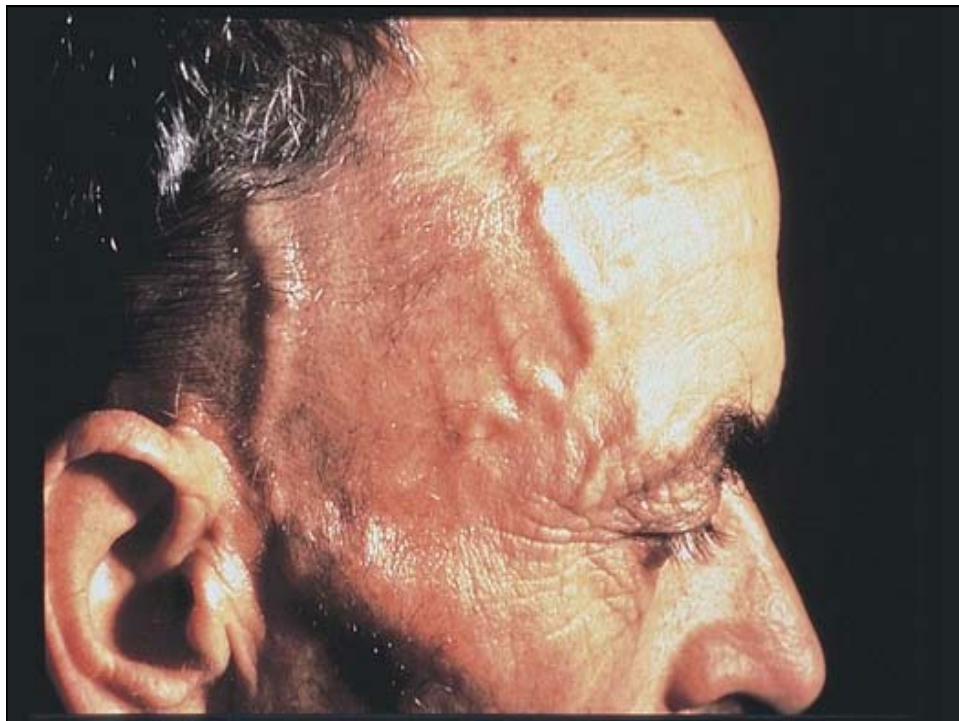## Epidemiology of Giant Cell Arteritis

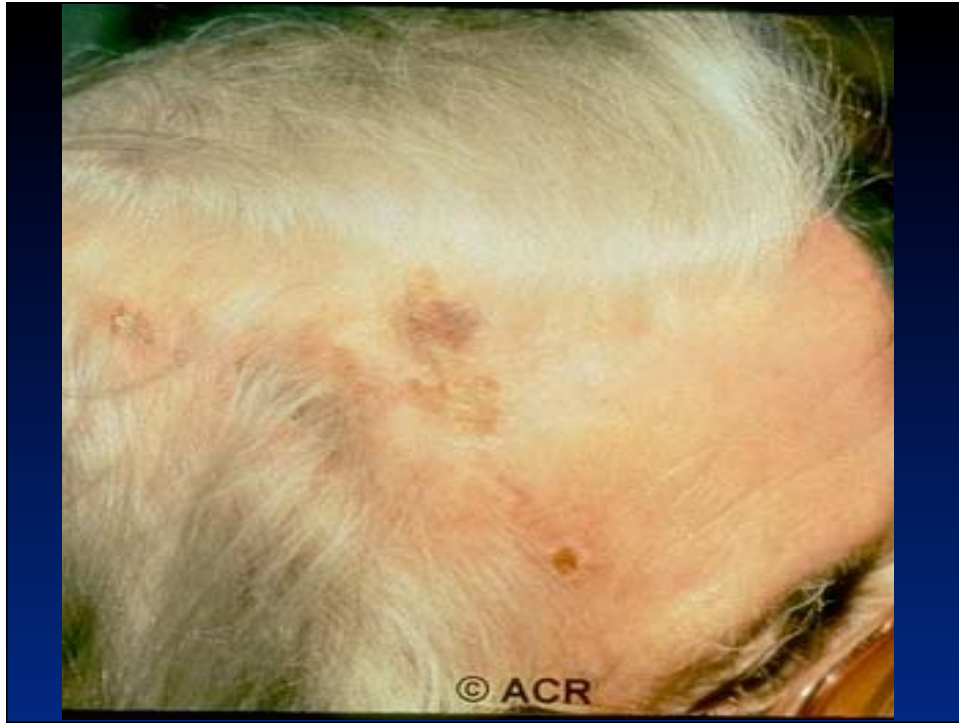- Age: > 50 years-old
- Racial/Ethnic Background (annual Incidence)
  - 20/100,000 Northern European
  - 2/100,000 African Americans and Hispanics
  - <1/1,000,000 Asians

## Vasculature involved

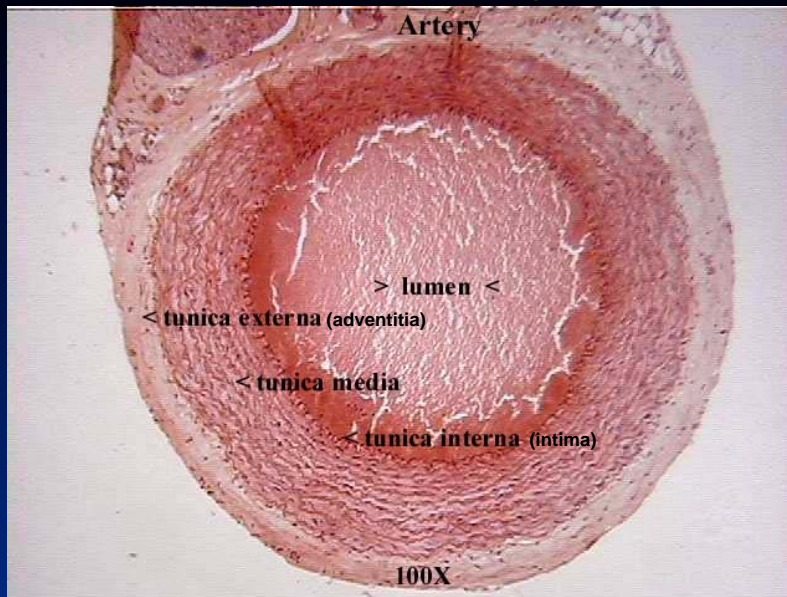
Thoracic aorta and major branches:

- Carotid artery extra-cranial branches
  - Temporal artery
  - Occipital artery
  - Ophthalmic artery
  - Posterior ciliary artery
- Subclavian/axillary artery

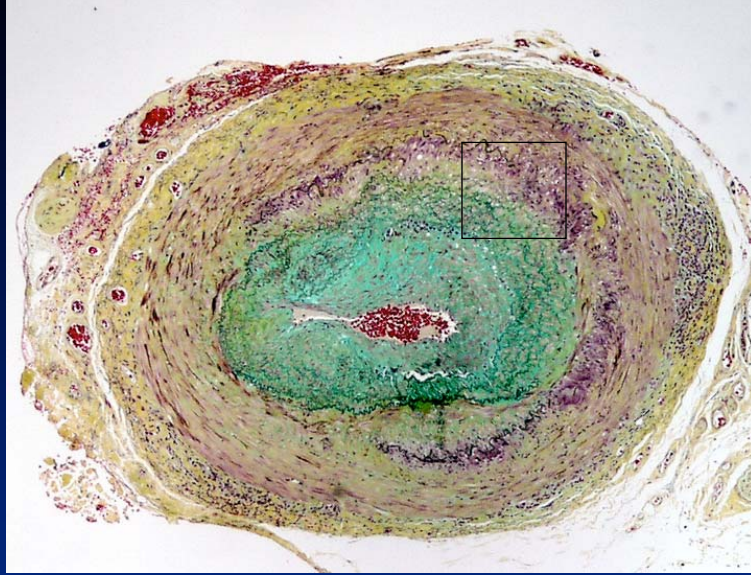




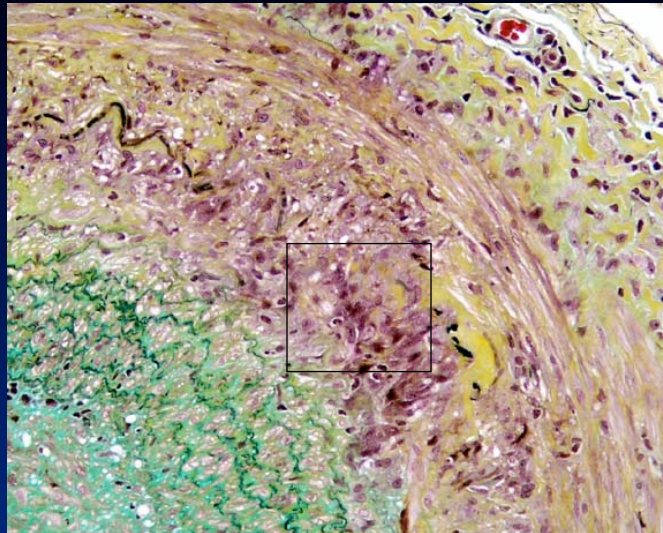
## Muscular Artery



## Temporal Artery Biopsy

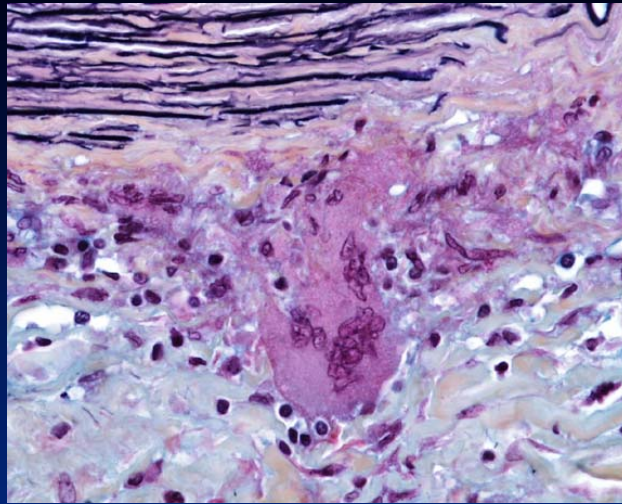


## Temporal Artery Biopsy





## Giant Cell



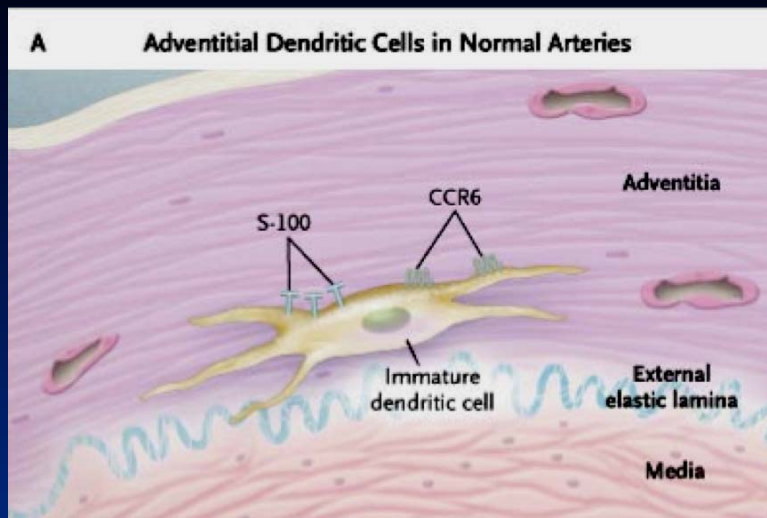
## Clinical Manifestations

- Constitutional
  - Fatigue
  - Weight loss
  - Fever
- Headache
  - 66% of patients
  - Most commonly temporal, but frontal or occipital pain also common
- Jaw pain(claudication)
  - 50% of patients

## Clinical Manifestations

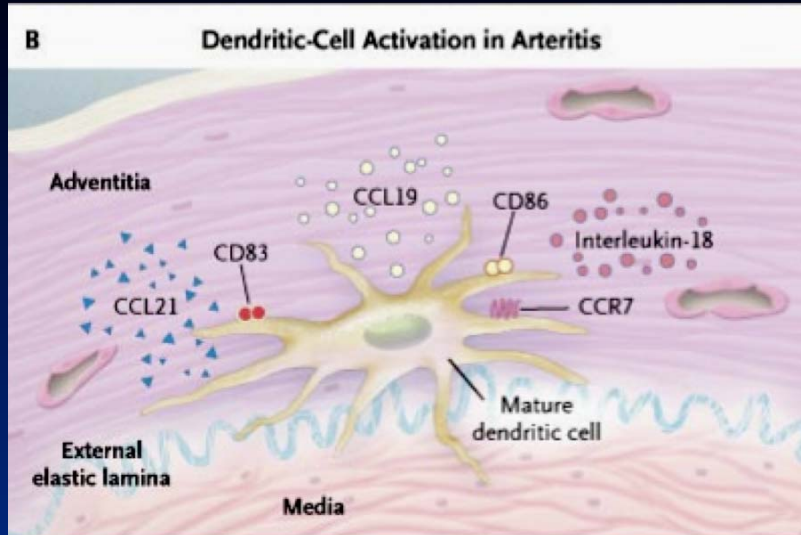
- Visual loss
  - Acute onset partial or complete visual field loss in 15-20% of patients
- Arm claudication
  - 15% of patients

## Giant Cell Arteritis Pathogenesis



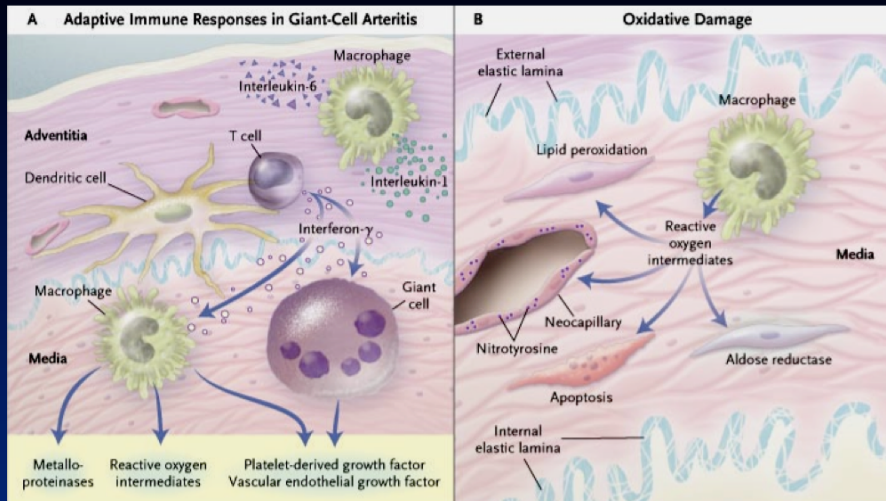
Weyand, C. M. et al. N Engl J Med 2003;349:160-169

# Temporal Arteritis Pathogenesis



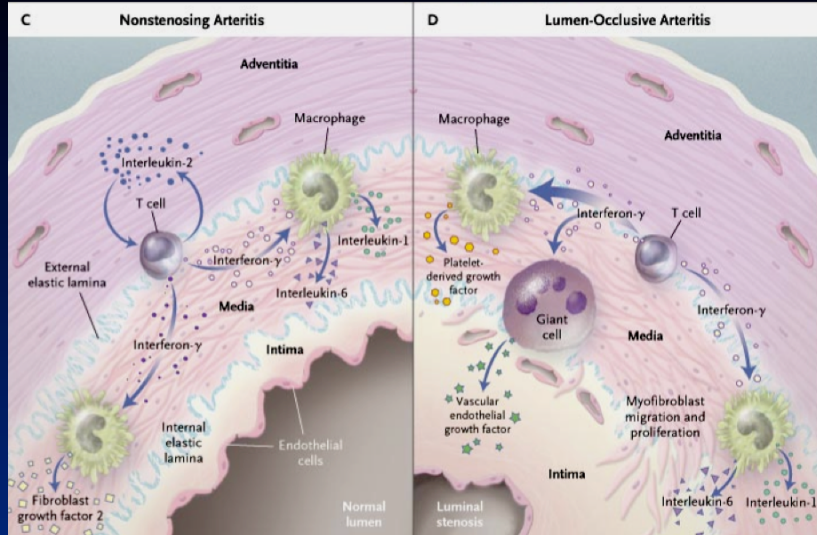
Weyand, C. M. et al. N Engl J Med 2003;349:160-169

# Temporal Arteritis Pathogenesis

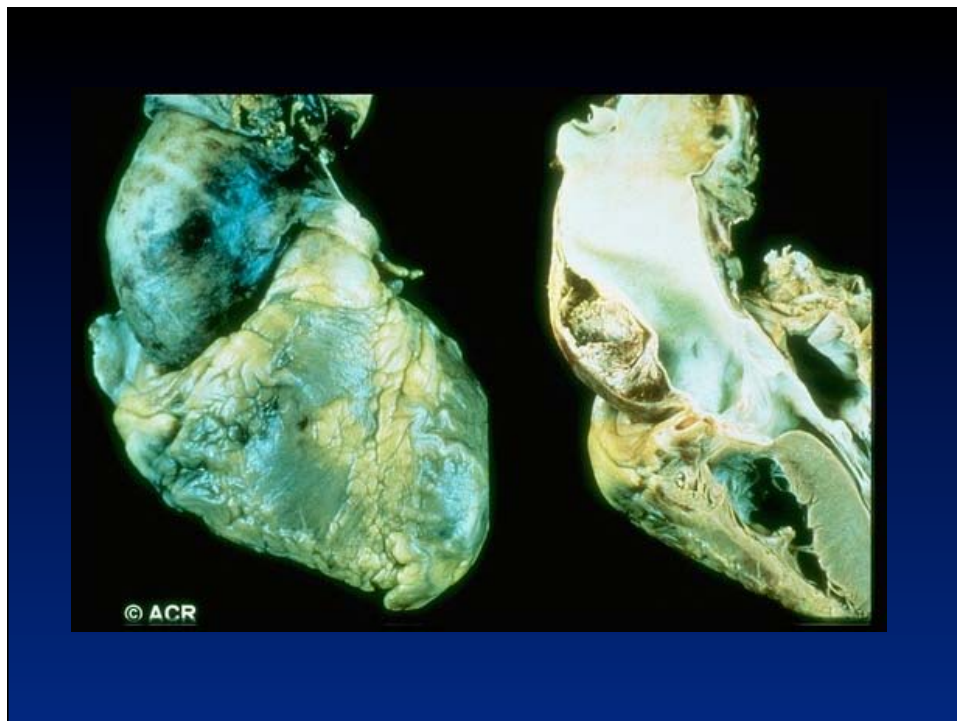

Weyand, C. M. et al. N Engl J Med 2003;349:160-169

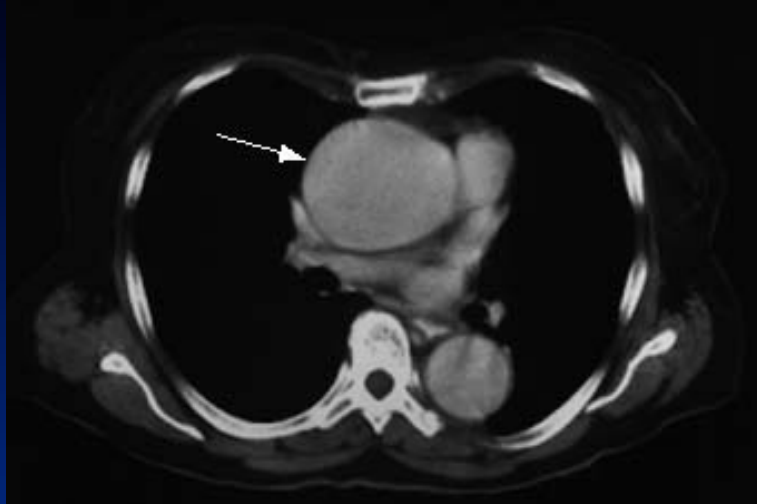# Temporal Arteritis Pathogenesis



Weyand, C. M. et al. N Engl J Med 2003;349:160-169



## Thoracic Aortic Aneurysm



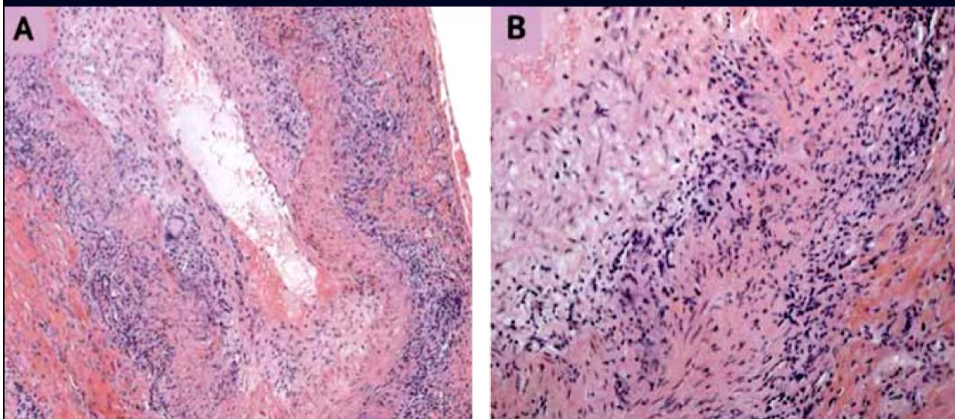
## Laboratory Abnormalities

- Elevated Acute Phase Reactants
  - Erythrocyte sedimentation rate (ESR)
  - C-reactive protein
  - Elevated IL-6 levels

## Diagnosis

- Temporal Artery biopsy
- Elevation of acute phase reactants

## Giant Cell Arteritis of Temporal Artery



Weyand C and Goronzy J. N Engl J Med 2003;349:160-169

## Treatment

- Glucocorticoids
  - Prednisone 1 mg/kg q d with tapering regimen over 4-6 months

## Polyarteritis Nodosa

- Necrotizing arteritis of medium-sized muscular arteries
  - Pathology: “fibrinoid necrosis”

## Vasculature involved

- Superior mesenteric artery
- Celiac and hepatic arteries
- Renal artery
- Muscular arteries of the extremities

## Epidemiology of Polyarteritis Nodosa

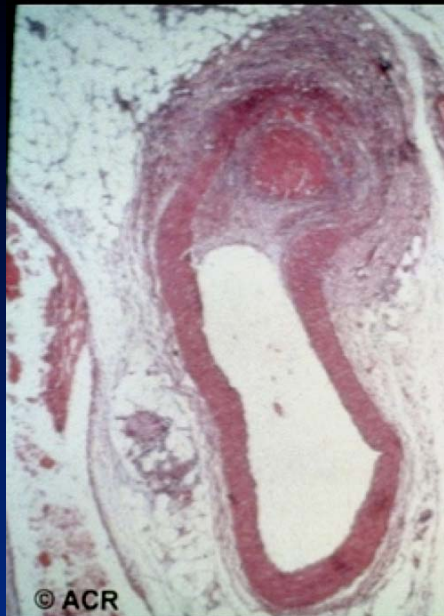
- Age: 20-70 years-old
- No racial or ethnic predilection
- Incidence
  - 2-4/1,000,000 annual incidence
  - 70-80/1,000,000/ in regions which are endemic for Hepatitis B



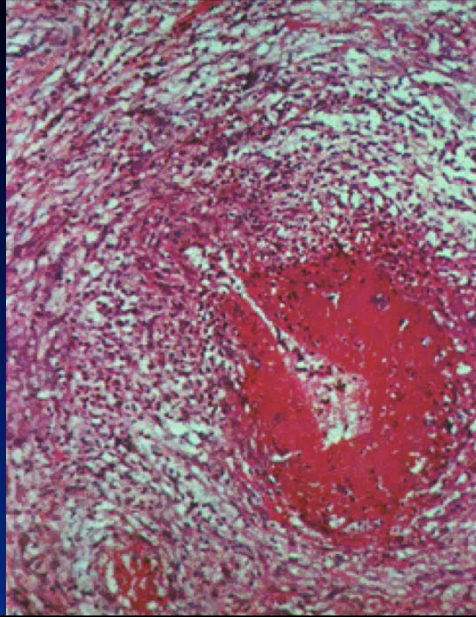
## Hepatitis B Virus Association

- Usually occurs during the first 6 months after infection
- Usually positive for surface and e antigen

## Necrotizing Arteritis



## Polyarteritis Nodosa



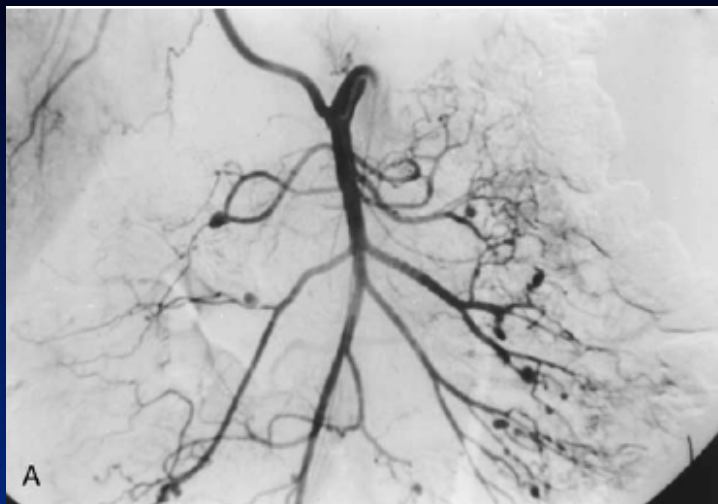## Clinical Manifestations

- Constitutional symptoms
  - Fatigue
  - Weight loss
  - Fever
- Gastrointestinal
  - Abdominal pain
- Kidney
  - Hypertension

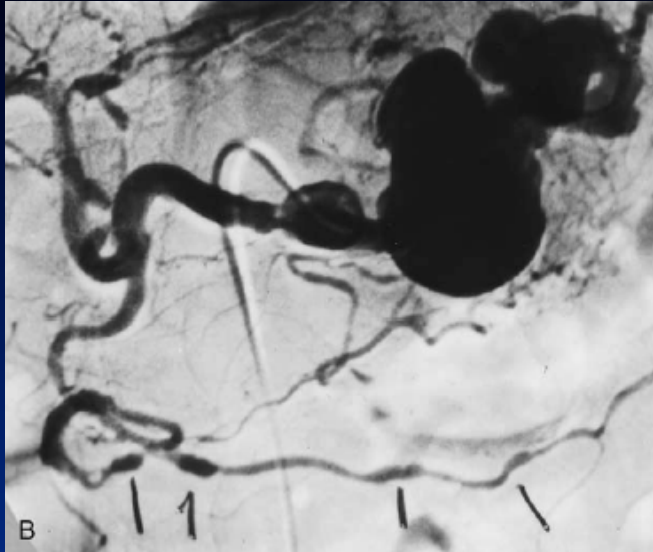
## Clinical Manifestations

- Peripheral Nervous system
  - Mononeuritis multiplex (e.g. wrist drop, foot drop)
- Skin
  - Nodules or ulcers
- Digital gangrene

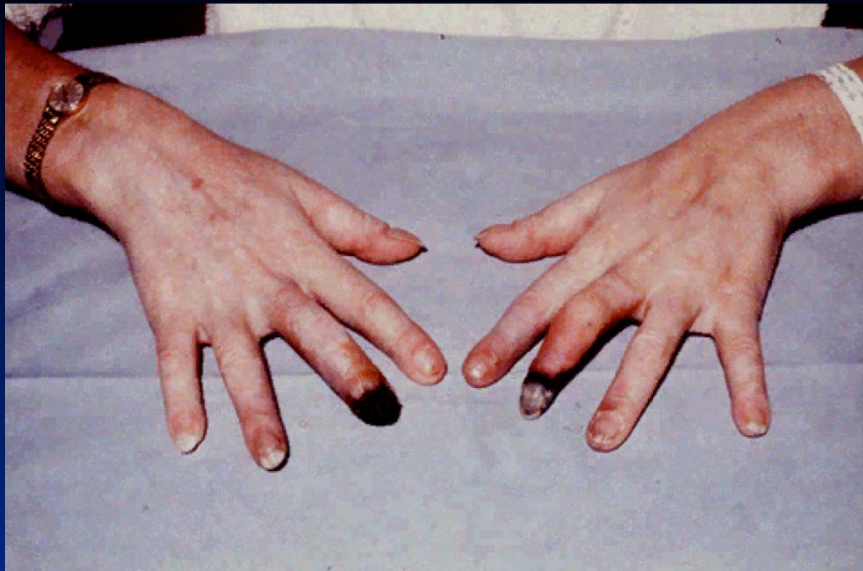## Angiogram of Superior Mesenteric Artery

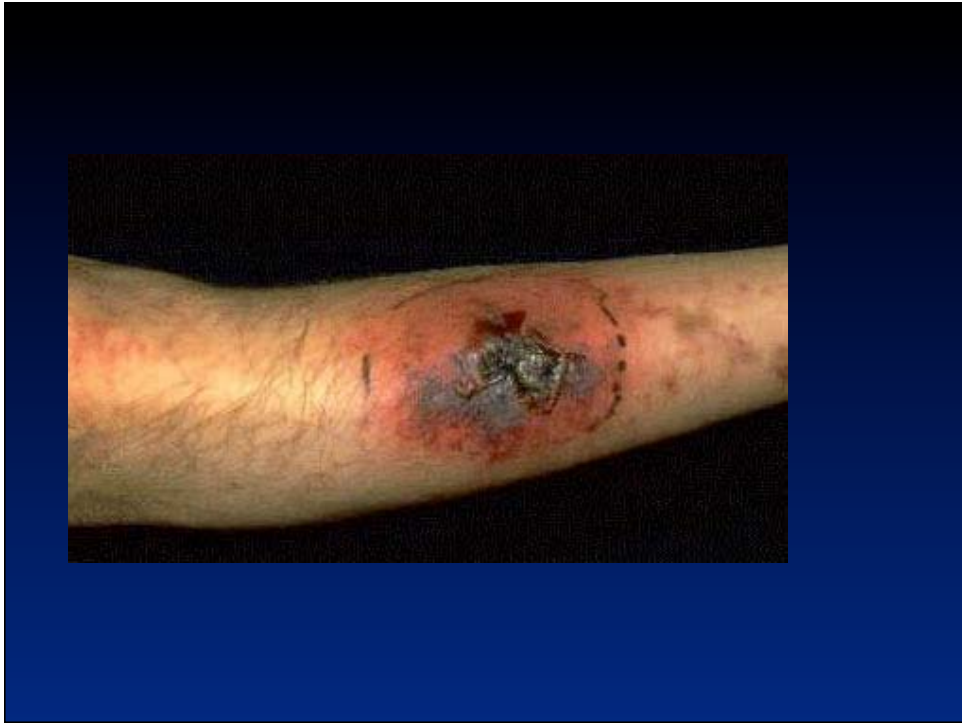

## Angiogram Splenic Artery

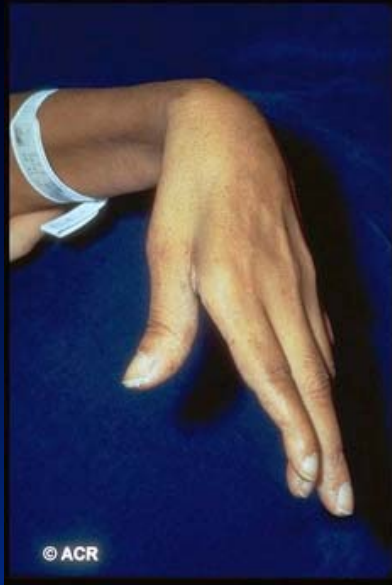

## Digital Gangrene

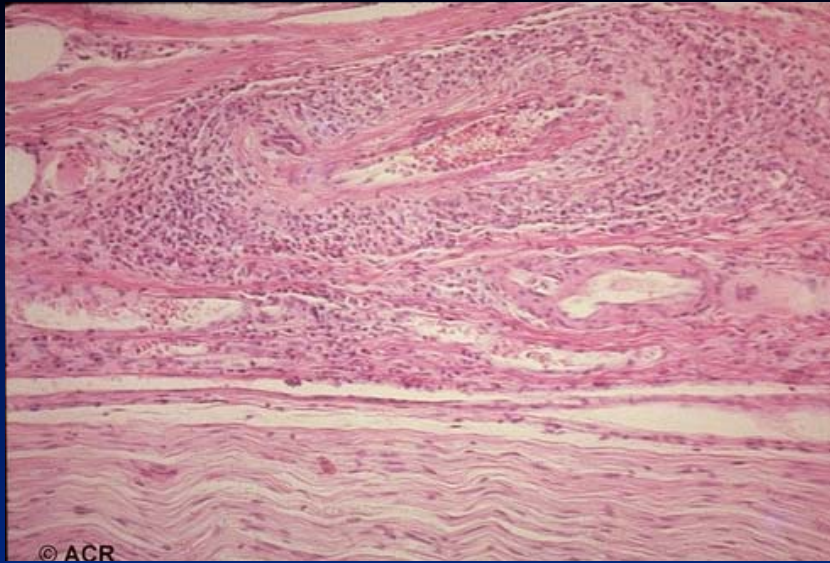




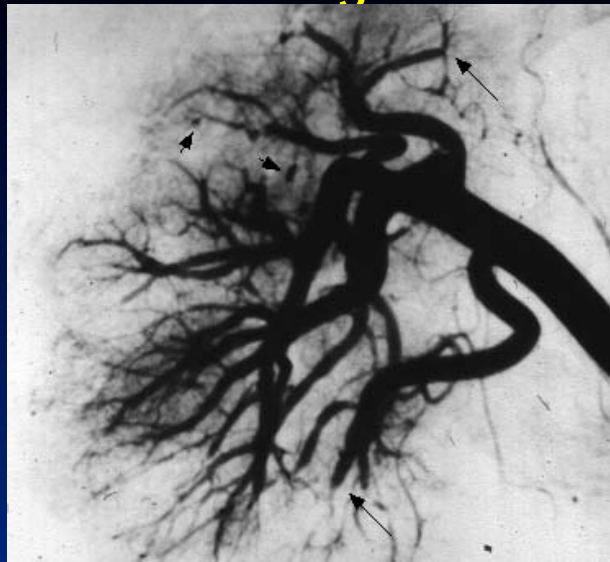
## Mononeuritis Multiplex

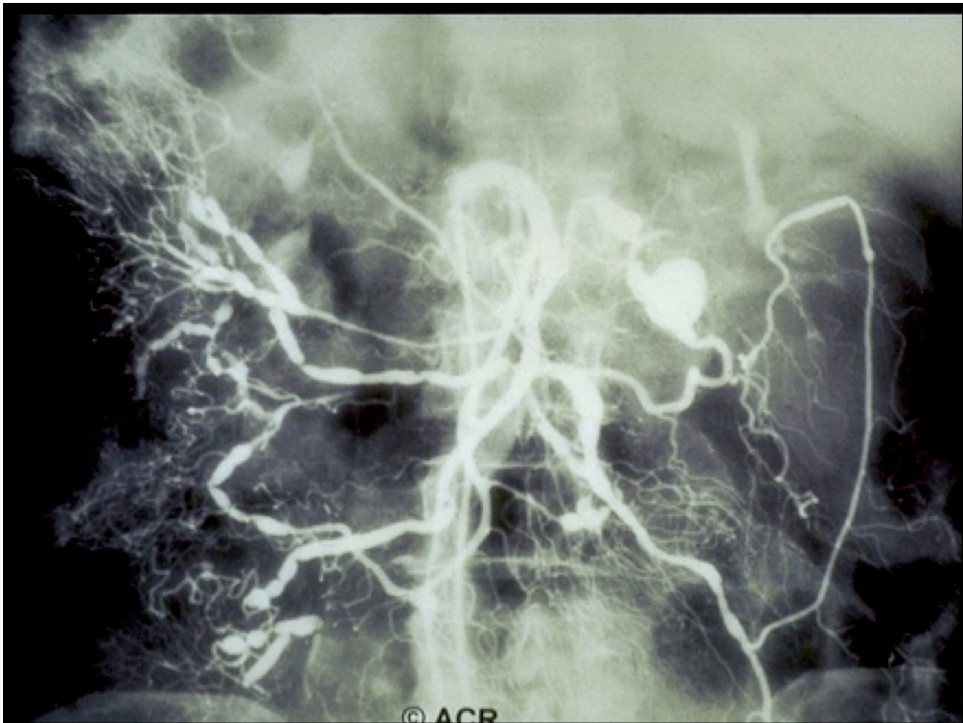
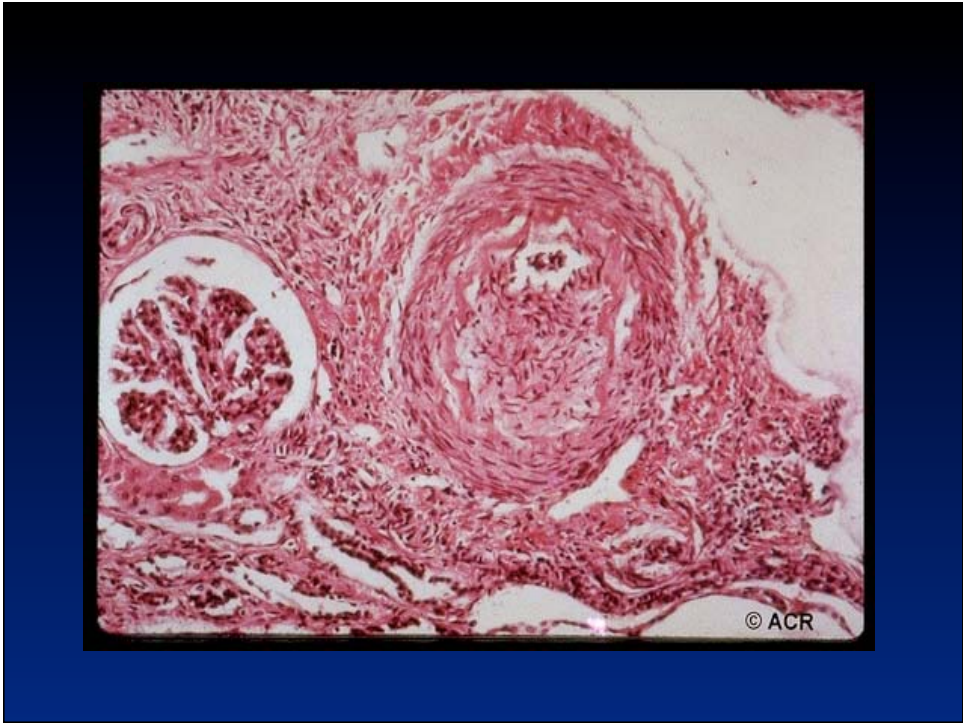


## Sural Nerve Biopsy



## Renal Arteriogram--PAN





## Treatment

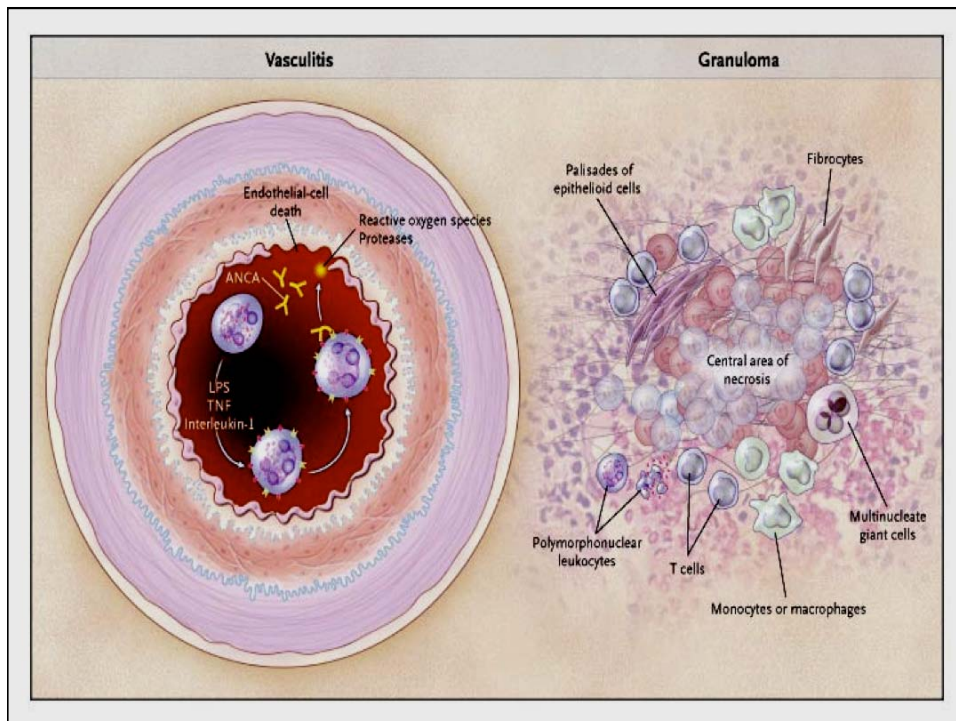
- 5 yr survival untreated: 13%
- Disease onset
  - Prednisone 1 mg/kg q d
  - Oral cyclophosphamide 2 mg/kg q d
- Duration of treatment
  - At least one year
- +HBV PAN
  - Interferon- $\alpha$

## Wegener's Granulomatosis



# Granuloma

- Nodular aggregate of macrophages or cells derived from the monocyte-lineage, which is typically surrounded by a “rim” of lymphocytes, and commonly associated with the presence of multinucleated giant-cells



## Epidemiology of Wegener's Granulomatosis

- Age: 25-60 years-old
- No racial or ethnic predilection
- Prevalence: 5-7/100,000

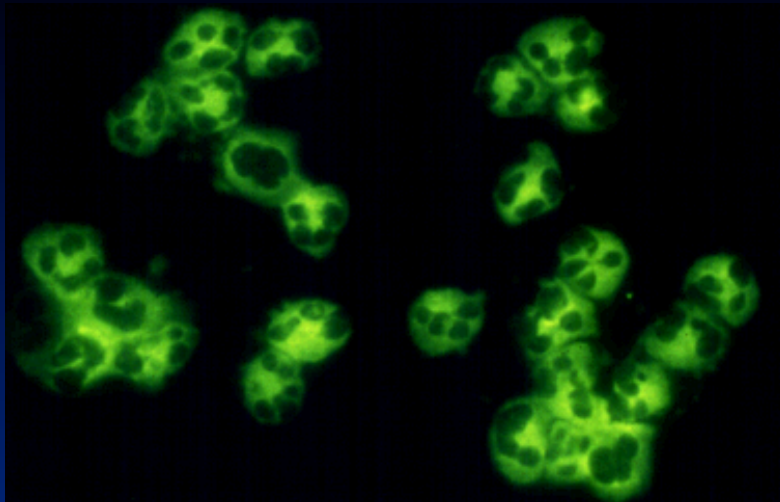
## Vasculature involved

- Upper respiratory tract arterioles/capillaries
- Lung
  - Arterioles and capillaries
- Kidney
  - Glomerulonephritis ("pauci immune")

## Clinical Manifestations

- Upper Respiratory Tract
  - Chronic Sinusitis
  - Chronic Otitis
- Lower Respiratory Tract
  - Pulmonary nodules
  - Alveolar hemorrhage(hemoptysis)
- Kidney
  - Glomerulonephritis
- Peripheral Nervous System
  - Mononeuritis multiplex
- Skin
  - Purpura

## Anti-Neutrophil Cytoplasmic Ab (ANCA)



## ANCA in Wegener's Granulomatosis

- Cytoplasmic reactivity (C-ANCA)
  - Antigenic target = Proteinase 3
    - Serine proteinase of lysosomal granules of monocytes and azurophilic granules of neutrophils

## Anti-Neutrophil Cytoplasmic Antibody

- c-ANCA/anti-PR3 ELISA
  - Wegener's Granulomatosis
- p-ANCA/anti-MPO ELISA
  - Microscopic Polyangiitis
  - Churg-Strauss Syndrome

## Survival of Wegener's Granulomatosis

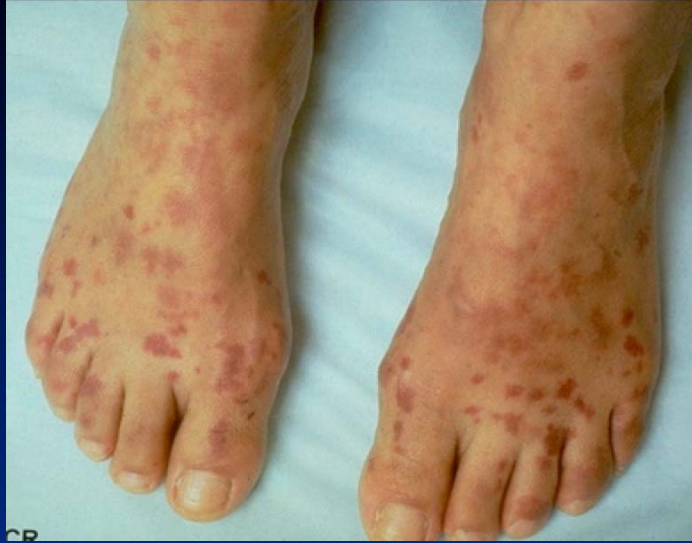- Untreated: 10% at 2 years
- Treated: 80% at 8 years

## Morbidity of Wegener's Granulomatosis

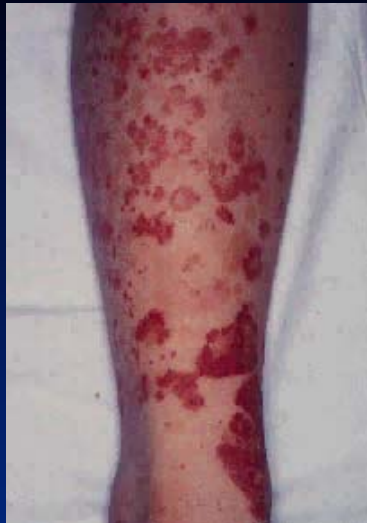- Permanent renal insufficiency- 42%
- End-stage renal disease- 11%
- Hearing loss- 35%
- Nasal deformities- 28%
- Tracheal stenosis- 13%

Note: No significant morbidity from pulmonary disease

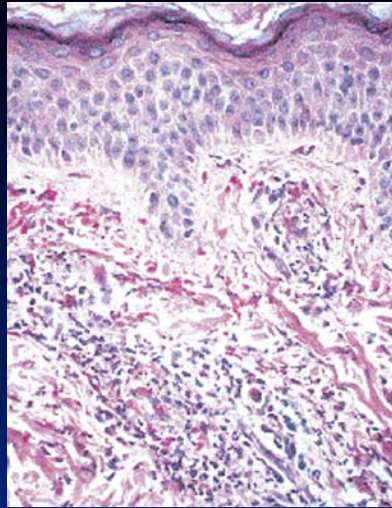
## Palpable Purpura



## Palpable Purpura

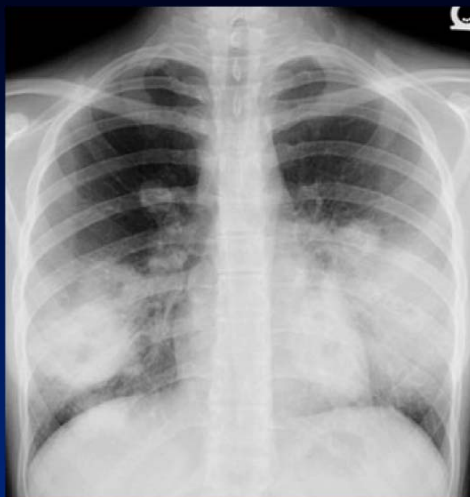

## Purpuric Dermal Vasculitis

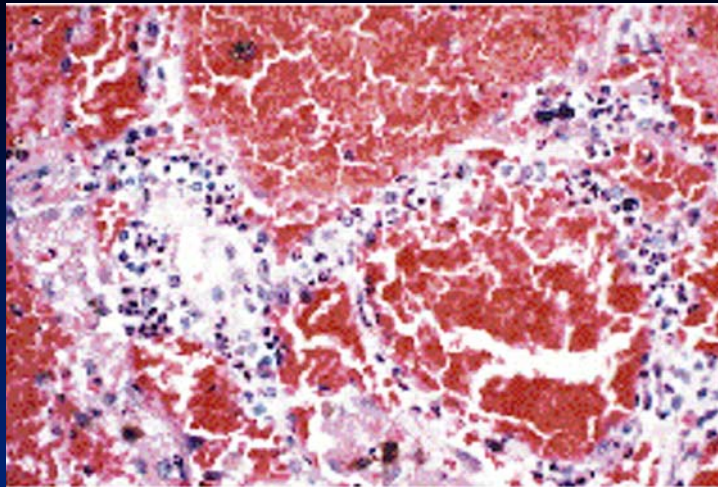


Jennette J and Falk R. N Engl J Med 1997;337:1512-1523

## Pulmonary Nodules and Hemorrhage

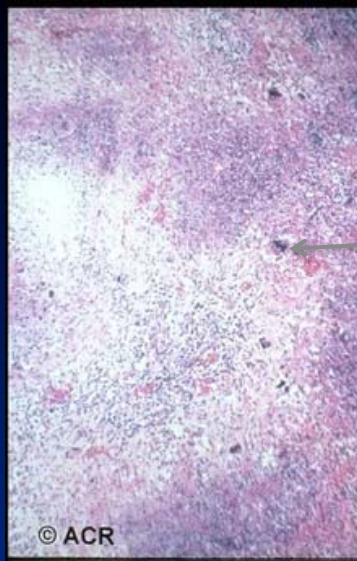


## Alveolar Capillaritis in ANCA-associated Vasculitis



Jennette J and Falk R. N Engl J Med 1997;337:1512-1523

## Granulomatous Inflammation

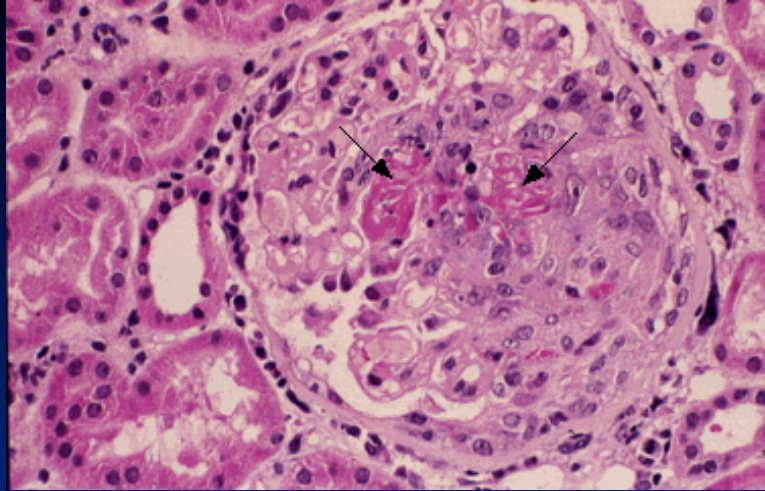


Multinucleated Giant Cell

© ACR

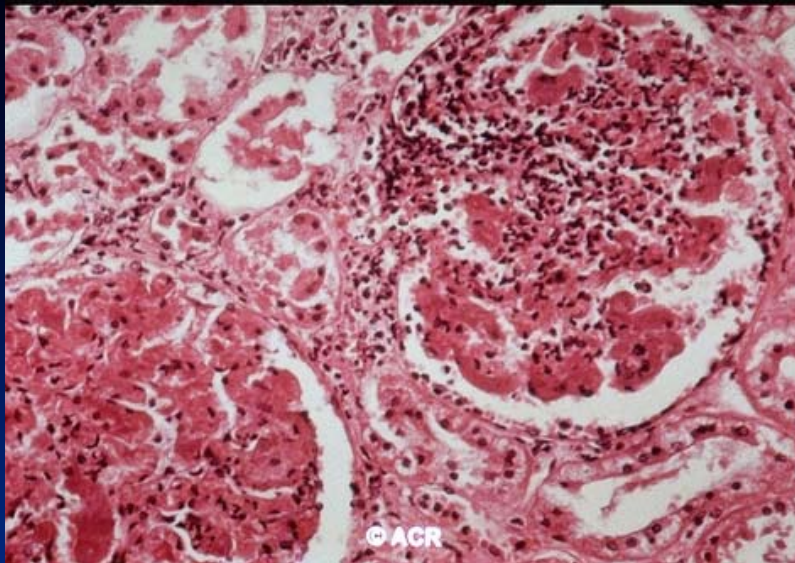


## Necrotizing Glomerulonephritis\*



\* "Pauci-immune" Glomerulonephritis

## Necrotizing Glomerulonephritis



## Treatment Regimen

- Prednisone 0.5-1 mg/kg q d (tapered) plus cyclophosphamide 2 mg/kg q d for approximately one year
  - 85-90% response rate
  - 75% complete remission
  - 30-50% at least one relapse

## Henoch Schonlein Purpura

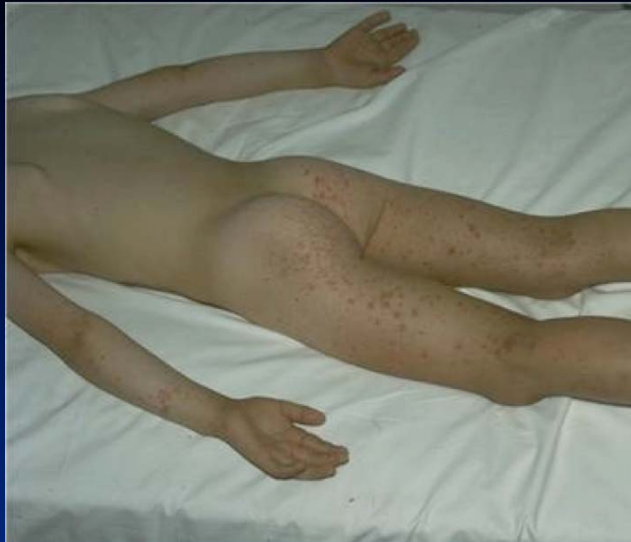- Age: 5-7 years old (range: 5-15)
  - Children: 20/100,000
    - 50% preceded by upper respiratory tract infection
  - Adults: <1/100,000
- Gender: male/female : 1.5/1

## Vasculature involved

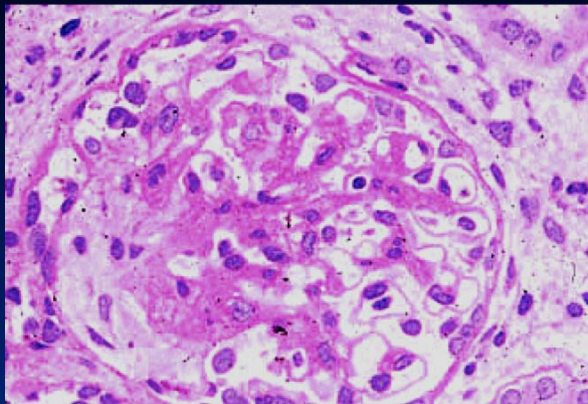
- Gastrointestinal tract
  - Submucosal arterioles/venules
- Kidney
  - Glomerulonephritis
- Skin
  - Dermal arterioles/venules

## Clinical Manifestations

- Abdominal pain
  - Intussusception
- Hematuria/proteinuria
  - Renal insufficiency infrequent
- Purpura
- Arthralgia/arthritis



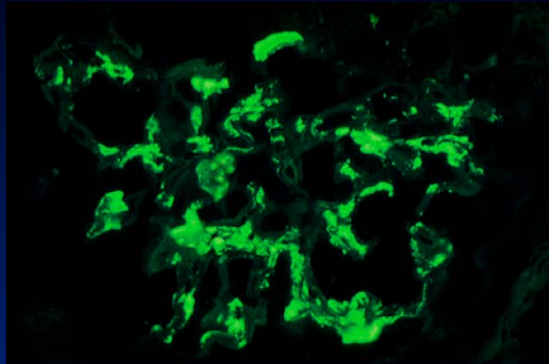
## Glomerulonephritis in HSP



## Pathogenesis

- Tissue (vascular) deposition of IgA-containing immune complexes

## Immunofluorescence for IgA in Kidney



## Treatment

- Prognosis: very favorable
- No indication for immunosuppression
- Supportive therapy:
  - Hydration
  - Bed rest
  - Analgesia
    - Non-steroidal anti-inflammatory agents

## Vasculitis

Edward Dwyer, M.D.

Division of Rheumatology