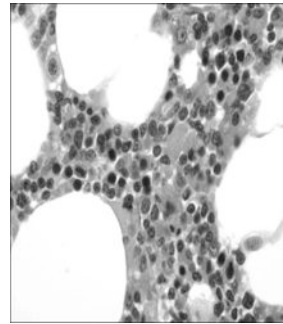


LYMPHOMA

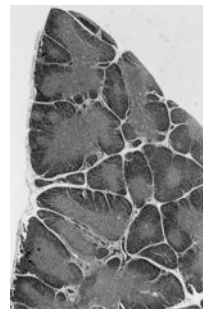
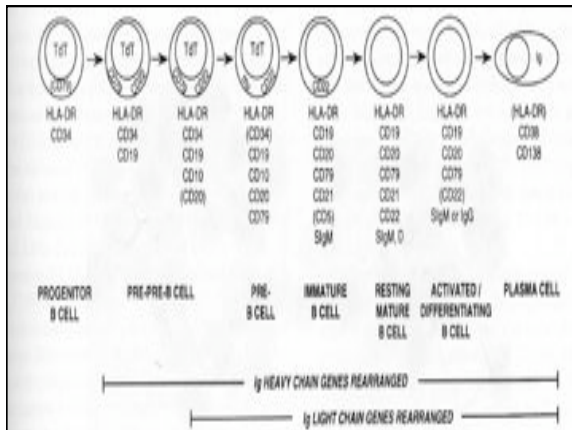
BACHIR ALOBEID, M.D.
DEPARTMENT OF PATHOLOGY
Columbia University-College of Physicians & Surgeons

Lymphoma: Neoplastic proliferation of lymphoid cells

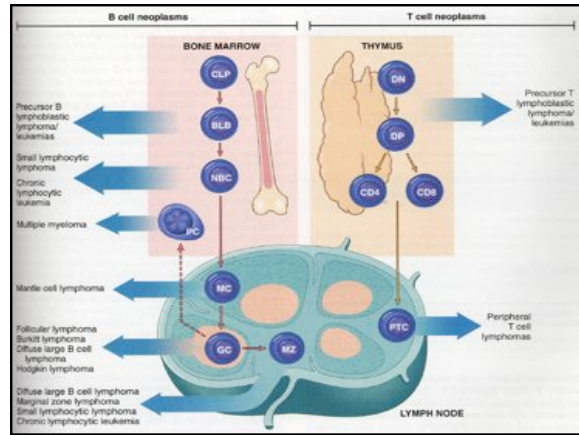
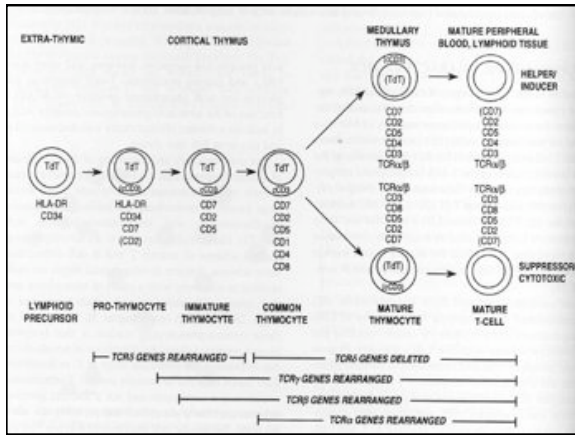
Normal development of lymphocytes



B-Cells
in the bone
marrow
“hematogones”

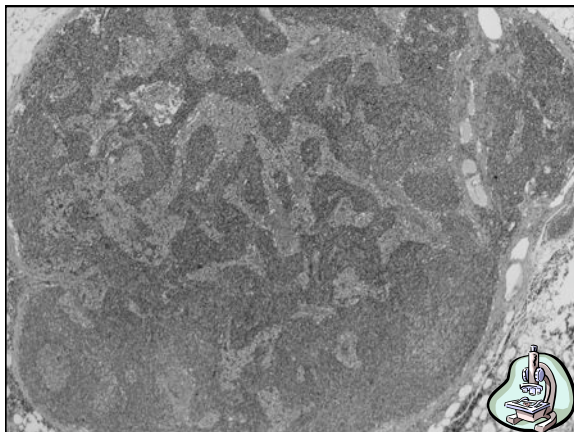
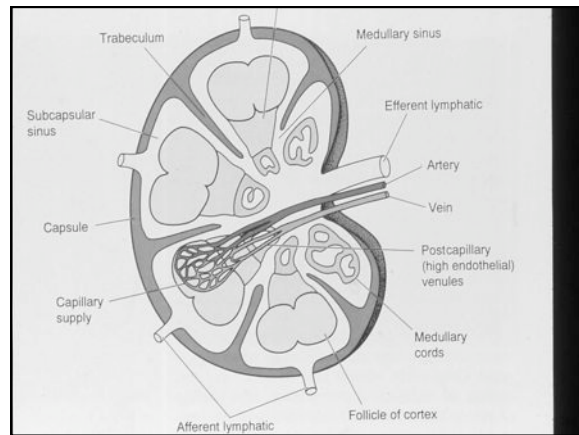


T-Cells
in the thymus
“thymocytes”



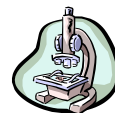Normal Lymph Node

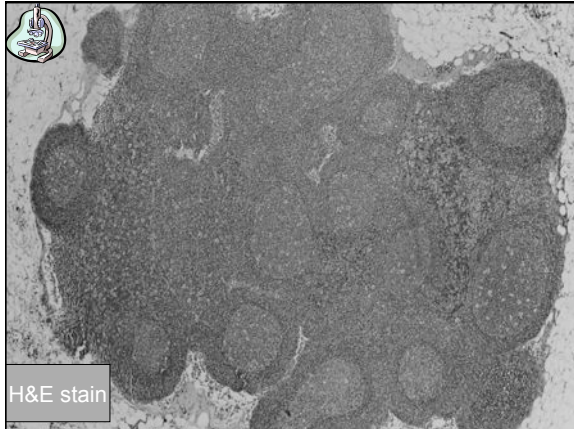
- **Normal compartments of the lymph node:**
 - 1- cortex / follicles
 - 2- paracortex
 - 3- medullary cords
 - 4- sinuses



Diagnostic Methods

- **Gold standard method:** **Histomorphologic evaluation of the lymphoid tissues.**
- Sections of fixed tissue -embedded in paraffin- for routine H&E staining





Diagnostic Methods

Ancillary studies:

- Immunophenotyping:

- 1- Immunohistochemistry (IHC) and/or
- 2- Flow cytometry

Lymphoid Markers

Lymphoid markers commonly used in immunophenotypic studies:

Pan-hematopoietic: CD45, CD43

B-cell markers: CD19, CD20, CD22, CD79a, Pax5, MUM1

T-cell markers: CD2, CD3, CD5, CD7, CD4, CD8

Germinal center cells: CD10, Bcl-6, HGAL

Follicular dendritic cells: CD21, CD23, CD35

Plasma cells: CD138, CD38, MUM1

Immature lymphoid cells: TdT, CD10, CD34, CD1a

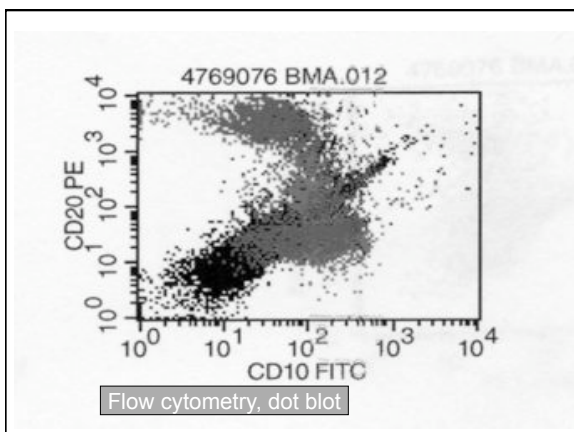
Activated lymphoid cells: CD30, CD23

NK-cells: CD56, CD57

Diagnostic Methods

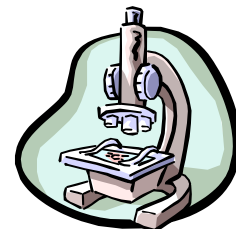
- **Flow cytometry (multi-parametric)** analysis is the method of choice to demonstrate the intensity of antigen expression and simultaneous expression of multiple antigens..

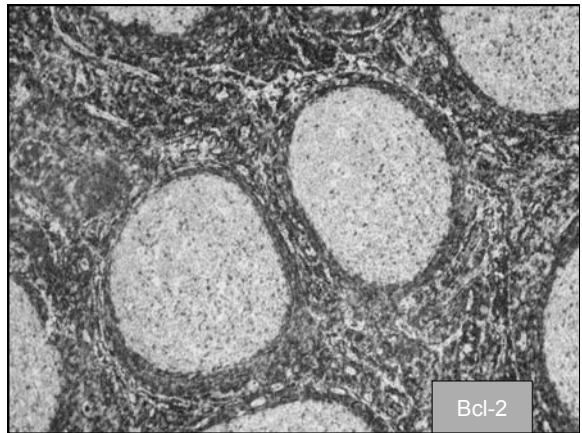
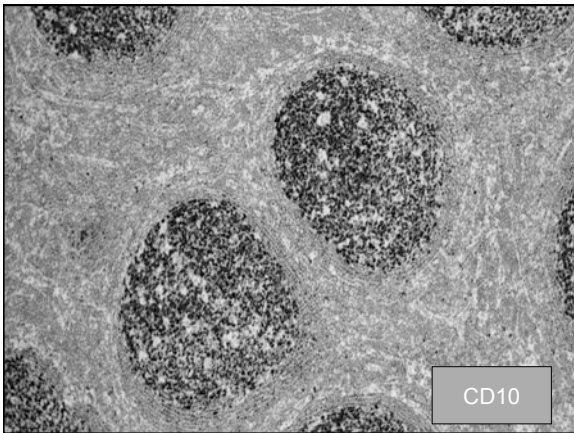
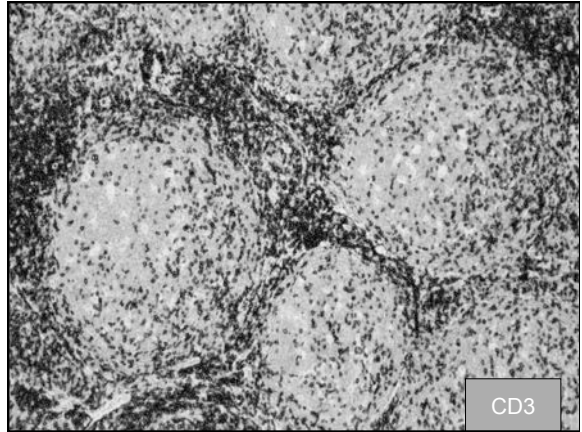
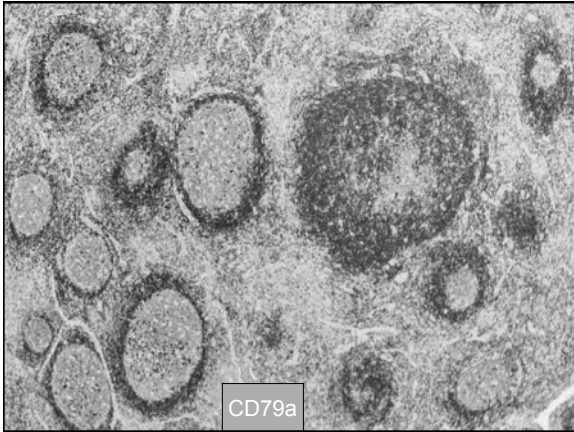
Cell suspensions and flow cytometer



Diagnostic Methods

- **IHC** is good to show the distribution and localization of different lymphoid elements in tissue sections..

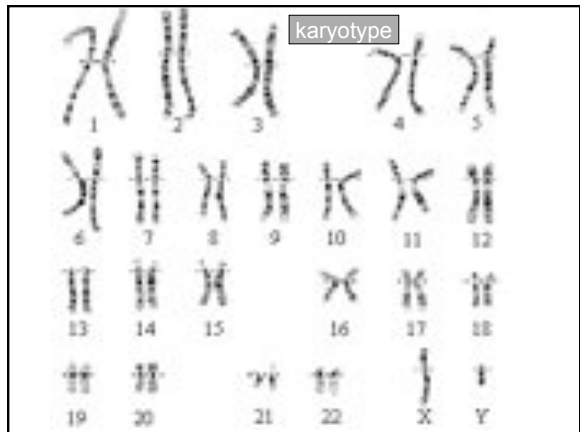


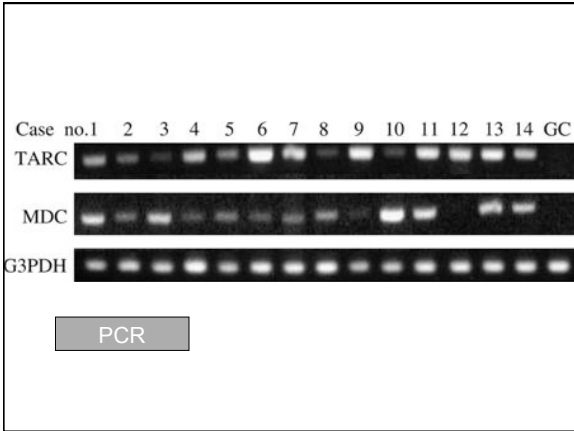

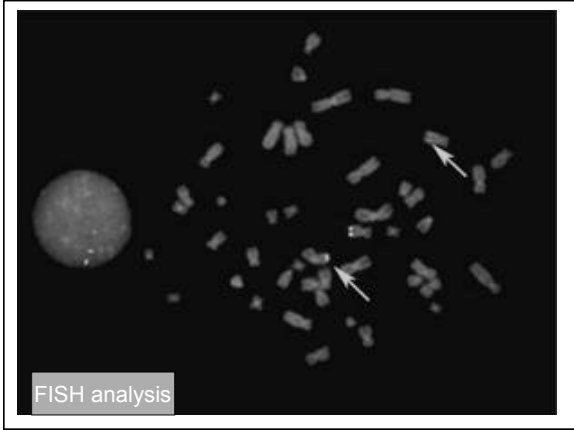


Diagnostic Methods, cont.

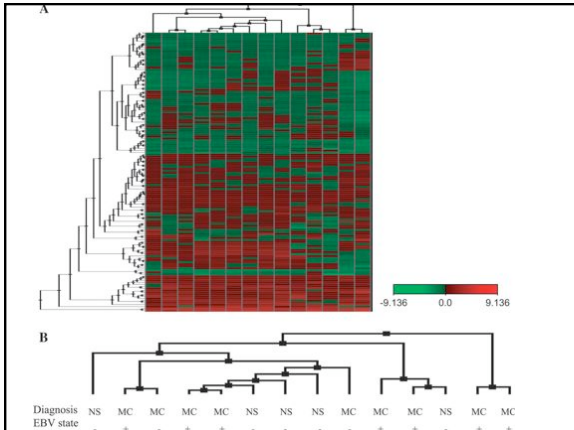
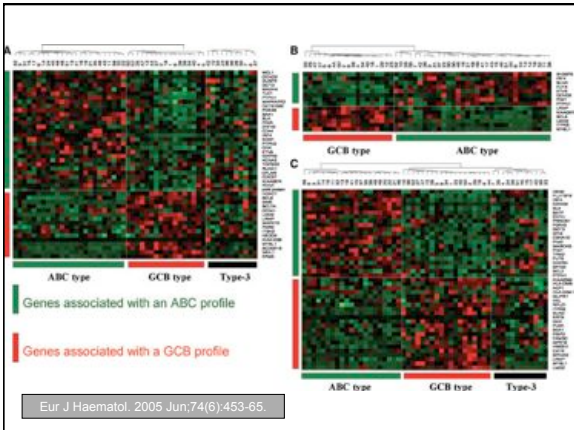
Ancillary studies:

- Cytogenetic studies: Conventional Karyotype analysis, FISH analysis, SKY analysis
- Molecular analysis: Southern blot and PCR





DNA microarray platforms: to demonstrate gene expression patterns/profiles; important methodology for the diagnosis and classification of hematological malignancies in the future



LYMPHOID DISORDERS

- 1- Benign (reactive) Lymphadenopathies
- 2- Malignant Lymphoproliferative Disorders/Lymphomas
- 3- Atypical (borderline/grey zone) Lymphoproliferative Disorders

LYMPHOMAS

- **Non-Hodgkin Lymphoma (NHL):**
 - 1- *B-cell lymphomas (most common)*
 - 2- *T-cell and NK cell lymphomas*
- **Hodgkin Lymphoma (disease):**
 - 1- *Nodular Lymphocyte Predominance*
 - 2- *Classical Hodgkin Lymphoma*

Non-Hodgkin Lymphoma

- **Definition:**

Malignant neoplastic proliferation of lymphoid cells derived from a single transformed cell (monoclonal proliferation).

Non-Hodgkin Lymphoma

- **Epidemiology:**
 - More common in the developed countries
 - Frequency of different types varies around the world:
 - B- vs NK/T-cell..
 - Burkitt lymphoma..
 - adult T-cell leukemia/lymphoma..

Non-Hodgkin Lymphoma

- **Epidemiology, cont.:**
 - Individuals with immunodeficiencies/immune disorders are at higher risk :
 - 1- Congenital (primary) immunodeficiency
 - 2- Acquired immunodeficiencies (HIV-related, post-therapy)
 - 3- Autoimmune diseases..

Non-Hodgkin Lymphoma

- **Etiology:**
 - **Infectious agents and development of lymphoma:**
 - HTLV-1 infection and T-cell leukemia/lymphoma..
 - Epstein-Barr virus (EBV) and Burkitt's lymphoma..
 - Human herpesvirus-8 (HHV-8) and primary effusion lymphoma
 - HCV and marginal zone lymphoma
 - H. Pylori and gastric MALT lymphoma

Non-Hodgkin Lymphoma

- **Etiology, cont.:**
- **Genetic alterations and development of lymphoma..**
 - t(14;18) translocation and follicular lymphoma..
 - t(8;14) translocation and Burkitt's lymphoma..
 - t(11;14) translocation and mantle cell lymphoma..

Non-Hodgkin Lymphoma

- **Classification of NHLs:**
- * **Rappaport Classification:**
Based on morphology; growth pattern (diffuse vs. nodular) and cytomorphology..
- * **Working Formulation (1984):**
Based on morphology; divides NHLs into prognostic groups (useful to clinicians) and can be applied in the absence of immunophenotypic studies..

Non-Hodgkin Lymphoma

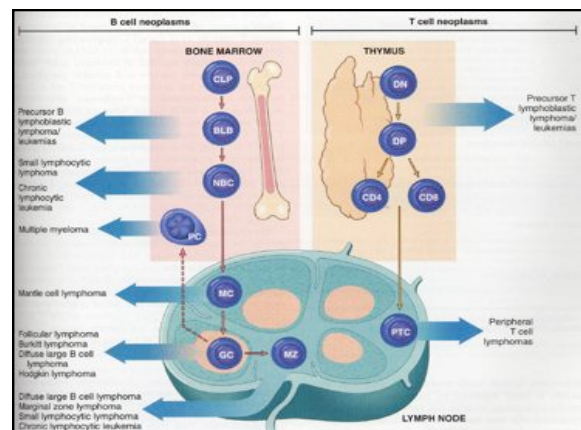
- **Classification of NHLs, cont.:**
- * **Revised European American Lymphoma (REAL) Classification (1994):**
This classification system recognizes specific (real) disease entities based on immunophenotypic, cytogenetic, and molecular features, as well as conventional morphology.

Non-Hodgkin Lymphoma

- **WHO Classification (2001):**
An updated version of the REAL classification..
- Expanded the principles of the REAL classification to the classification of the myeloid and histiocytic neoplasms..
- Replaced existing classifications..
- The first international consensus..

WHO Classification

- **Precursor (immature) B- and T-cell Lymphoid Neoplasms (leukemia/lymphoma):**
Precursor lymphoblastic leukemia/lymphoma
- **Mature (peripheral) B- and T-cell Lymphoid Neoplasms:**
Mature B-cell lymphomas
Mature NK/T-cell lymphomas



WHO Classification

- Immunodeficiency Associated Lymphoproliferative Disorders:
 1. Lymphoproliferative diseases associated with primary immune disorders
 2. Lymphomas associated with infection by HIV
 3. Post-transplant lymphoproliferative disorders
 4. Methotrexate-associated lymphoproliferative disorders

Non-Hodgkin Lymphoma

- Clinical manifestations of NHL:
 - 1- Lymphadenopathy..
 - 2- Organomegaly (infiltration of organs)..
 - 3- Systemic/B symptoms (fever, night sweats, weight loss)..

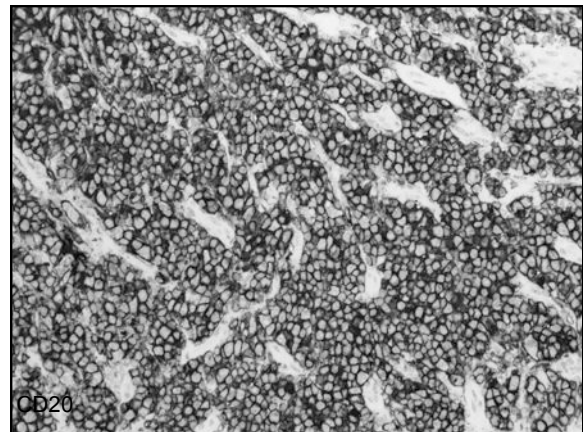
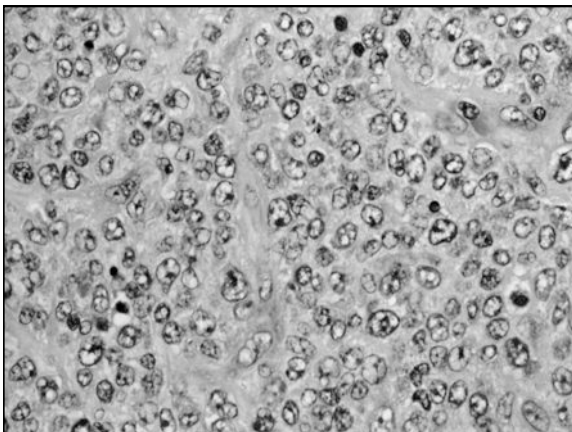
Non-Hodgkin Lymphoma

- *Examples of NHL:*
 - Diffuse Large B-cell Lymphoma (DLBCL), most common lymphoma in the western hemisphere**
 - Follicular Lymphoma (FL)**
 - Burkitt Lymphoma (BL)**

Non-Hodgkin Lymphoma

- Diffuse Large B-cell Lymphoma**

A diffuse proliferation of large neoplastic B lymphoid cells with a nuclear size equal to or exceeding normal macrophage nuclei or more than twice the size of a normal lymphocyte



Recent studies using gene expression profiling (GEP) in DLBCL have identified patterns of gene expression, as well as individual genes that appear to have important prognostic significance, related to underlying tumor biology.

At least two types:

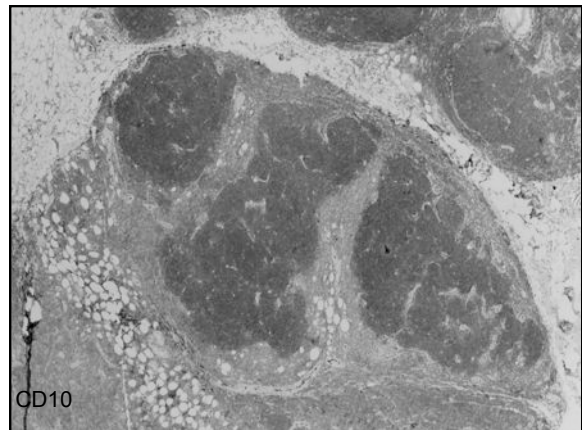
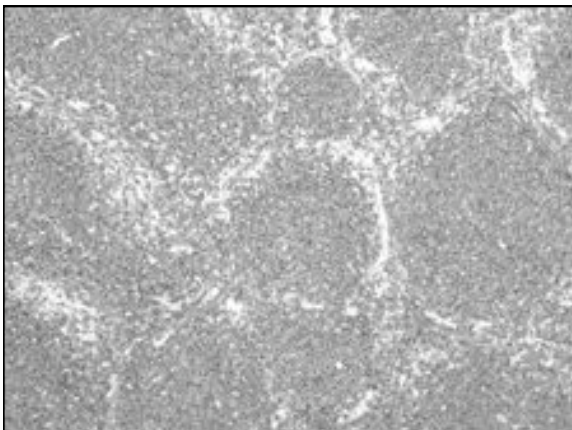
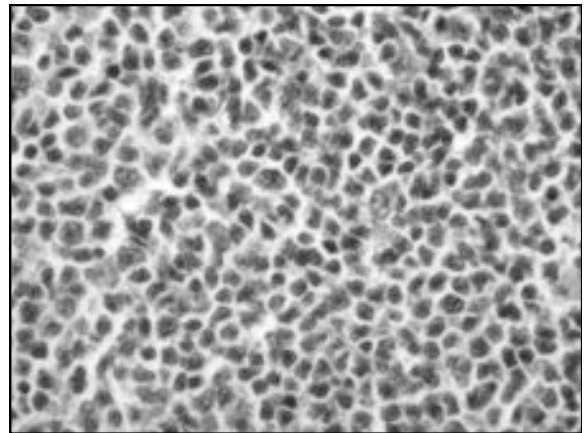
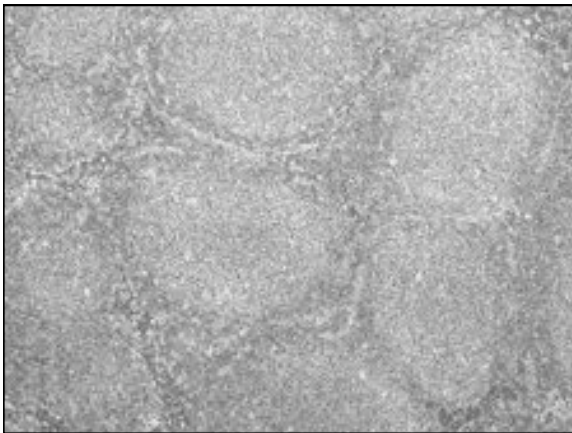
1- DLBCL of germinal center cell origin
CD10+ and/or BCL-6+

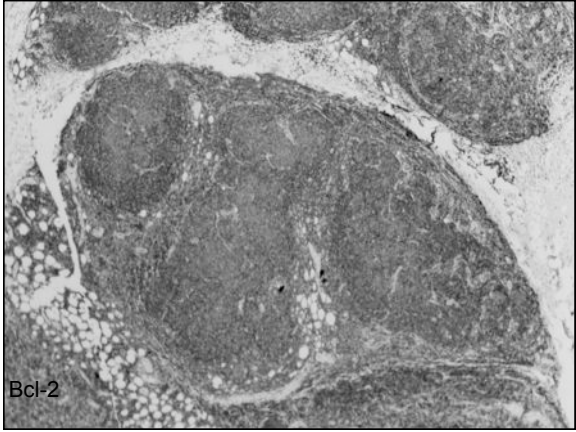
2- DLBCL activated B-cell like
CD10- and MUM1+

Non-Hodgkin Lymphoma

Follicular Lymphoma

A neoplasm of follicle center B cells (a mixture of centrocytes/centroblasts), which has at least a partially follicular/nodular pattern of growth

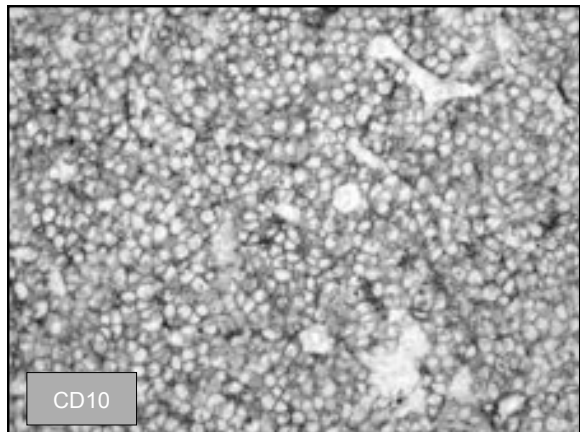

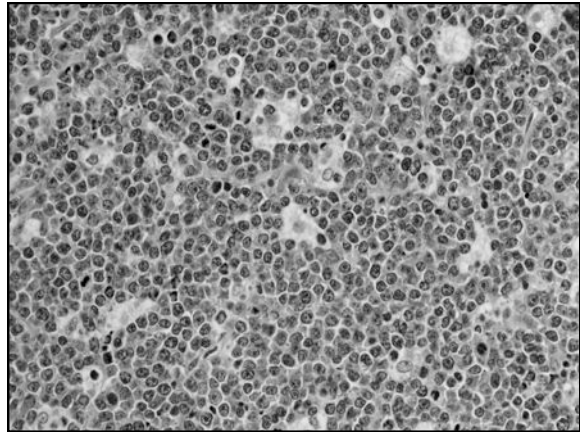
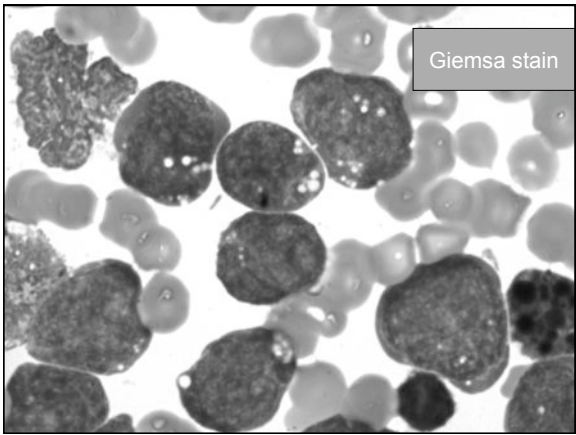




Non-Hodgkin Lymphoma

Burkitt Lymphoma

A highly aggressive lymphoma often presenting at an extra-nodal site or in a leukemic phase, composed of monomorphic medium-sized B-cells with basophilic/vacuolated cytoplasm and numerous mitotic figures



Non-Hodgkin Lymphoma

- **Therapy of NHL:**
 - 1- Chemotherapy
 - 2- Radiotherapy
 - 3- Combined chemo- and radiotherapy
 - 4- Immune therapy: antibodies raised against B-cell antigens (anti- CD20/anti-CD22 antibodies)

Hodgkin Lymphoma

- **Definition:**

Lymphoid neoplasm with a minority of neoplastic lymphoid cells (**Hodgkin cells**) in a predominant inflammatory/reactive background which may mask the tumor cell population

Hodgkin Lymphoma

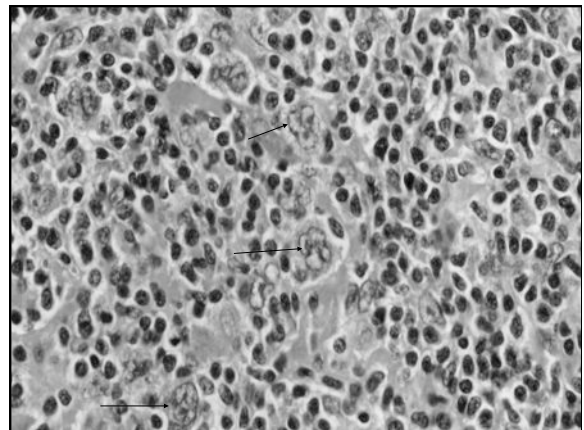
- **Epidemiology & Etiology :**
 - accounts approximately for 30% of all malignant lymphomas
 - bimodal age distribution
 - EBV has been postulated to play a role in the pathogenesis of classical HL

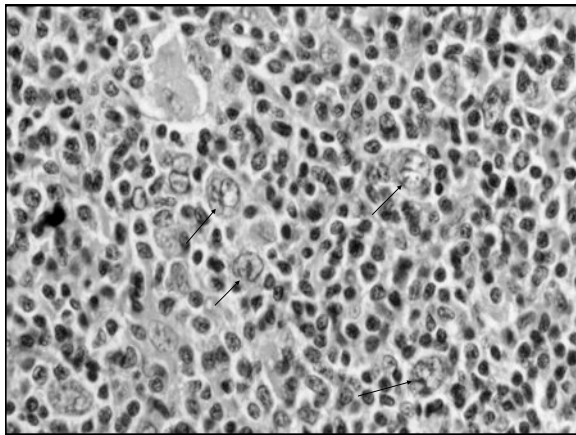
Hodgkin Lymphoma

- **WHO Classification of HL:**
 - 1- *Nodular Lymphocyte Predominance*
 - 2- *Classical Hodgkin Lymphoma*

Hodgkin Lymphoma

- **Nodular Lymphocyte Predominance:**
 - uncommon variant (6% of HL)
 - characteristic nodular pattern of growth
 - characteristic variant of Hodgkin cells (known as “popcorn” cells), which are CD20 positive B-cells of follicle center cell origin (CD10+, Bcl-6+)





Hodgkin Lymphoma

Classical Hodgkin Lymphoma:

- Nodular sclerosis (NSHL)
- Mixed cellularity (MCHL)
- Lymphocyte depletion (LDHL)
- Lymphocyte-rich classical Hodgkin lymphoma (LRCHL)

Hodgkin Lymphoma

Classical Hodgkin Lymphoma:

Hodgkin cells: derived from mature B-cells at the germinal center stage of differentiation

- typical Reed-Sternberg cells (binucleated cells)
- variants (mono- and multinucleated forms and lacunar cells)

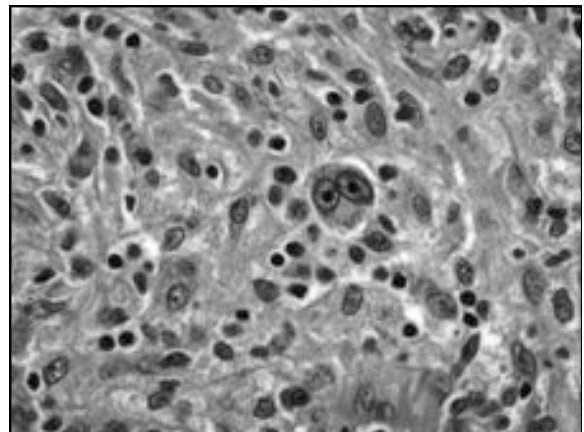
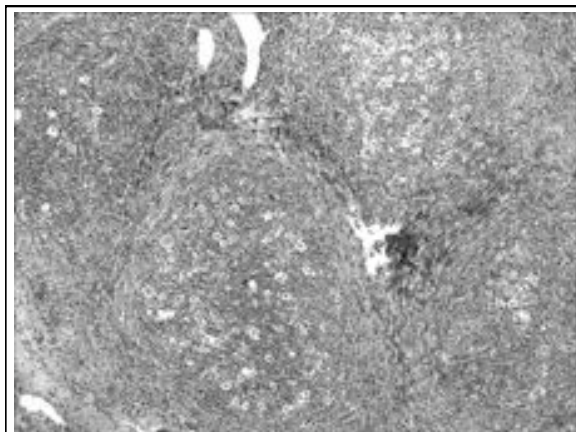
Immunophenotype: CD30+, CD15+, Pax5+, and CD45 negative

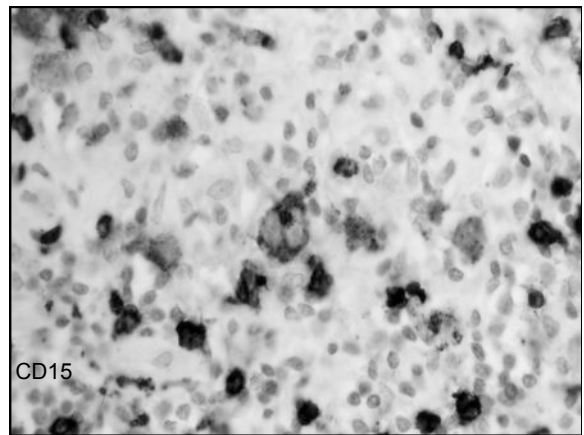
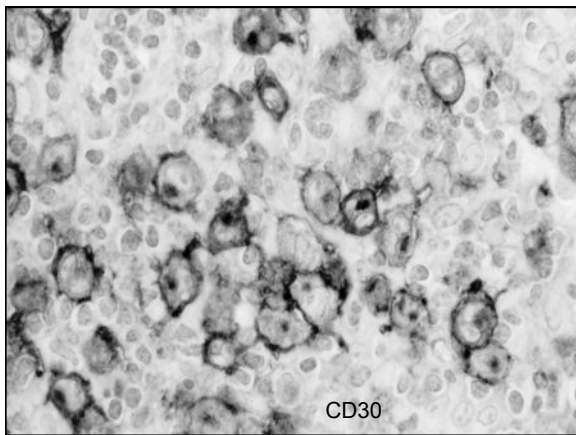
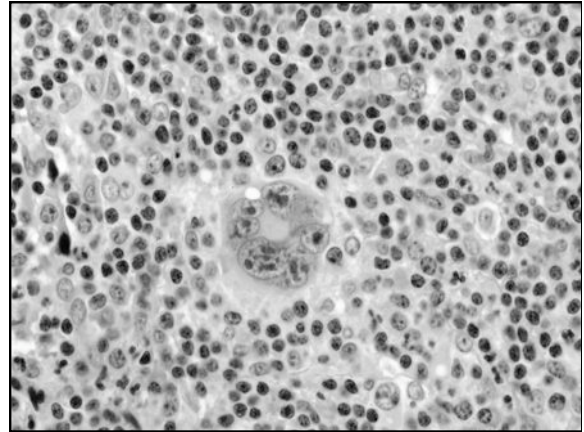
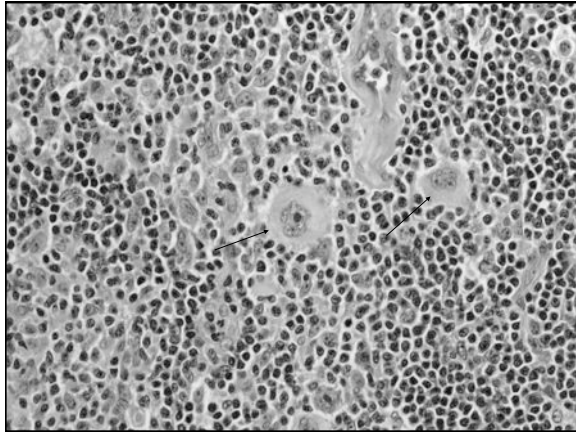
Hodgkin Lymphoma

Classical Hodgkin Lymphoma:

Nodular sclerosis (NSHL):

- characterized by Reed-Sternberg cells and **lacunar cells** within a polymorphic reactive background, and a characteristic **fibrosis** (bands of collagen surrounding nodules)





Hodgkin Lymphoma

Classical Hodgkin Lymphoma:

Mixed cellularity (MCHL):

- classical Reed-sternberg cells in a mixed, polymorphic background; no lacunar cells or collagen bands

Lymphocyte depletion (LDHL):

- uncommon subtype
- rich in Hodgkin's cells

Hodgkin Lymphoma

- **Clinical manifestations of HL:**
 - 1- **Lymphadenopathy**
 - 2- **Organomegaly** (infiltration of organs)
 - 3- **Systemic/B symptoms** (fever, night sweats, weight loss)

Hodgkin's Lymphoma

- **Therapy of HL:**
 - 1- **Chemotherapy**
 - 2- **Radiotherapy**