

*Pneumocystis jirovecii* and *Toxoplasma gondii*:  
A Tale of Two Parasites or  
**Opportunistic Infections In Immuno-deficient Hosts**

Charles Knirsch, MD, MPH

## Protozoan Parasites

1. *Toxoplasma gondii*

2. The Malariae

*Plasmodium falciparum*

*Plasmodium vivax*

*Plasmodium ovale*

*Plasmodium malariae*

3. Diarrheal disease-causing protozoa:

*Giardia lamblia*

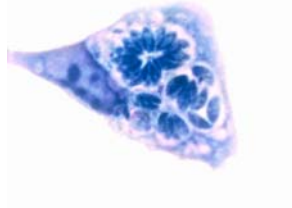
*Entameba histolytica*

*Cryptosporidium parvum*

*Cyclospora cayetanensis*

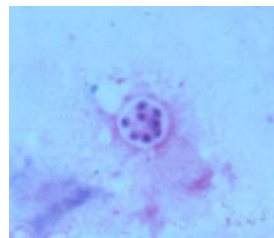
# Protozoa:

*Toxoplasma gondii*




and

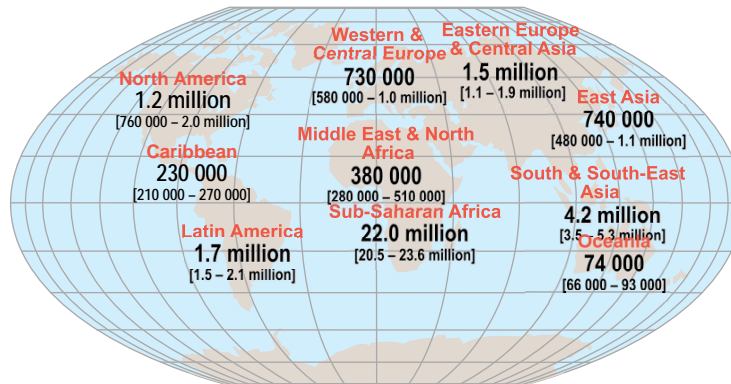
*Pneumocystis jirovecii*\*  
formerly *P. carinii*



\*actually an unusual fungus



## Adults and children estimated to be living with HIV, 2007

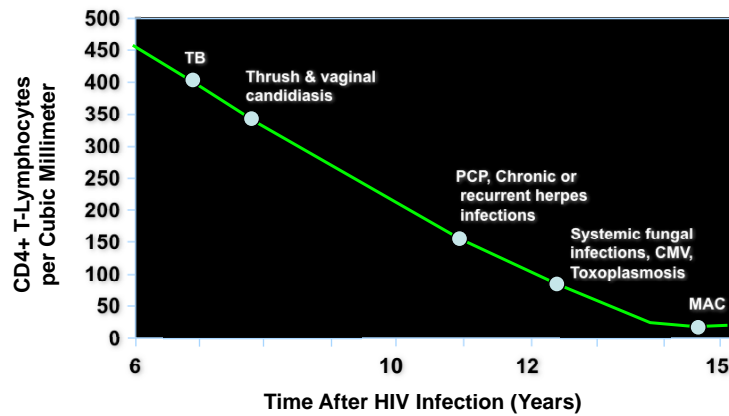


**Total: 33 million (30 – 36 million)**

## And the Band Played On

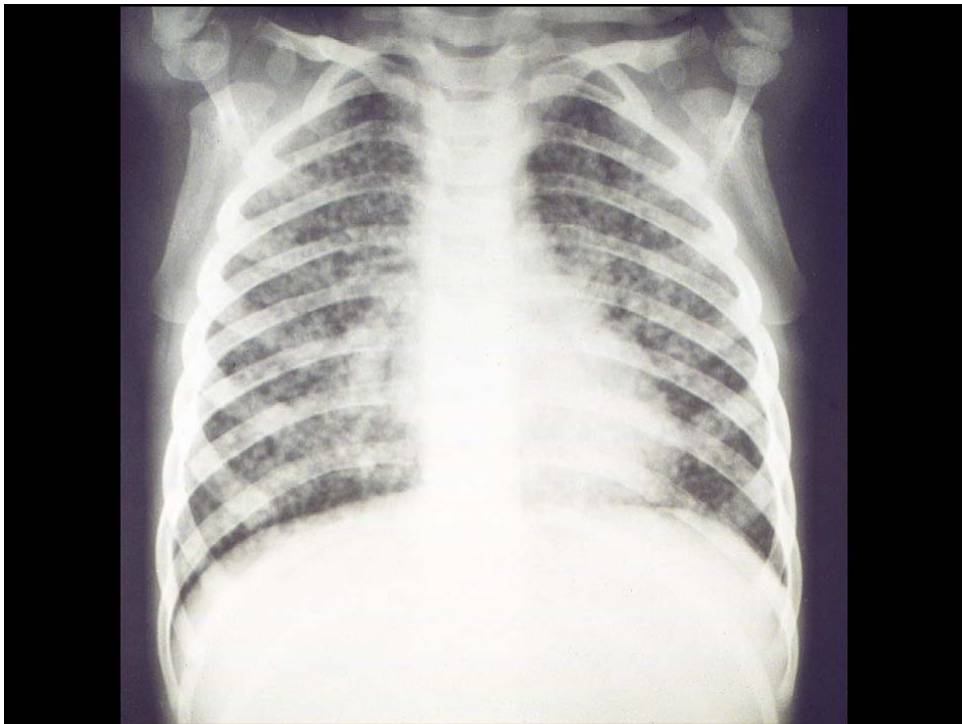
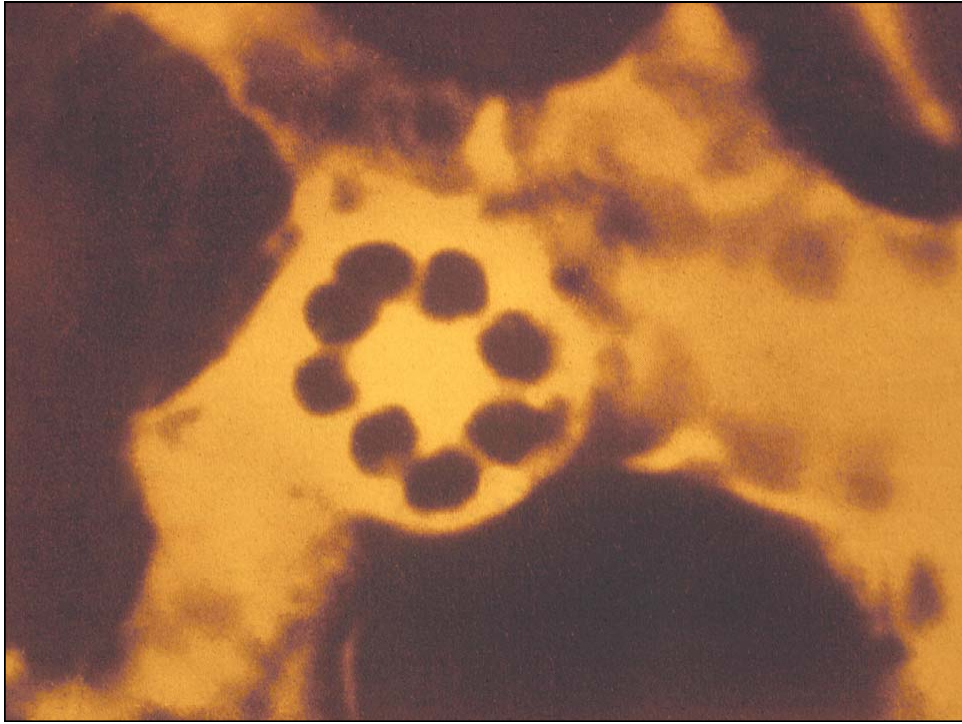
- Politics, people and the AIDS epidemic
- CDC April 1981: “This guy should go back to medical school if he can’t find some simple neoplasm”
- June 1981 MMWR: Pneumocystis pneumonia in young men
- GRID

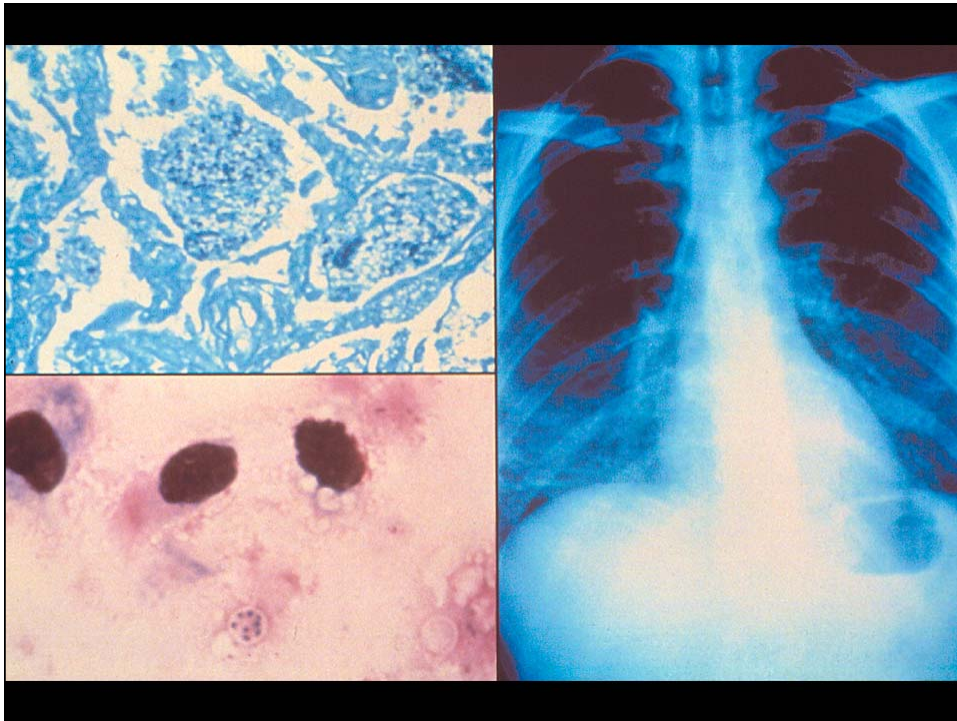
## Opportunistic Infections Associated with Progressive Immunodeficiency



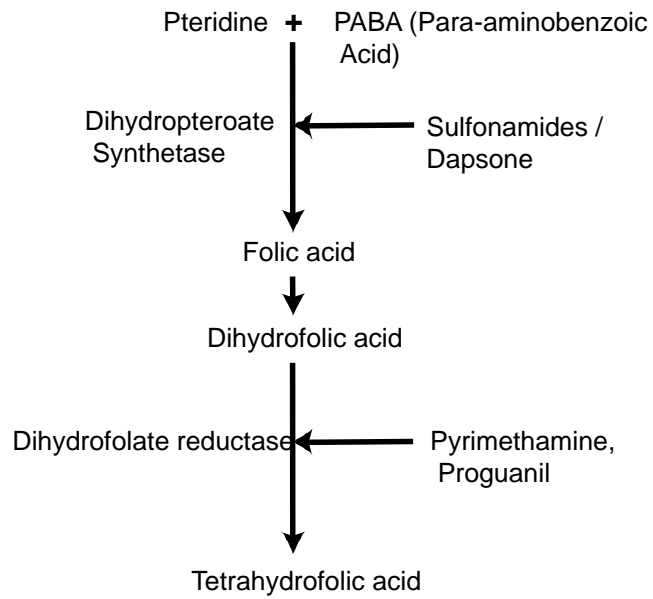
## Pneumocystis jirovecii (PCP)

- Commensal organism and opportunistic pathogen
- Morphologically resembles protozoan
- Difficult to grow in vitro
- Life cycle???
  - Cyst stage : 5 um in diameter with 4-8 sporozoites
  - Trophozoite : 2-5 um in diameter – attach to cell surfaces





### Folic Acid Inhibitors are Drugs of Choice for PCP



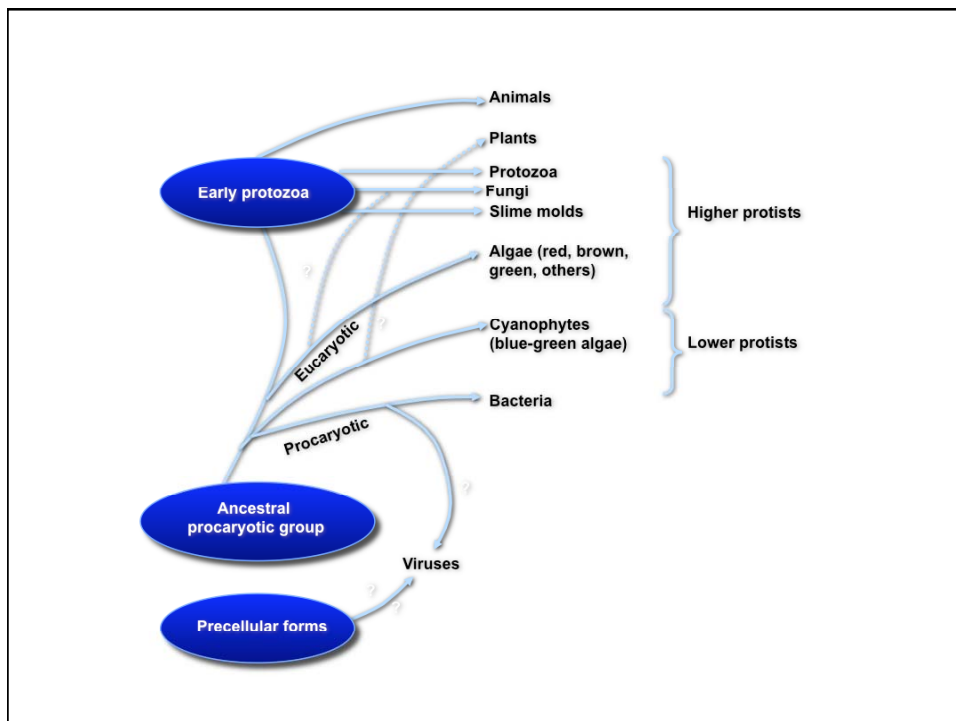
# Is *P. carinii* a Fungus or Protozoon?

## Protozoon

- Morphology
- Inability to culture in vitro
- Response to anti-protozoal drugs

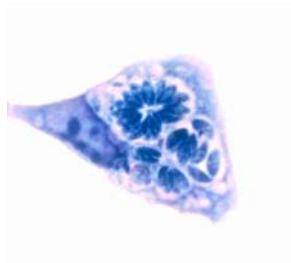
## Fungus

- Ribosomal rRNA sequence homology
- ELF3

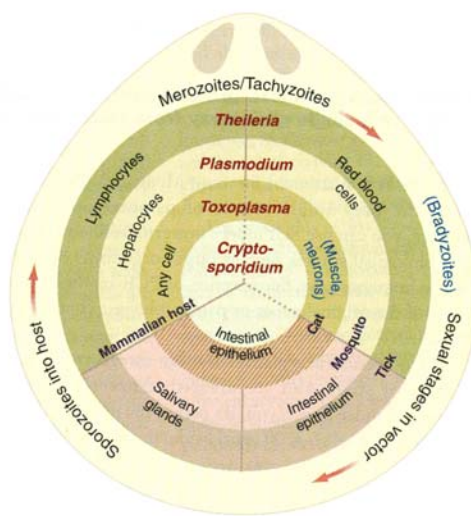


# Protozoa:

*Toxoplasma gondii*

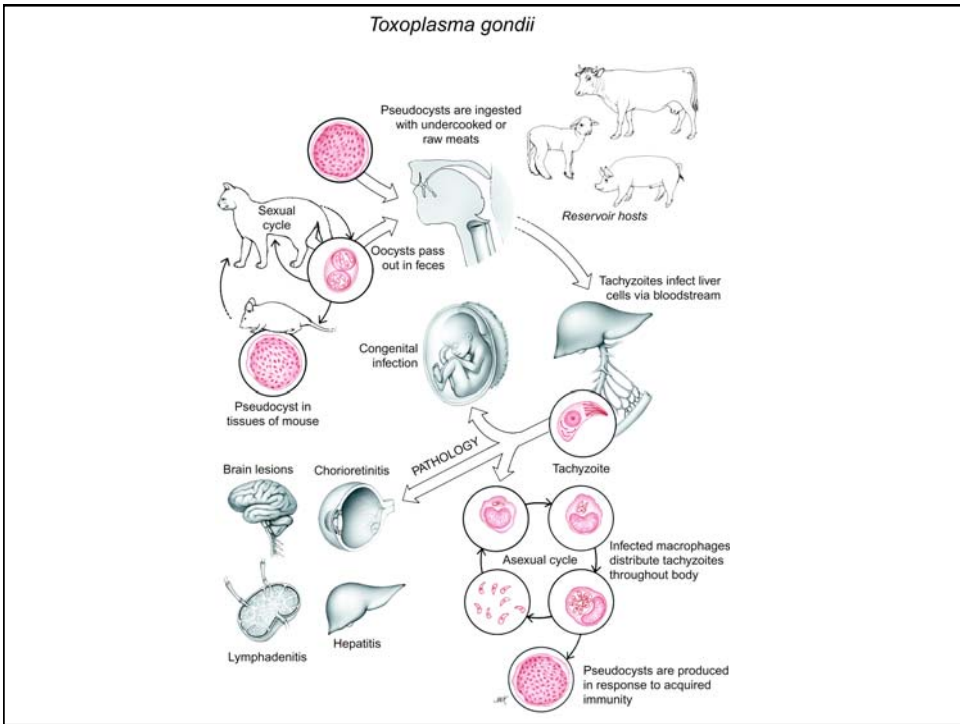
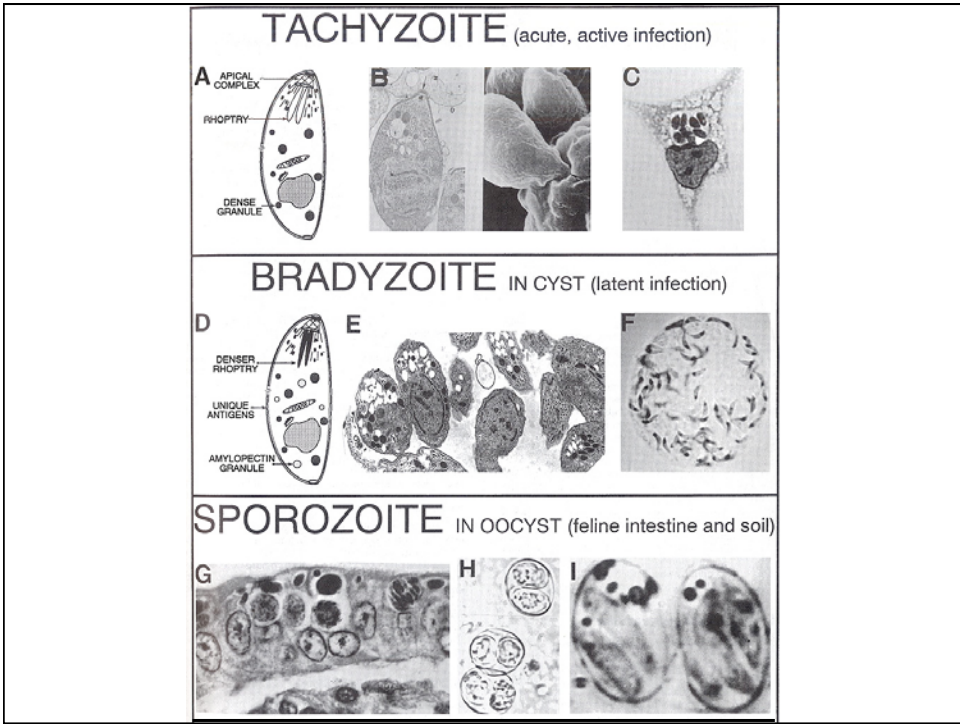


# The Apicomplexa



*Toxoplasma gondii*  
The Plasmodia (malaria)  
*Cryptosporidium parvum*

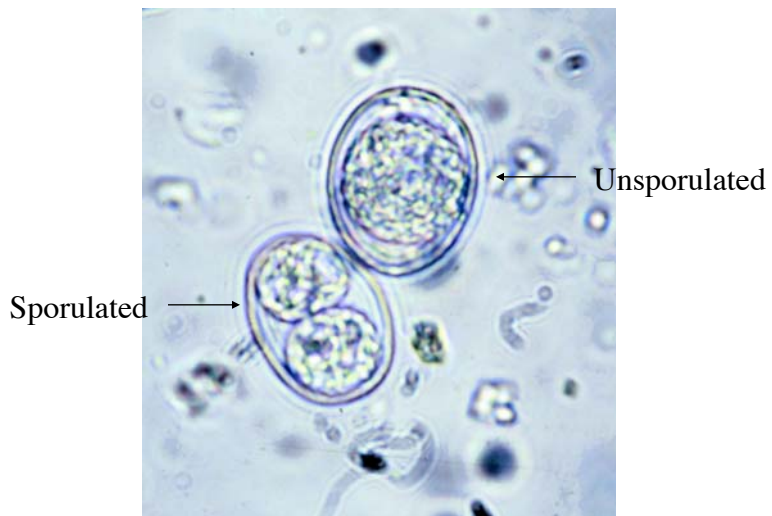



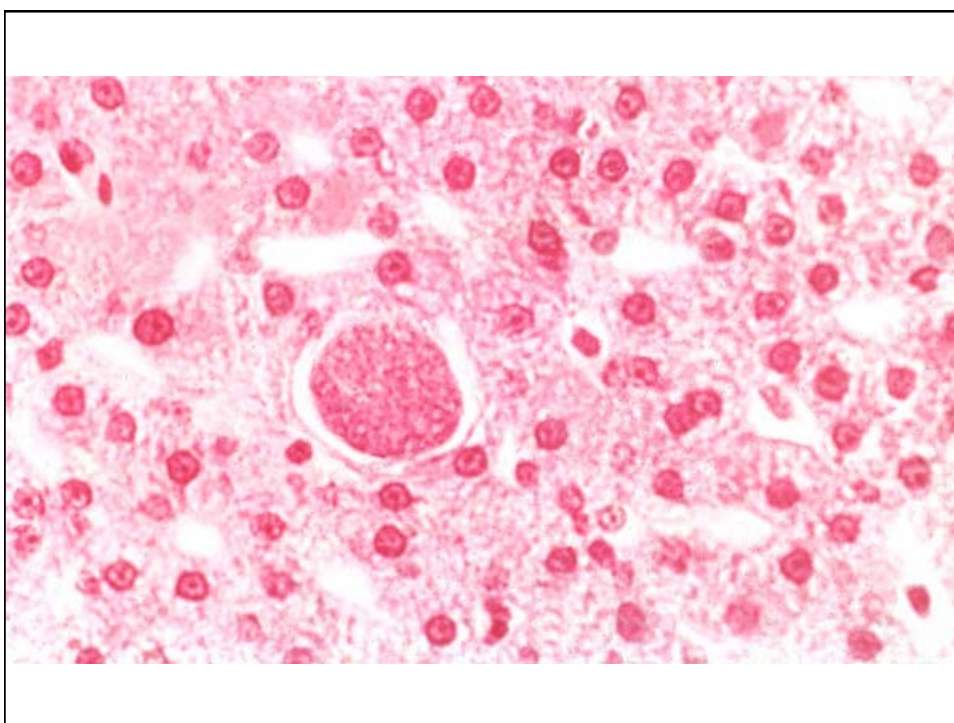
Felines are the definitive hosts for *Toxoplasma gondii*



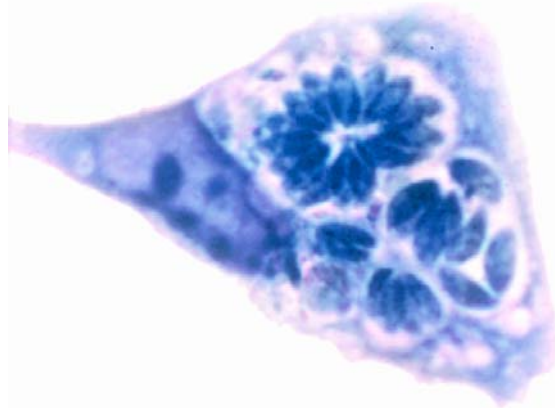
Oocysts of *Toxoplasma gondii*



Rack of lamb is usually served rare

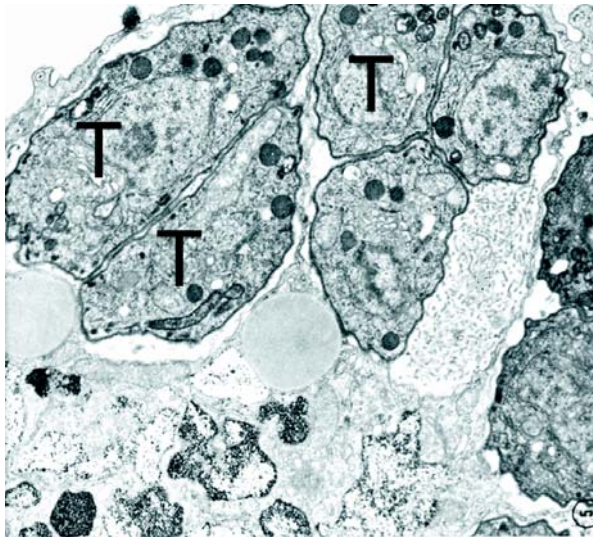


Macrophage Infected With *Toxoplasma gondii*\*



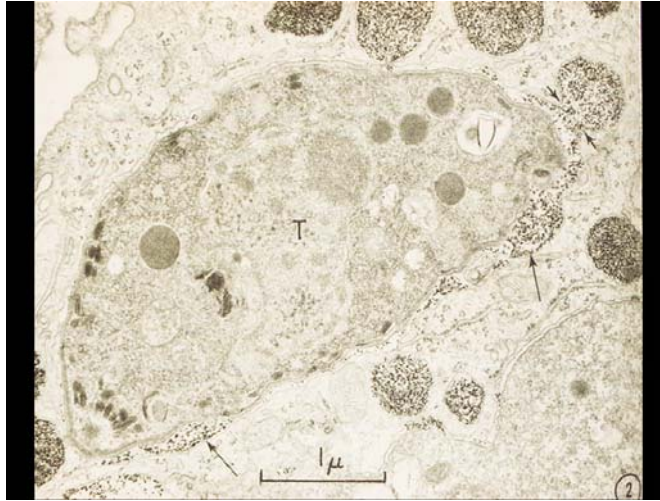
\* The hunter becomes the hunted

*Toxoplasma gondii* in culture



Trophozoites (T) prevent fusion of lysosomal membranes to the parasitophorous vacuole, thereby escaping digestion

## *Toxoplasma gondii* in culture



Heat-killed organisms cannot prevent fusion of lysosomal membranes with the parasitophorous vacuole

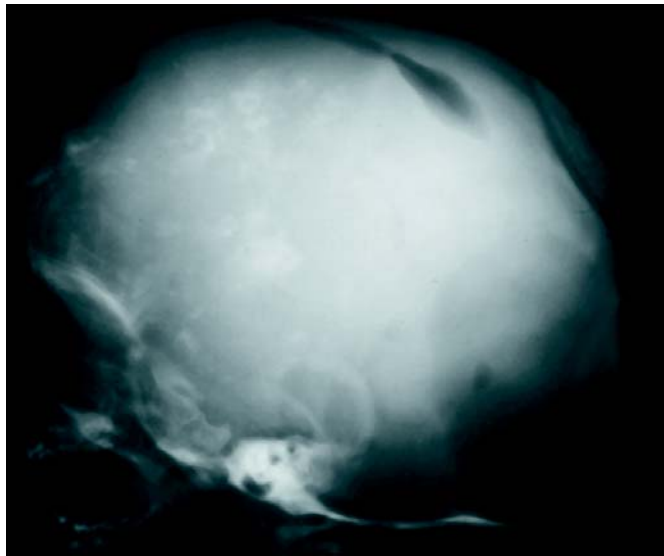
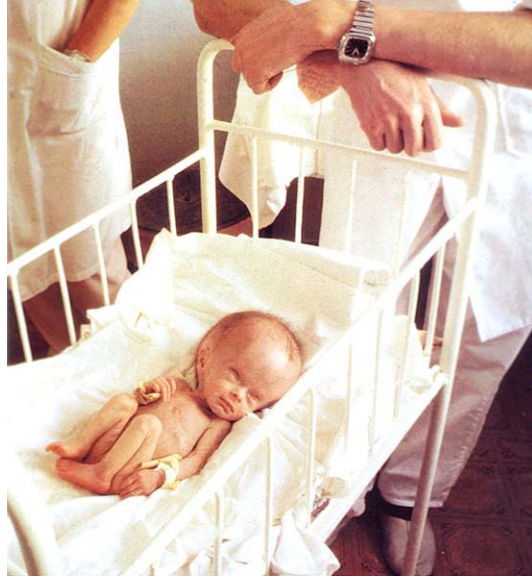## Clinical Disease:

Congenital

Adult-acquired

AIDS-related

*Congenital Toxoplasmosis*



## *Congenital Toxoplasmosis*

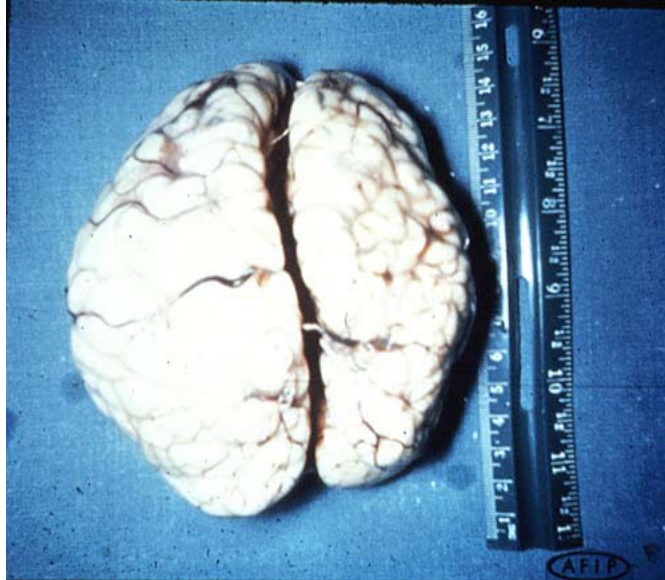


Photo courtesy: Gary Baumbach, M.D., Department of Pathology, University of Iowa College of Medicine

## Congenital Toxoplasmosis:

Still Birth

Chorioretinitis

Mental Retardation

## Congenital Toxoplasmosis Following Maternal Infection During First and Second Trimester\*

---

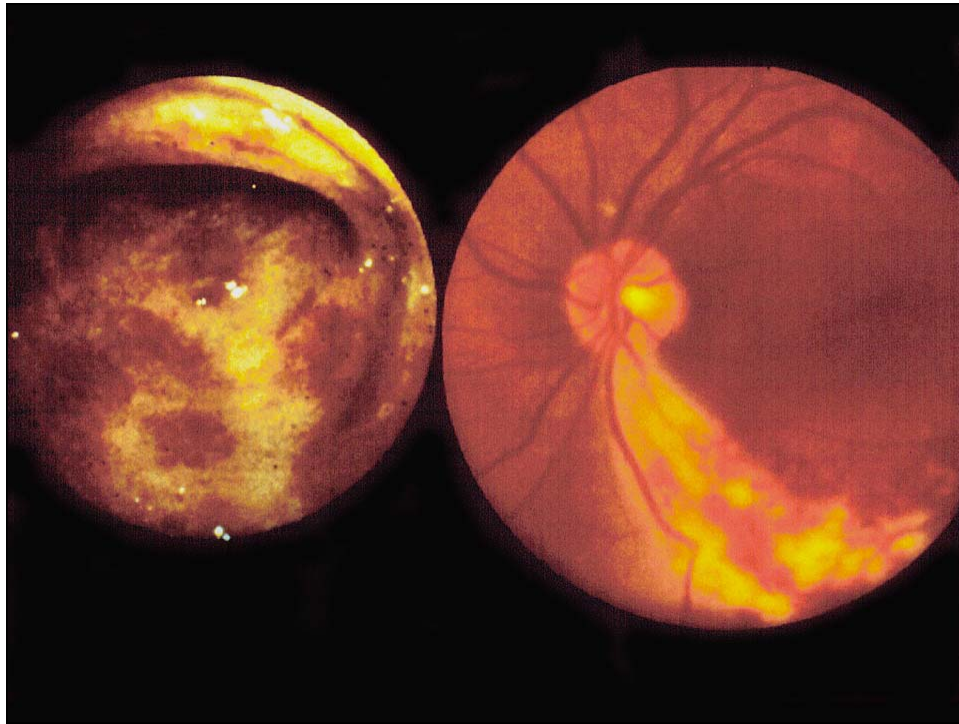
Not Infected	73%
Subclinical Infection	13%
Mild Infection	7%
Severe Infection	6%

---

\* From Desmonts and Couvier, NEJM 290: 1110, 1974

## Toxoplasma Ocular Disease

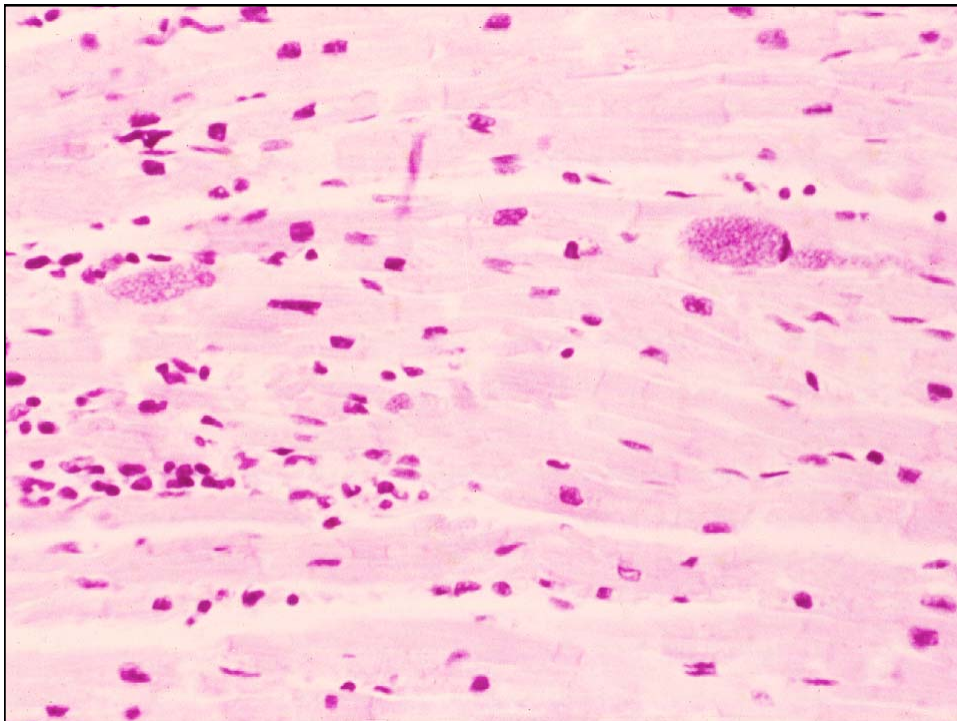
- Usually from congenital infection manifesting in adults
  - Episodic flares may destroy retinal tissue
  - Specific treatment necessary



## Adult-Acquired Toxoplasmosis

## Infection by Blood or Organ Transplant

- Parasitemia (WBC's) for up to 1 year post infection
- Heart, bone marrow, liver, kidney donors
  - Dangerous when recipient toxo (-)
- Myocarditis, diffuse lymphadenopathy



## Adult-Acquired Toxoplasmosis

### Signs and symptoms:

Lymphadenopathy

Fever

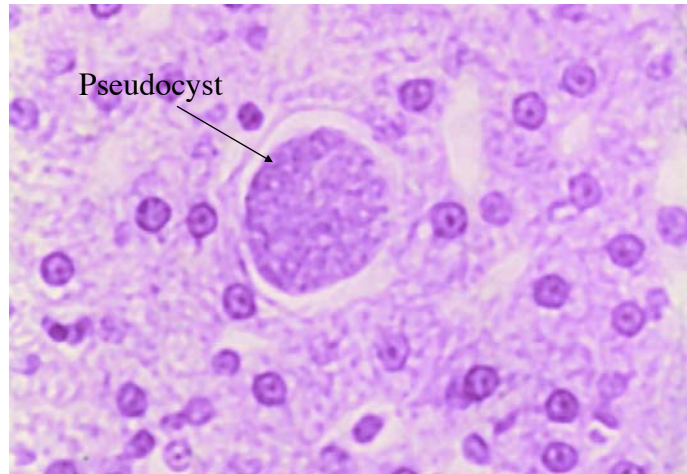
Headache

Chronic Malaise

## Differential Diagnosis of Lymphadenopathy

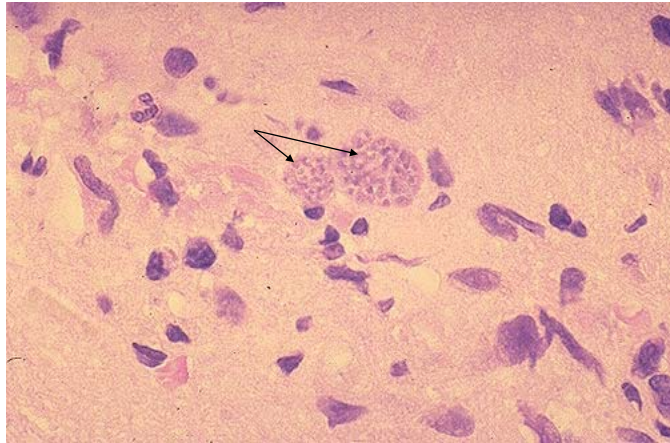
	<i>Toxoplasmosis</i>	<i>Inf. Mono</i>	<i>Lymphoma</i>
<b>Lymphadenopathy Without Other Symptoms</b>	+++	+	+++
<b>Pharyngitis</b>	+	+++	+
<b>Monocytosis, Eosinophilia</b>	+++	+	+++
<b>Atypical Lymphocytes</b>	+	++++	+
<b>Anemia</b>	0	+	+++
<b>Positive Heterophil</b>	0	++++	0
<b>Altered Liver Function</b>	0	++++	++
<b>Hilar Lymphadenopathy</b>	+	+	+++
<b>Lymph Node Pathology</b>	Reticulum Cells	Germinal Cells	Bizarre Cells

## Pseudocyst of *Toxoplasma gondii* in Liver



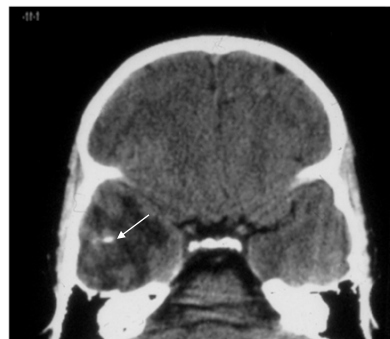## AIDS-related Disease

Pseudocysts of *Toxoplasma gondii* in a microglial nodule with a variety of inflammatory cell types in an HIV/AIDS patient

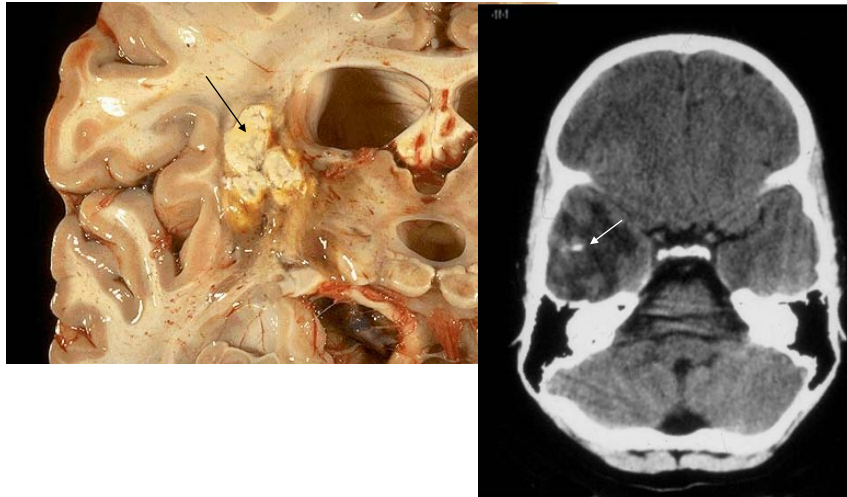


### AIDS-related Disease:

1. CD4 < 200 and reactivation of latent infection
2. Encephalitis
  1. Diffuse inflammation and swelling
  2. Localized ring enhancing lesions on CT scan
  3. Herniation
  4. Death if untreated



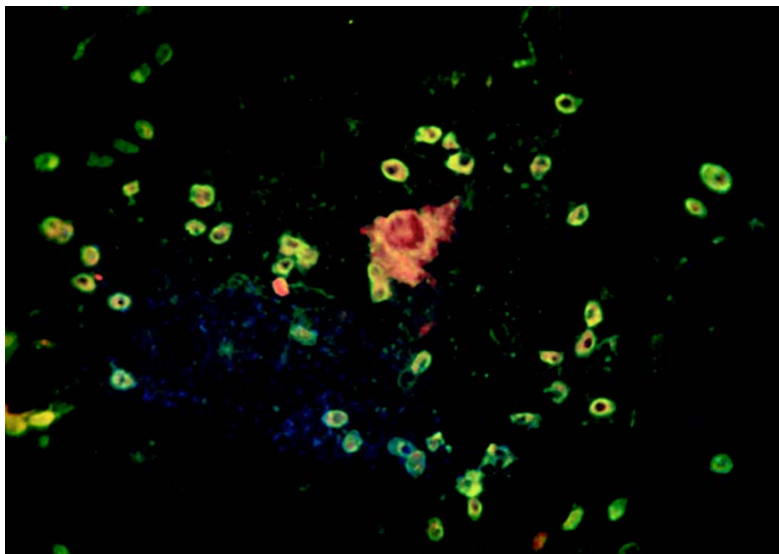
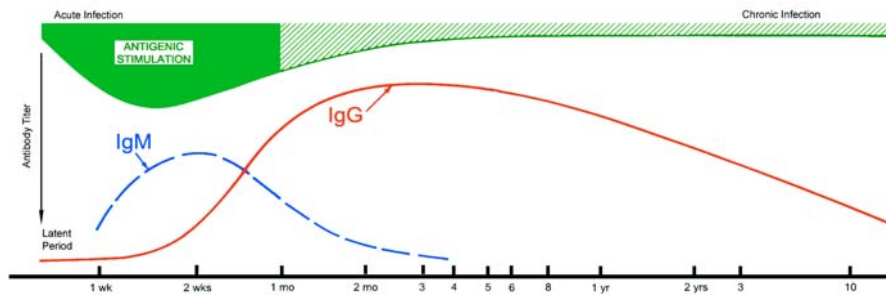
Toxoplasma abscess in the brain would appear as a ring-enhancing lesion with CT scan.



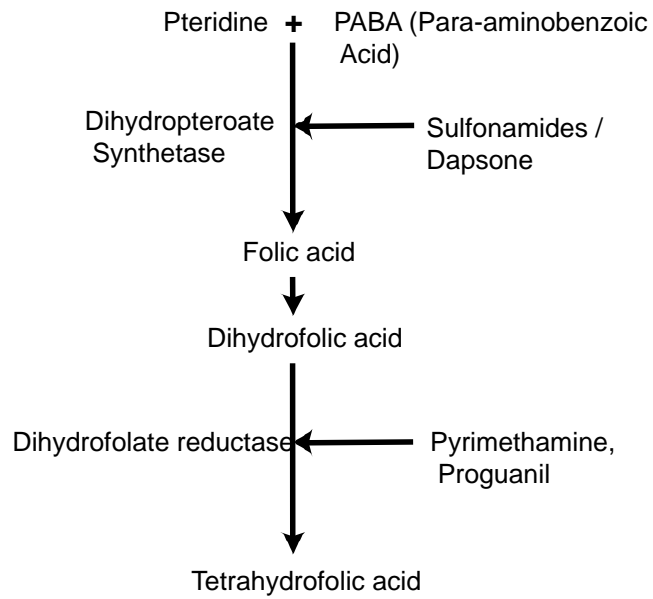
CT Scan

Diagnosis

## Serological correlates in acute and chronic infection



## Folic Acid Inhibitors are Drugs of Choice



## Prevention:

1. Prevent pregnant women from handling cat litter
2. Avoid eating raw or under-cooked meats



Trained cat



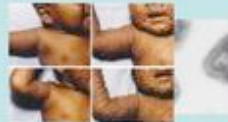Automated litter collection box

## Host status

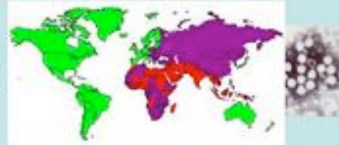- *Pneumocystis carinii*
  - No Life cycle!
  - Lung disease in AIDS
  - Malnourished children
  - Organ Transplants
- *Toxoplasma gondii*
  - Cat definitive host
  - Disease: Host status
  - CNS Disease in AIDS
  - Congenital Infections
  - Organ Transplants

## Some Good News Regarding Extinction:

Smallpox - eliminated  
(probably)



Polio - nearly gone



Yaws - almost eliminated



Onchocerciasis - on its way out



## The Most Common Neglected Infections of Poor People

Disease	Number of Cases	Population at-risk
Ascariasis	807 million	4.2 billion
Trichuriasis	604 million	3.2 billion
Hookworm	576 million	3.2 billion
Amebiasis	500 million	ND
Schistosomiasis	200 million	0.6 billion
<b>Lymphatic Filariasis</b>	<b>120 million</b>	<b>1.0 billion</b>
Trachoma	84 million	0.5 billion
<b>Onchocerciasis</b>	<b>18 million</b>	<b>0.1 billion</b>
<b>Chagas Disease</b>	<b>16 million</b>	<b>0.1 billion</b>
<b>Leishmaniasis</b>	<b>12 million</b>	<b>0.4 billion</b>
Leprosy	0.4 million	ND
<b>Dracunculiasis</b>	<b>0.01 million</b>	<b>ND</b>

## Global Network for Neglected Tropical Diseases

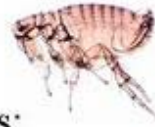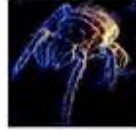<http://www.GNNTDC.org>

- Schistosomiasis Control Initiative
- International Trachoma Initiative
- Helen Keller International
- Liverpool School - GAELF
- Human Hookworm Vaccine Initiative
- Earth Institute at Columbia Univ.
- Task Force for Child Survival
  - Mectizan Donation Program
  - Albendazole Donation Program
  - Mebendazole Donation Program



**GNNTDC**  
 GLOBAL NETWORK  
 FOR NEGLECTED TROPICAL  
 DISEASE CONTROL





More Bad News:

Most vector-borne diseases are on the rise

