

Information Gathering and Diagnosis Development

CHAPTER OUTLINE

Overview of the Diagnostic Process

Information Gathering

Patient History

Techniques for Obtaining a Patient History

Questionnaires and Forms

Patient Interviews

Components of a Patient History

Demographic Data

Chief Complaint and History

General Health History

Oral Health History

Psychosocial History

Clinical Examination

Physical Examination

Intraoral and Extraoral Examination

Periodontal Examination

Examination of the Teeth

Occlusion

Radiographic Examination

Other Diagnostic Aids

Study Casts

Diagnostic Wax-Ups and Altered Casts

Occlusal Splints

Caries Excavation

Consultations

Medical Laboratory Tests

Biopsy

Microbiologic and Other Testing Systems

Developing Diagnoses and Problem Lists for Patients

Benefits of Creating Diagnosis and Problem Lists

Common Diagnoses

General Health Diagnoses

Psychosocial Diagnoses

Intraoral/Extraoral Diagnoses

Periodontal Diagnoses

Dental Diagnoses

Pulpal and Periapical Diagnoses

Documentation

Accurate diagnostic information forms the foundation of any treatment plan. This information comes from several sources: the patient history, radiographs, and the clinical examination. The dentist must critically analyze the information before recommending treatment options to the patient. The goal of this chapter is to discuss both the types of data that the dentist in general practice typically collects and the ways in which the dentist evaluates and documents this information in preparation for creating a treatment plan.

OVERVIEW OF THE DIAGNOSTIC PROCESS

The diagnostic process is begun by gathering information about the patient and creating a **patient database** from which all future decisions will be made. Although the components of each patient's database vary, each includes pieces of information, or **findings**, that come from asking questions, reviewing information on forms, observing and examining structures, performing diagnostic tests, and consulting with physicians and other dentists.

Findings fall into several categories. **Signs** are findings discovered by the dentist during an examination. For instance, the practitioner may observe that a patient has swollen ankles and difficulty in breathing when reclined, signs suggestive of congestive heart failure. Findings revealed by the patients themselves, usually because they are causing problems, are referred to as **symptoms**. Patients may report such common symptoms as pain,

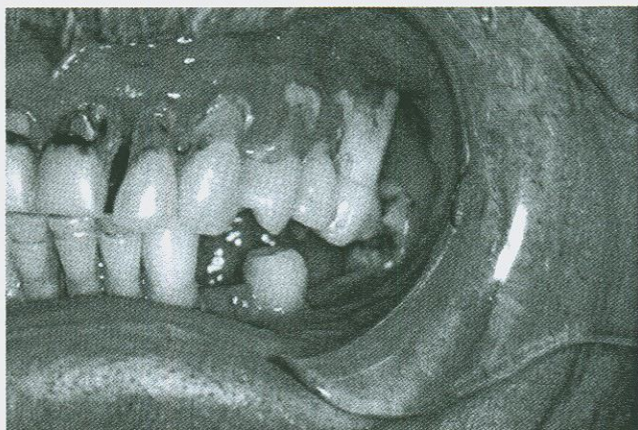


Figure 1-1 This patient reported symptoms of tooth pain and bleeding gums. Many signs—dark teeth, receding gingival tissue, and poor oral hygiene—suggest serious dental problems.

swelling, broken teeth, loose teeth, bleeding gums, and esthetic concerns. When a symptom becomes the motivating factor for a patient to seek dental treatment, it is referred to as the **chief complaint** or **chief concern**. Patients who are new to a practice often have one or more chief complaints (Figure 1-1).

The clinician must evaluate findings individually and in conjunction with other findings to determine whether or not the finding is significant. For example, the finding that a patient is being treated for hypertension may be not be significant alone, but when accompanied by another finding of blood pressure measuring 180/110 mm Hg, the level of importance of the first finding increases. Questions arise as to whether the patient's hypertension is being managed appropriately or whether the patient is even taking the prescribed medication regularly. Obviously, further questioning of the patient is in order, generating even more findings to evaluate for significance. The process of differentiating *significant* from *insignificant* findings can be challenging for dental students and recent graduates. For example, a student may believe a dark spot on the occlusal surface of a tooth to be significant, while a faculty member might discard the finding as simply stained fissure, not requiring treatment. Thankfully, this differentiation and selection process becomes easier as the dentist gains experience from treating more and more patients.

The process of discovering significant findings leads to a list of diagnoses or patient problems that ultimately forms the basis for creating a treatment plan (Figure 1-2). Experienced practitioners may not always evaluate patients in a linear, sequential fashion. Instead, they move back and forth between discovering findings, evaluating

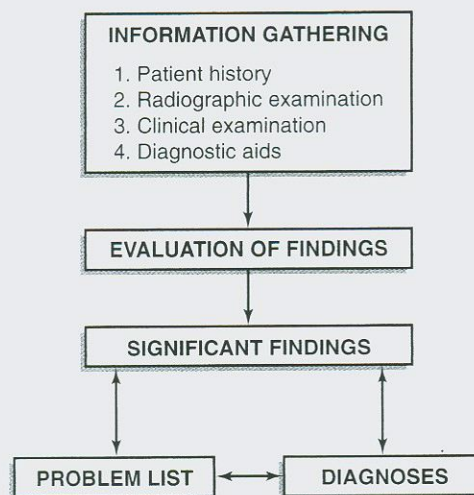


Figure 1-2 The pathway to reaching a diagnosis.

for significance, and making a diagnosis, and they may begin to think about treatment options before gathering all the data. Despite this normal process, the novice practitioner (and even the experienced one) is *highly* advised against giving treatment recommendations to patients before creating and analyzing the entire patient database. Typically, the patient initiates the discussion during the examination process. For example, examination of a sensitive tooth may elicit a query from the patient as to whether it can be saved and at what cost. Saying “yes” and “in two appointments” may prove embarrassing when subsequent radiographs reveal extensive decay and the need to extract the tooth. To prevent such errors, the inquisitive patient should be gently reminded that the examination is not yet complete and that more information will enable questions to be answered more completely.

INFORMATION GATHERING

Gathering information about the patient often requires more time and attention than any other aspect of treatment planning. To prevent missing important findings, the dentist should gather data in an organized, systematic manner. Each practitioner must develop a consistent and standardized mechanism for gathering historical information about the patient, obtaining radiographs, and performing the clinical examination. It is essential that any data gathered be both *complete* and *accurate*. If deficiencies occur in either completeness or accuracy, the validity of the final treatment may be suspect.

Dental Team Focus Information Gathering and the Oral Health Team

In addition to the dentist, other members of the oral health team in an office might include an administrative assistant, a dental hygienist, and a clinical assistant.

When a new patient walks into a dental practice, meeting the office administrative assistant will typically be the first direct contact with a dental health team member. This initial interaction marks the beginning of the information gathering process for and about this patient.

The administrative assistant must be well organized and prepared to gather the following information components to prepare the patient for the clinical phase of the examination and the diagnostic stage. The administrative assistant may be responsible for:

- Reviewing the demographic and health history forms to ensure that they have been completed correctly.
- Recording the information from the demographic and medical/dental history forms and compiling the patient's computerized or paper dental record.
- Reviewing privacy forms with the patient for acceptance and signature.
- Collecting and recording dental insurance information.

The clinical assistant will assist the dentist and the dental hygienist in the clinical phase of the information gathering process through the following tasks:

- Reviewing the completed medical/dental history forms with the patient and initiating an open dialogue about the patient's general health and previous dental care
- Answering questions and making notes briefly describing patient concerns and questions for the dentist's review
- Recording medical alerts in the patient record
- Taking and recording the patient's base-line vital signs, typically including pulse rate and blood pressure
- Obtaining prescribed dental radiographs, which may include periapical, bite-wing, full mouth, occlusal, or panoramic radiographs
- Recording and charting the intraoral and extraoral examinations on the clinical examination form as the dentist dictates findings
- Taking and pouring up preliminary impressions for study casts

The sheer number of findings that arise when evaluating a patient with a complicated health history or many dental problems can overwhelm the beginning practitioner. Staying focused on each stage of information gathering and being careful to record information in an organized fashion for later analysis help prevent confu-

sion. This section covers the four major categories of information required to begin developing a treatment plan: the patient history, clinical examination, radiographic examination, and other diagnostic aids.

Patient History

The distinguished Canadian physician Sir William Osler wrote, "Never treat a stranger." His words underscore the need for a thorough patient history; experienced dentists learn everything they can about their patients *before* beginning treatment. Obtaining a complete and accurate patient history is part of the art of being a doctor. It takes considerable practice and self-study to become a talented investigator. No set amount of historical information is required for each patient. The volume of information collected and the complexity of the data collection process naturally depend on the severity of the patient's problems. As more information comes to light, additional diagnostic techniques may need to be employed.

In dental offices, persons other than the dentist have access to patient information. The entire office staff should be aware of the confidential nature of patient information and cautioned about discussing any patient's general or oral health history other than for treatment purposes. The author is reminded of one example of a lapse in confidentiality. When updating the health history, a staff member learned that a patient had recently become pregnant. Later in the day, the patient's mother was in the office, and another staff member congratulated her on her daughter's pregnancy. At first the mother was elated, but later was hurt that her daughter had not told her herself. The incident provided an uncomfortable reminder of the importance of keeping patient information confidential both inside and outside the office.

In the United States, the Health Insurance Portability and Accountability Act of 1996, **HIPAA**, requires practitioners and health care organizations to prevent unnecessary use and release of protected health information (**PHI**). Patient PHI includes medical findings, diagnoses and treatment notes, and any demographic data that could identify the patient, such as an address, phone number, or personal identification number. HIPAA permits the use of a patient's PHI for treatment purposes, obtaining payment for services, and other organizational requirements, such as quality assurance activities or assisting legal authorities. Patients must be given, and sign, an acknowledgment that they have received information about how the practitioner or organization will use the PHI and who they can contact if they believe

their health information has been inappropriately used or released. Under HIPAA, a patient also has the right to inspect his or her medical records.

Techniques for Obtaining a Patient History

The two primary methods for obtaining the patient history are (1) questionnaires and forms and (2) patient interviews. A secondary method involves requesting information from another health care practitioner.

Questionnaires and Forms The use of questionnaires and forms during the examination process offers several advantages. Questionnaires save time, do not require any special skills to administer, and provide a standardized method for obtaining information from a variety of patients. Many types of forms are available commercially, or the practitioner can create his or her own.

Unfortunately, using a form to gather information has several disadvantages. The dentist only gets answers to the questions asked on the form, and important findings can be missed. The severity of a condition may not be reflected in a simple positive response. Patients may misinterpret questions, resulting in incorrect answers. It may be necessary to have the forms printed in other languages to facilitate information gathering. The more comprehensive the questionnaire is, the longer it must be, which can be frustrating to patients. Finally, patients can more easily falsify information on a questionnaire or form than when confronted directly in an interview.

Patient Interviews A major advantage of interviewing patients is that the practitioner can tailor questions to the individual patient. The patient interview serves a problem-solving function and functions quite differently from a personal conversation. There is a level of formality to the discussion, which centers on the patient's health and oral care needs, problems, and desires. To obtain accurate information and not influence the responses, the dentist must be a systematic and unbiased information gatherer. Being a good listener is key to facilitating information flow from the patient. The desired outcome of the interviewing process is to develop a good rapport with the patient by establishing a cooperative and harmonious interaction. If the interviewer does not speak the patient's language, it may be necessary to have a translator available. A sign language translator may be also required if the patient is hearing impaired.

The dentist can ask two general types of questions when interviewing: open and closed. **Open questions** cannot be answered with a simple response, such as "yes"

or "no." Instead, open questions get the patient involved and generate reflection by asking for opinions, past experiences, feelings, or desires. Open questions usually begin with "what" or "how" and should avoid leading the patient to a specific answer.

Examples:

How may I help you?

What do you think is your biggest dental problem?

Tell me about your past dental care.

Tell me more about your heart problems.

Closed questions, on the other hand, are usually simple to answer with one or two words. They permit specific facts to be obtained or clarified but do not give insight into patient beliefs, attitudes, or feelings.

Examples:

Do any of your teeth hurt?

Which tooth is sensitive to cold?

How long has it been since your teeth were last examined?

Do you have a heart murmur?

In general, the examiner should use open questions when beginning to inquire about a problem. Later, closed questions can be asked to obtain answers to specific questions. The skilled clinician knows when to use each type of question during the interview. Examples are presented in the following sections. The *In Clinical Practice* box features tips on how to be an effective interviewer.

In Clinical Practice

Principles for Effective Interviewing

Eye contact is important, so position the dental chair upright and sit facing the patient. Raise or lower the operator's stool so that your eyes are at the same level as the patient's.

Use open-ended questions when investigating positive responses to items from the health questionnaire.

Explain to the patient why you are asking a question if he or she is hesitant or refuses to answer.

Be an objective, unbiased interviewer. Avoid adding personal feelings. The primary goals during the interview are to accumulate and assess the facts, not to influence them.

Be an attentive, active listener. The "golden rule" of interviewing is to listen more than speak.

Use verbal facilitators like "yes" and "uh huh" to encourage patients to share information.

Be aware of the patient's nonverbal communication, such as crossing arms or legs or avoiding making eye contact.

At the conclusion of the interview, summarize positive findings with the patient to confirm accuracy.

The **history of present illness (HPI)** is the history of the chief complaint, which the patient usually supplies with a little prompting. When possible, the dentist should keep the questioning open, although specific (closed) questions help clarify details.

Example 1:

Chief complaint

"My tooth hurts." (*a symptom*)

HPI

The patient has had a dull ache in the lower right quadrant that has been increasing in intensity for the past 4 days. The pain is worse with hot stimuli and chewing and is not relieved by aspirin.

Example 2:

Chief complaint

"I lost a filling and need my teeth checked." (*a symptom and a request*)

HPI

The patient lost a restoration from an upper right molar 2 days ago. The tooth is asymptomatic. Her last dental examination and prophylaxis was 2 years ago.

Resolving the patient's chief complaint as soon as possible represents a "golden rule" of treatment planning. When a new patient presents in pain, the dentist may need to suspend the comprehensive examination process and instead focus on the specific problem, make a diagnosis, and quite possibly begin treatment.

At times, the chief complaint may be very general, such as, "I need to chew better," or "I don't like the appearance of my teeth." In such instances, the practitioner must carefully dissect what issues concern the patient. Often, what initially appears to be the problem may be a more complex issue that will be difficult to manage until later in the treatment plan. During the course of treatment, the dentist should advise the patient as to what progress is being made toward resolving the initial chief complaint.

General Health History

The dentist must obtain a health history from each patient and regularly update this information in the record. A comprehensive health history contains a review of all of the patient's past and present illnesses. Information about a patient's health history can prevent or help manage an emergency. Some systemic diseases may affect the oral cavity and the patient's response to dental treatment, including delaying healing or increasing the chance for infection. Conversely, some oral diseases can affect the patient's general health. Because many patients see their dentist more frequently than they see their physician, the dentist should use the patient's general health history and physical examination to screen for sig-

nificant systemic diseases, such as hypertension, diabetes, and cancer.

Most dental practices screen for potential health problems by asking all new patients to complete a health questionnaire (Figure 1-4, A and B). When reviewing the health questionnaire, the dentist must look for conditions that may affect treatment, patient management, or treatment outcomes. Interviewing the patient, first with open-ended questions about the problem and later with closed questions, usually clarifies positive responses to the questionnaire. Although it is beyond the scope of this book to present all the systemic conditions that can impact dental treatment, several are discussed in Chapter 5, including guidelines for consulting with the patient's physician when the dentist has detected significant findings.

Whether using a preprinted questionnaire or an interview technique, the general health history should include a **review of systems**. Commonly reviewed systems include the cardiovascular, respiratory, central nervous, gastrointestinal, genitourinary, musculoskeletal, endocrine, and integumentary (including eyes and ears). The information gained through the review of systems enables the dentist (1) to recognize significant health problems that may affect dental treatment and (2) to elicit information suggestive of new health problems that were previously unrecognized, undiagnosed, or untreated.

Including both prescription and nonprescription medications in the medication history also provides valuable insight into the patient's overall health. Any over-the-counter medications, herbal remedies, vitamins, or nutritional supplements used also should be included. The medication history can corroborate findings from the health history or may suggest new diseases or conditions that need further investigation. Some medications are, in themselves, cause for limiting, delaying, or modifying dental treatment. The dentist may consult one of several reference publications to help determine the indications and potential problems that may arise from the use of various drugs. Several references, available on electronic media or on the Internet, provide rapid access to information. Any potentially life threatening condition or medical problem that has a significant impact on the dental treatment should be displayed in a prominent place in the record.

Oral Health History

The oral health history incorporates such areas as the date of last dental examination, frequency of dental visits, types of treatment received, and the history of any problems that have emerged when receiving dental care.

Medical Alert:	Condition:	Premedication:	Allergies:	Anesthesia:	Date:
----------------	------------	----------------	------------	-------------	-------

HEALTH HISTORY FORM

Name: _____ Home Phone: () _____ Business Phone: () _____

Address: _____ City: _____ State: _____ Zip Code: _____

Occupation: _____ Height: _____ Weight: _____ Date of Birth: _____ Sex: M ☐ F ☐

Emergency Contact: _____ Relationship: _____ Phone: () _____

If you are completing this form for another person, what is your relationship to that person?

NAME	RELATIONSHIP

For the following questions, please (X) whichever applies, your answers are for our records only and will be kept confidential in accordance with applicable laws. Please note that during your initial visit you will be asked some questions about your responses to this questionnaire and there may be additional questions concerning your health. This information is vital to allow us to provide appropriate care for you. This office does not use this information to discriminate.

DENTAL INFORMATION

	Yes	No	Don't Know	
Do your gums bleed when you brush?	<input type="checkbox"/>	<input type="checkbox"/>	<input type="checkbox"/>	How would you describe your current dental problem?
Have you ever had orthodontic (braces) treatment?	<input type="checkbox"/>	<input type="checkbox"/>	<input type="checkbox"/>	_____
Are your teeth sensitive to cold, hot, sweets or pressure?	<input type="checkbox"/>	<input type="checkbox"/>	<input type="checkbox"/>	_____
Do you have earaches or neck pains?	<input type="checkbox"/>	<input type="checkbox"/>	<input type="checkbox"/>	Date of your last dental exam: _____
Have you had any periodontal (gum) treatments?	<input type="checkbox"/>	<input type="checkbox"/>	<input type="checkbox"/>	Date of last dental x-rays: _____
Do you wear removable dental appliances?	<input type="checkbox"/>	<input type="checkbox"/>	<input type="checkbox"/>	What was done at that time? _____
Have you had a serious/difficult problem associated with any previous dental treatment?	<input type="checkbox"/>	<input type="checkbox"/>	<input type="checkbox"/>	How do you feel about the appearance of your teeth? _____
If yes, explain: _____				_____

MEDICAL INFORMATION

	Yes	No	Don't Know	
<p>If you answer yes to any of the 3 items below, please stop and return this form to the receptionist.</p> <p>Have you had any of the following diseases or problems?</p> <p>Active Tuberculosis <input type="checkbox"/> <input type="checkbox"/> <input type="checkbox"/></p> <p>Persistent cough greater than a 3 week duration <input type="checkbox"/> <input type="checkbox"/> <input type="checkbox"/></p> <p>Cough that produces blood <input type="checkbox"/> <input type="checkbox"/> <input type="checkbox"/></p>				<p>Are you taking or have you recently taken any medicine(s) including non-prescription medicine? <input type="checkbox"/> <input type="checkbox"/> <input type="checkbox"/></p> <p>If yes, what medicine(s) are you taking? _____</p> <p>Prescribed: _____</p> <p>Over the counter: _____</p> <p>Vitamins, natural or herbal preparations and/or diet supplements: _____</p>
Are you in good health?	<input type="checkbox"/>	<input type="checkbox"/>	<input type="checkbox"/>	Are you taking, or have you taken, any diet drugs such as Pondimin (fenfluramine), Redux (dextfenfluramine) or phen-fen (fenfluramine-phentermine combination)? <input type="checkbox"/> <input type="checkbox"/> <input type="checkbox"/>
Has there been any change in your general health within the past year?	<input type="checkbox"/>	<input type="checkbox"/>	<input type="checkbox"/>	Do you drink alcoholic beverages? <input type="checkbox"/> <input type="checkbox"/> <input type="checkbox"/>
Are you now under the care of a physician?	<input type="checkbox"/>	<input type="checkbox"/>	<input type="checkbox"/>	If yes, how much alcohol did you drink in the last 24 hours? _____
If yes, what is/are the condition(s) being treated? _____				In the past week? _____
Date of last physical examination: _____				Are you alcohol and/or drug dependent? <input type="checkbox"/> <input type="checkbox"/> <input type="checkbox"/>
Physician: _____				If yes, have you received treatment? (circle one) Yes / No
NAME _____ PHONE _____				Do you use drugs or other substances for recreational purposes? <input type="checkbox"/> <input type="checkbox"/> <input type="checkbox"/>
ADDRESS _____ CITY/STATE _____ ZIP _____				If yes, please list: _____
NAME _____ PHONE _____				Frequency of use (daily, weekly, etc.): _____
ADDRESS _____ CITY/STATE _____ ZIP _____				Number of years of recreational drug use: _____
Have you had any serious illness, operation, or been hospitalized in the past 5 years? <input type="checkbox"/> <input type="checkbox"/> <input type="checkbox"/>				Do you use tobacco (smoking, snuff, chew)? <input type="checkbox"/> <input type="checkbox"/> <input type="checkbox"/>
If yes, what was the illness or problem? _____				If yes, how interested are you in stopping? (circle one) Very / Somewhat / Not interested
_____				Do you wear contact lenses? <input type="checkbox"/> <input type="checkbox"/> <input type="checkbox"/>

PLEASE COMPLETE BOTH SIDES

A

Figure 1-4 A, Health history form, front side.

	Yes	No	Don't Know		Yes	No	Don't Know
Are you allergic to or have you had a reaction to?				Have you had an orthopedic total joint (hip, knee, elbow, finger) replacement?			
Local anesthetics	<input type="checkbox"/>	<input type="checkbox"/>	<input type="checkbox"/>	If yes, when was this operation done?			
Aspirin	<input type="checkbox"/>	<input type="checkbox"/>	<input type="checkbox"/>	If you answered yes to the above question, have you had any complications or difficulties with your prosthetic joint?			
Penicillin or other antibiotics	<input type="checkbox"/>	<input type="checkbox"/>	<input type="checkbox"/>				
Barbiturates, sedatives, or sleeping pills	<input type="checkbox"/>	<input type="checkbox"/>	<input type="checkbox"/>				
Sulfa drugs	<input type="checkbox"/>	<input type="checkbox"/>	<input type="checkbox"/>				
Codeine or other narcotics	<input type="checkbox"/>	<input type="checkbox"/>	<input type="checkbox"/>				
Latex	<input type="checkbox"/>	<input type="checkbox"/>	<input type="checkbox"/>				
Iodine	<input type="checkbox"/>	<input type="checkbox"/>	<input type="checkbox"/>	Has a physician or previous dentist recommended that you take antibiotics prior to your dental treatment?	<input type="checkbox"/>	<input type="checkbox"/>	<input type="checkbox"/>
Hay fever/seasonal	<input type="checkbox"/>	<input type="checkbox"/>	<input type="checkbox"/>	If yes, what antibiotic and dose?			
Animals	<input type="checkbox"/>	<input type="checkbox"/>	<input type="checkbox"/>	Name of physician or dentist*:			
Food (specify) _____	<input type="checkbox"/>	<input type="checkbox"/>	<input type="checkbox"/>	Phone:			
Other (specify) _____	<input type="checkbox"/>	<input type="checkbox"/>	<input type="checkbox"/>				
Metals (specify) _____	<input type="checkbox"/>	<input type="checkbox"/>	<input type="checkbox"/>				
To yes responses, specify type of reaction.				WOMEN ONLY			
				Are you or could you be pregnant?	<input type="checkbox"/>	<input type="checkbox"/>	<input type="checkbox"/>
				Nursing?	<input type="checkbox"/>	<input type="checkbox"/>	<input type="checkbox"/>
				Taking birth control pills or hormonal replacement?	<input type="checkbox"/>	<input type="checkbox"/>	<input type="checkbox"/>

Please (X) a response to indicate if you have or have not had any of the following diseases or problems.

	Yes	No	Don't Know		Yes	No	Don't Know
Abnormal bleeding	<input type="checkbox"/>	<input type="checkbox"/>	<input type="checkbox"/>	Hemophilia	<input type="checkbox"/>	<input type="checkbox"/>	<input type="checkbox"/>
AIDS or HIV infection	<input type="checkbox"/>	<input type="checkbox"/>	<input type="checkbox"/>	Hepatitis, jaundice or liver disease	<input type="checkbox"/>	<input type="checkbox"/>	<input type="checkbox"/>
Anemia	<input type="checkbox"/>	<input type="checkbox"/>	<input type="checkbox"/>	Recurrent Infections	<input type="checkbox"/>	<input type="checkbox"/>	<input type="checkbox"/>
Arthritis	<input type="checkbox"/>	<input type="checkbox"/>	<input type="checkbox"/>	If yes, indicate type of infection: _____			
Rheumatoid arthritis	<input type="checkbox"/>	<input type="checkbox"/>	<input type="checkbox"/>	Kidney problems	<input type="checkbox"/>	<input type="checkbox"/>	<input type="checkbox"/>
Asthma	<input type="checkbox"/>	<input type="checkbox"/>	<input type="checkbox"/>	Mental health disorders. If yes, specify: _____	<input type="checkbox"/>	<input type="checkbox"/>	<input type="checkbox"/>
Blood transfusion. If yes, date: _____	<input type="checkbox"/>	<input type="checkbox"/>	<input type="checkbox"/>	Malnutrition	<input type="checkbox"/>	<input type="checkbox"/>	<input type="checkbox"/>
Cancer/Chemotherapy/Radiation Treatment	<input type="checkbox"/>	<input type="checkbox"/>	<input type="checkbox"/>	Night sweats	<input type="checkbox"/>	<input type="checkbox"/>	<input type="checkbox"/>
Cardiovascular disease. If yes, specify below:	<input type="checkbox"/>	<input type="checkbox"/>	<input type="checkbox"/>	Neurological disorders. If yes, specify: _____	<input type="checkbox"/>	<input type="checkbox"/>	<input type="checkbox"/>
___ Angina				Osteoporosis	<input type="checkbox"/>	<input type="checkbox"/>	<input type="checkbox"/>
___ Arteriosclerosis				Persistent swollen glands in neck			
___ Artificial heart valves				Respiratory problems. If yes, specify below:	<input type="checkbox"/>	<input type="checkbox"/>	<input type="checkbox"/>
___ Congenital heart defects				___ Emphysema			
___ Congestive heart failure				___ Bronchitis, etc.			
___ Coronary artery disease				Severe headaches/migraines	<input type="checkbox"/>	<input type="checkbox"/>	<input type="checkbox"/>
___ Damaged heart valves				Severe or rapid weight loss	<input type="checkbox"/>	<input type="checkbox"/>	<input type="checkbox"/>
___ Heart attack				Sexually transmitted disease	<input type="checkbox"/>	<input type="checkbox"/>	<input type="checkbox"/>
___ Heart murmur				Sinus trouble	<input type="checkbox"/>	<input type="checkbox"/>	<input type="checkbox"/>
___ High blood pressure				Sleep disorder	<input type="checkbox"/>	<input type="checkbox"/>	<input type="checkbox"/>
___ Low blood pressure				Sores or ulcers in the mouth	<input type="checkbox"/>	<input type="checkbox"/>	<input type="checkbox"/>
___ Mitral valve prolapse				Stroke	<input type="checkbox"/>	<input type="checkbox"/>	<input type="checkbox"/>
___ Pacemaker				Systemic lupus erythematosus	<input type="checkbox"/>	<input type="checkbox"/>	<input type="checkbox"/>
___ Rheumatic heart disease/Rheumatic fever				Tuberculosis	<input type="checkbox"/>	<input type="checkbox"/>	<input type="checkbox"/>
Chest pain upon exertion	<input type="checkbox"/>	<input type="checkbox"/>	<input type="checkbox"/>	Thyroid problems	<input type="checkbox"/>	<input type="checkbox"/>	<input type="checkbox"/>
Chronic pain	<input type="checkbox"/>	<input type="checkbox"/>	<input type="checkbox"/>	Ulcers	<input type="checkbox"/>	<input type="checkbox"/>	<input type="checkbox"/>
Disease, drug, or radiation-induced immunosuppression	<input type="checkbox"/>	<input type="checkbox"/>	<input type="checkbox"/>	Excessive urination	<input type="checkbox"/>	<input type="checkbox"/>	<input type="checkbox"/>
Diabetes. If yes, specify below:	<input type="checkbox"/>	<input type="checkbox"/>	<input type="checkbox"/>	Do you have any disease, condition, or problem not listed above that you think I should know about?	<input type="checkbox"/>	<input type="checkbox"/>	<input type="checkbox"/>
___ Type I (Insulin dependent)				Please explain:			
___ Type II							
Dry Mouth	<input type="checkbox"/>	<input type="checkbox"/>	<input type="checkbox"/>				
Eating disorder. If yes, specify: _____	<input type="checkbox"/>	<input type="checkbox"/>	<input type="checkbox"/>				
Epilepsy	<input type="checkbox"/>	<input type="checkbox"/>	<input type="checkbox"/>				
Fainting spells or seizures	<input type="checkbox"/>	<input type="checkbox"/>	<input type="checkbox"/>				
Gastrointestinal disease	<input type="checkbox"/>	<input type="checkbox"/>	<input type="checkbox"/>				
G.E. Reflux/persistent heartburn	<input type="checkbox"/>	<input type="checkbox"/>	<input type="checkbox"/>				
Glaucoma	<input type="checkbox"/>	<input type="checkbox"/>	<input type="checkbox"/>				

NOTE: Both Doctor and patient are encouraged to discuss any and all relevant patient health issues prior to treatment.

I certify that I have read and understand the above. I acknowledge that my questions, if any, about inquiries set forth above have been answered to my satisfaction. I will not hold my dentist, or any other member of his/her staff, responsible for any action they take or do not take because of errors or omissions that I may have made in the completion of this form.

SIGNATURE OF PATIENT/LEGAL GUARDIAN

DATE

FOR COMPLETION BY DENTIST

Comments on patient interview concerning health history:

Significant findings from questionnaire or oral interview:

Dental management considerations:

Health History Update: On a regular basis the patient should be questioned about any medical history changes, date and comments notated, along with signature.

Date

Comments

Signature of patient and dentist

Common problems include syncope (fainting), general anxiety, and reactions to drugs used in dentistry. Patients should also be questioned about their oral hygiene practices. Experienced dentists spend whatever time is necessary to investigate the oral health history of the patient because of the strong influence it can have on future treatment.

While obtaining the oral health history, the dentist should first determine the general nature of the patient's past care. Has the patient seen a dentist regularly or been treated only on an episodic basis? What kind of oral health care did the patient receive as a child? The frequency of oral health care can be an important predictor of how effectively the patient will comply with new treatment recommendations. If the patient has visited the dentist regularly, what types of treatment were provided? Was the patient satisfied with the treatment received? Did the dentist do anything in particular to make treatment more comfortable? It also is important to establish whether the patient has had any specialty treatment, such as orthodontic, endodontic, or periodontal care, in the event additional treatment is required in the future.

Investigation into the patient's dental history supplements the clinical examination during which new findings may be identified. The dentist should establish the reason for any missing teeth, including when they were removed. Knowing the age of suspect restorations may yield important perspectives on the quality of previous work, the patient's oral hygiene, how well previous treatment has held up, and the prognosis for new work. The age of tooth replacements may also have a bearing on whether the patient's dental insurance will cover any necessary replacement.

Psychosocial History

The patient's social, emotional, and behavioral history represents one of the most important and difficult areas to investigate. The patient's occupation, habits, financial resources, and general lifestyle can significantly influence attitudes about dentistry. It is important to investigate the patient's attitudes about the profession, including priorities, expectations, and motivations for seeking treatment. The psychosocial history is also a prime source of information about the patient's financial status, time availability for treatment, mode of transportation to dental visits—any or all of which may have a bearing on how dental treatment is planned or executed. Much of the psychosocial history will overlap with the oral health history, especially concerns regarding fear of dental treatment (covered in depth in Chapter 13) and concerns about the cost of treatment (discussed in Chapter 17).

The health questionnaire can be used to screen for information about habits such as smoking, alcohol, and drug use. Often, however, these questions are best pursued verbally during the patient interview. A patient's behavior or medication profile may suggest the presence of some type of mental disease, a topic discussed further in Chapter 14.

CLINICAL EXAMINATION

Developing an accurate and comprehensive treatment plan depends on a thorough analysis of all the general and oral health conditions that exist when the patient presents for evaluation. A comprehensive clinical examination involves assembling significant findings from the following five areas:

- The physical examination
- The intraoral and extraoral soft tissue examination
- The periodontal examination
- The examination of the teeth
- The radiographic examination

Physical Examination

Unlike the physician who examines many areas of the body for signs of disease, the dentist in general practice usually performs only a limited overall physical examination that includes evaluation of:

- Patient posture and gait
- Exposed skin surfaces
- Vital signs
- Cognition and mental acuity
- Speech and ability to communicate

With careful observation and findings from the health history, the dentist can detect many signs of systemic diseases that could have treatment implications and may suggest referral to a physician. For example, a patient who has difficulty walking may be afflicted with osteoarthritis or have a neurologic problem, such as Parkinson's disease or a stroke. The appearance of the skin, hair, and eyes may suggest such diseases as anemia, hypothyroidism, or hepatitis.

Measuring vital signs provides an easy and objective measure for physical evaluation. Heart rate, rhythm, and blood pressure should be measured for every new patient and reevaluated at each periodic examination. The vital signs should also be taken before administering any local anesthetic or sedation and at the beginning of *all* visits for patients under treatment for high blood pressure, thyroid disease, or cardiac disease. Automated blood pressure devices have greatly simplified the process of obtaining these measurements. The normal pulse rate for adults

is 60 to 90 beats per minute at rest, with a regular and strong rhythm. Blood pressure measurements can vary considerably between individuals, but ideally should be lower than 120/80 mm Hg. Information about how to evaluate a patient's blood pressure can be found in Chapter 5.

Although not regularly recorded, measuring vital signs—such as respiration rate and temperature—may be indicated for patients with respiratory problems or signs of infection. Some practitioners record height and weight measurements for children, with the latter being especially useful for calculating medication dosages.

Intraoral and Extraoral Examination

Evaluation of head and neck structures for evidence of tissue abnormalities or lesions constitutes an important part of a comprehensive examination. This is typically accomplished by looking for variations from normal and by palpating the tissues to detect abnormalities. The following extraoral structures of the head and neck should be evaluated in a systematic fashion: facial form and symmetry, the skin, temporomandibular joint, eyes, ears, nose, major salivary glands, regional lymph nodes, and thyroid gland. The location and characteristics of any lesions should be noted in the patient record (Box 1-1).

Following the extraoral examination, the dentist then evaluates the intraoral structures, which include the lips, buccal mucosa and vestibule, tongue, floor of the mouth, salivary glands, hard and soft palate, and oropharynx.

The significance of positive findings from the head and neck examination may be difficult to determine without further evaluation or biopsy. Common findings, such as small ulcerations, can be observed for 5 to 10 days to see if they resolve. The patient usually can provide important historical information, such as how long the lesion has existed and whether it is associated with symptoms of pain or other discomfort. With this information, a

history of repeated sun exposure or tobacco or alcohol use may elevate the significance of skin and oral lesions and make the clinician suspicious of cancer (Figure 1-5).

Periodontal Examination

Evaluating the periodontium is an important part of a comprehensive examination. Problems with the supporting structures of the teeth can affect the entire treatment planning process. The dentist records findings from the examination in the record on a periodontal chart.

The examination begins with an overall assessment of the patient's oral hygiene and the appearance of periodontal soft tissue. Significant findings include areas of plaque and food accumulation on the teeth. Using disclosing solution can further reveal the presence and distribution of plaque and calculus, but this is best accomplished at the conclusion of the examination so that tissue color can be examined in its natural state. The clinician should look for deviations from healthy soft tissue, such as redness and rolled gingival margins.

The dentist next checks each tooth for excessive mobility, which may be related to loss of periodontal attachment or trauma from occlusion. Radiographs and periodontal probing depths provide information about the level of periodontal hard and soft tissue support. The dentist may use the periodontal screening and recording (PSR) system for determining the extent of periodontal probing (see *In Clinical Practice* box on p. 14). A full mouth periodontal charting (Figure 1-6) includes identification of probing depths; the gingival margin; presence of bleeding on probing and areas of gingival recession; mucogingival problems, such as deficiencies of keratinized tissue; abnormal frenulum insertions; and presence, location, and extent of furcation involvement.

BOX 1-1 Characteristics of Surface Lesions

Location
Size
Color
Shape
Borders
Surface contour
Surface texture
Consistency
Drainage/bleeding
Blanching with pressure
Fixed/moveable

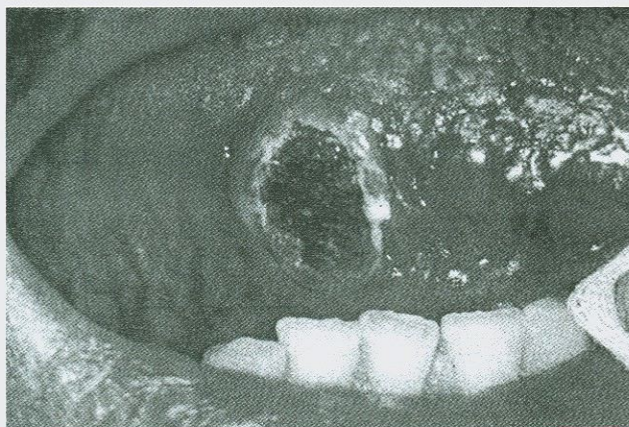


Figure 1-5 This firm, ulcerated lesion on the right lateral border of the tongue was found in a patient who had used tobacco for more than 30 years. After biopsy and histologic evaluation, the lesion was diagnosed as a squamous cell carcinoma.

The University of Michigan School of Dentistry PERIODONTAL EXAM FORM

☒ Initial ☐ Re-evaluation ☐ Maintenance

Patient's last name				First				Middle Initial			
Chart number				Date of birth							

Date 5/1/06

Instructor: _____

Student: _____

Periodontally:

☐ Stable
☒ Unstable

Bleeding/
exudate •

Furcation: I, II, III

Mobility: 1, 2, 3

Fremitus: F

Impacted
(circle tooth)

Missing X

Drift ↑→

Mucogingival
problems/
defects X

Prognosis
mark problem teeth:
? questionable
P poor
H hopeless

	1	2	3	4	5	6	7	8	9	10	11	12	13	14	15	16
PD	4 3 6 7 4 6 6 4 5 4 5 8 4 2 5 5 6 7 6 6 6								5 4 6 5 3 4 4 2 4 2 2 2 2 2 2 2 2 2 2 2 2							
Recession																
Other																
BOP																
Exudate																
Prognosis	Q Q Q P Q								P Q							
BUCCAL																
LINGUAL																
PD	5 4 7 6 5 6 5 3 5 4 5 8 4 2 4 5 5 5 6 4 6								5 4 5 5 4 4 3 4 2 2 2 2 2 2 2 2 2 2 2 2 2							
Recession	2								2							
Other																
BOP																
Exudate																
Prognosis																
BUCCAL																
LINGUAL																
PD	5 5 6 6 8 6 5 2 4 4 2 4 3 3 3 2 1 2 2 1 2								3 2 2 3 1 3 3 2 3 4 4 5 5 5 6 5 7 6 6 6 6							
Recession	2								2							
Other																
BOP																
Exudate																
Prognosis	Q H Q Q								Q Q Q Q Q							

Figure 1-6 Periodontal charting form. (Courtesy the University of Michigan School of Dentistry, Ann Arbor, Michigan.)

In Clinical Practice

PSR—An Early Detection System for Periodontal Disease

In 1992, the American Dental Association and the American Academy of Periodontology introduced a screening system for the detection of periodontal disease in adults, referred to as periodontal screening and recording, or PSR. To perform a PSR examination, a special periodontal probe is "walked" through the gingival crevice of the teeth and measurements are observed at six sites around each tooth. A numerical score between 0 and 4 is recorded for each sextant of the mouth, based on the deepest recorded probing in the sextant. An asterisk added to the score denotes presence of furcation invasion, mobility, mucogingival problems, or recession greater than 3.5 mm. The data from the PSR examination are recorded using a simple chart:

PERIODONTAL SCREENING AND RECORDING					
R	1	2*	2	L	
	2	1	1		
			1	0	1
			Month	Day	Year

The PSR program is intended for the dentist in general practice. Relatively easy to administer, the PSR technique can be performed in only a few minutes. It serves as a screening tool for patients and can assist the clinician in deciding whether more comprehensive periodontal data collection is indicated. In addition, the PSR scores provide a general measure of periodontal disease throughout the mouth. Armed with this information, a dentist in general practice can decide whether to treat the patient or refer to a periodontist for care.

Examination of the Teeth

Patients usually perceive the examination of the teeth as the most important reason to be evaluated by the dentist. The procedure is important from the dentist's point of view also because dental problems are common patient complaints. For an effective examination, it is important that the teeth be relatively clean and free from stain, plaque, and calculus, or significant findings may be missed. For patients with extensive plaque and calculus, it may be best to perform a cursory examination of the dentition, begin periodontal treatment to clean the teeth, and have the patient return to finish the examination at a later appointment.

The following instruments should be readily available for use when examining the teeth (Figure 1-7):

- Dental mirror
- Dental explorer
- Periodontal probe
- Miller forceps and articulating paper
- Cotton forceps
- Cotton rolls and gauze
- Air/water syringe
- Dental floss

In addition, an electric pulp tester and refrigerant spray (for cold testing) will help to evaluate the pulp vitality of individual teeth. Although optional, the dentist's use of magnifying loupes or glasses is highly desirable to help identify early signs of dental disease.

Before beginning the examination, the dentist should review any significant findings from the dental history, especially chief complaints involving the teeth. The patient should be asked again about any dental problems, including teeth that might be sensitive to being dried

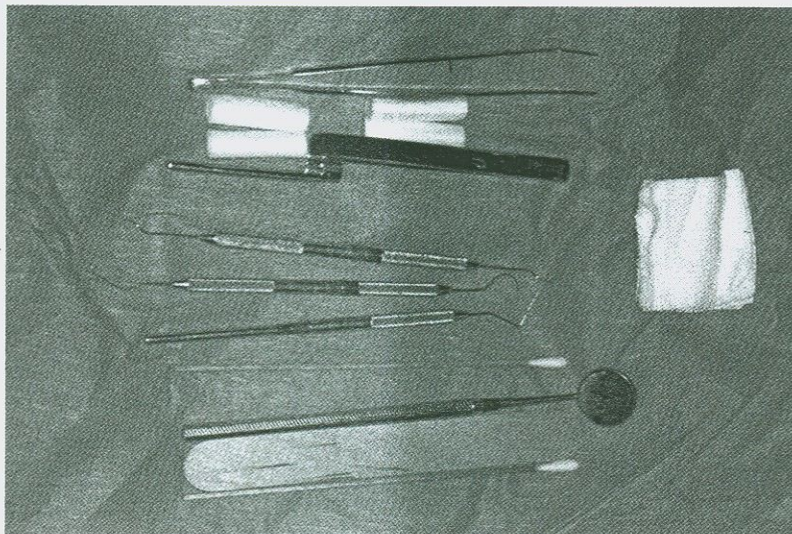

Figure 1-7 Instruments and materials that should be available when examining the teeth include cotton forceps, cotton rolls for isolation, Miller forceps, dental explorers, periodontal probe, cotton swabs, a mouth mirror, a wooden tongue blade, and gauze squares.

with air. The dentist should review any available radiographs during the examination so that radiographic findings can be correlated with those found clinically. It is advantageous to have an assistant available to record findings during the examination and to maintain asepsis of the dental record.

The examiner begins by noting any missing teeth and evaluating any replacements for them such as implants, fixed and removable partial dentures, and complete dentures. The patient should be questioned as to the history of any missing teeth. If the patient has removable prostheses, they can be evaluated in the mouth at this time and then removed. Use dental floss to check the integrity of each interproximal contact. Finally, assess teeth for general condition, noting overall numbers and types of restorations, irregularities of tooth color, morphology, and ability to function.

Each tooth is then evaluated sequentially, usually from the maxillary right to the mandibular left. Air-dry a sextant of teeth and, if necessary, use cotton rolls to maintain dryness and isolation (Figure 1-8). Record the shape and type of all existing restorations. Use the explorer to evaluate margins of the restoration for signs of recurrent decay or marginal breakdown. Visually examine any

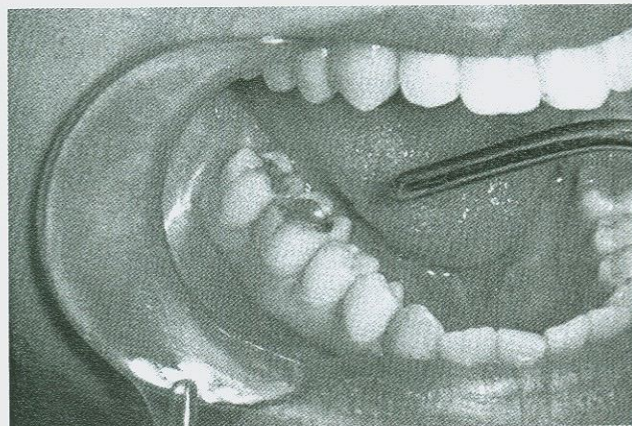


Figure 1-8 It is important to dry the teeth before examination to prevent missing any significant findings.

unrestored pits and fissures for color changes suggestive of demineralization or caries. Proximal surfaces can be examined and findings corroborated with the bite-wing radiographs. The use of a sharp dental explorer to evaluate stained and discolored tooth surfaces is controversial (see the *What's the Evidence?* box). **Transillumination**, or shining light between the teeth, may help identify dark areas of proximal caries, especially in the anterior region. Vital teeth with large restorations or those that

What's the Evidence?

Evidence Relating to the Use of an Explorer as an Adjunct to Visual Caries Diagnosis

Using a sharp explorer to probe for caries is a traditional method that is still commonly used in the United States. Research has shown, however, that probing with an explorer can cause enamel destruction that leads to future caries development.¹⁻³ Additionally, the use of an explorer may transfer microorganisms from one fissure to another, increasing lesion susceptibility.⁴ Using an explorer for caries detection has not been shown to improve the accuracy of caries diagnosis⁵ and a catch of the explorer may relate to noncarious anatomic features of pits and fissures.⁶ In a review of caries diagnosis methods, Newburn states that using a probe is not a better method than visual examination alone because both methods have similar sensitivity (accurate detection of true disease) and specificity (accurate determination of absence of disease).⁷ Others have also verified the low sensitivity of an explorer.⁸⁻⁹ Ekstrand and others created visual criteria for occlusal caries detection, which were then correlated with histologic lesion depth. They concluded that if a dentist uses only the visual system, without a probe or explorer, it is still possible to have a good sense of the histologic depth of the lesion.¹⁰ In Europe, a visual examination of the teeth without an explorer has been used for many years and is the standard in clinical practice and in clinical caries trials.¹¹

Additionally, the consensus report for the 2001 NIH

(National Institute of Health) Conference on Diagnosis and Management of Dental Caries Throughout Life concluded that, "... the use of sharp explorers in the detection of primary occlusal caries appears to add little diagnostic information to other modalities and may be detrimental."¹²

During a visual examination for caries, it is important that the teeth are not only clean, but dry. In a review discussing the content validity of caries detection criteria literature, A. Ismail states: "While no data are available to compare the accuracy and reliability of examiners of clean vs. unclear or dry vs. wet teeth, the detection of early signs of caries cannot be achieved unless teeth are clean and dry."¹³ In their paper describing use of a ranked visual scoring system for caries diagnosis, Ekstrand and others state that to clearly see a carious lesion, "it is absolutely essential that all plaque is cleaned from the tooth surface."¹⁴ They note that demineralized enamel is more porous than sound enamel. The pores of demineralized enamel fill with a watery medium such as saliva, which causes the lesion to appear white since the refractive indices of enamel and water are different. When the tooth is dried, the watery medium is replaced with air and the lesion is even more apparent.¹⁴ McComb and Tam suggest that to obtain the greatest amount of information during a visual examination, in addition to the teeth being clean and dry, the teeth should be well illuminated.⁶ Once the tooth is cleaned and dried, all surfaces can be evaluated for

What's the Evidence?

Evidence Relating to the Use of an Explorer as an Adjunct to Visual Caries Diagnosis—cont'd

opacities, translucencies, and localized breakdown of enamel.

To prevent damage to a lesion that can most likely be re-mineralized, a blunt probe is preferred over a sharp explorer.¹⁵

The blunt probe should only be used lightly, if necessary.

1. Ekstrand K, Qvist V, Thylstrup A: Light microscope study of the effect of probing in occlusal surfaces, *Caries Research* 21(4):368-374, 1987.
2. van Dorp CS, Exterkate RA, ten Cate JM: The effect of dental probing on subsequent enamel demineralization, *J Dent Child* 55(5):343-347, 1988.
3. Weerheijm KL, van Amerongen WE, Eggink CO: The clinical diagnosis of occlusal caries: a problem, *Journal of Dentistry for Children* 56(3):196-200, 1989 May-Jun.
4. Loesche WJ, Svanberg ML, Pape HR: Intraoral transmission of *Streptococcus mutans* by a dental explorer, *J Dent Res* 58(8):1765-1770, 1979.
5. Lussi A: Comparison of different methods for the diagnosis of fissure caries without cavitation, *Caries Research* 27(5):409-416, 1993.
6. McComb D, Tam LE: Diagnosis of occlusal caries: Part I. Conventional methods, *J Can Dent Assoc* 67(8):454-457, 2001.
7. Newbrun E: Problems in caries diagnosis, *Int Dent J* 43(2):133-142, 1993.
8. Hintze H: Screening with conventional and digital bite-wing radiography compared to clinical examination alone for caries detection in low-risk children, *Caries Research* 27(6):499-504, 1993.
9. Penning C, van Amerongen JP, Seef RE et al: Validity of probing for fissure caries diagnosis, *Caries Research* 26(6):445-449, 1992.
10. Ekstrand KR, Ricketts DN, Kidd EA: Reproducibility and accuracy of three methods for assessment of demineralization depth of the occlusal surface: an in vitro examination, *Caries Research* 31(3):224-231, 1997.
11. Pitts NB, Stamm JW: International consensus workshop on caries clinical trials (ICW-CCT)—final consensus statements: agreeing where the evidence leads, *J Dent Res* 83 Spec No C:C125-128, 2004.
12. Found at: <http://consensus.nih.gov/2001/2001DentalCaries115html.htm>
13. Ismail AI: Visual and visuo-tactile detection of dental caries, *J Dent Res* 83 Spec No C:C56-66, 2004.
14. Ekstrand KR, Ricketts DN, Kidd EA: Occlusal caries: pathology, diagnosis and logical management, *Dent Update* 28(8):380-387, 2001.
15. Angmar-Mansson B, ten Bosch JJ: Advances in methods for diagnosing coronal caries—a review, *Adv Dent Res* 7(2):70-79, 1993.

are symptomatic should be percussed with the end of the mirror handle and/or evaluated with hot and cold or an electric pulp tester.

Occlusion

After the individual teeth have been examined, the dentist should evaluate them all together by studying the patient's occlusion. Looking at each arch separately, the clinician first checks for shifts of the dentition from the midline. Are the marginal ridges even, or are teeth extruded or intruded from the occlusal plane? Have teeth moved mesially or distally into any edentulous spaces? Is there evidence of excessive wear to the teeth? Instruct the patient to occlude in the maximum intercuspal position, so that the dentist can evaluate the amount of overbite and overjet in the incisor area. Note the Angle classification by examining the relationships between the maxillary and mandibular canines and molar teeth. At this time, also note in the record any open bite or cross-bite. Instruct the patient to move the mandible from side to side and forward to study which teeth guide the occlusion in lateral and protrusive excursions. The dentist can then manipulate the lower jaw to evaluate the

centric relation and look for interferences in lateral and protrusive movements. The patient should be questioned at this time about pain or tenderness in the temporomandibular joint and associated muscles. The patient should be evaluated for visual; palpatory; or auditory evidence, such as "pops," "clicks," or crepitation. Any deviation on opening should be noted. Finally the patient should be asked to demonstrate how wide the mouth can be opened. A more detailed investigation is warranted when the patient has pain, an inability to chew, or a limited opening (<25 mm).

RADIOGRAPHIC EXAMINATION

Conventional and digital radiographs provide informative images of the teeth and jaws, and serve to document the patient's dental condition at the beginning of treatment. Before any radiographic examination, the dentist should review the patient's oral health history and clinically examine the patient. When possible, any radiographs made by previous dentists should be obtained, particularly those less than 3 years old.

Radiographs should be made only when the diagnostic benefits outweigh the risks of exposure to ionizing radiation. The dentist decides which type of radiograph to obtain based on patient age, clinical findings, and oral health history. Certain factors place a patient at higher risk for oral problems, necessitating a more extensive radiographic survey (Box 1-2). The American Dental Association and the U.S. Food and Drug Administration (FDA) have issued a series of recommendations to assist practitioners with this decision (Table 1-1).

Dentists in general practice commonly use several types of radiographs. The primary intraoral exposures are periapical, interproximal (or bite-wing), and occlusal projections. The dentist can choose from among several types of extraoral radiographs, with the panoramic being most

frequently used for examining areas not readily visualized with intraoral films. Dentists typically use radiographs to examine for signs of pathologic conditions, caries, periodontal and periapical problems, remnants of missing teeth, and the quality of existing dental restorations.

Periapical radiographs should show all of a particular tooth and the surrounding bone. Useful for imaging the teeth, detecting caries, and documenting signs of periodontal and periapical disease, they are limited by their size and the need to be placed in the mouth. A complete mouth survey of a completely dentate patient usually consists of 16 to 20 periapical radiographs along with four interproximal radiographs (Figure 1-9).

Horizontal and vertical **interproximal** or **bite-wing radiographs** show the coronal portion of the teeth in both arches and the alveolar crestal bone. Most frequently used for the detection of interproximal caries and for evaluating the crestal bone height, bite-wing radiographs are also valuable as a screening tool for patient evaluation before deciding to make posterior periapical radiographs.

Occlusal radiographs are placed over the teeth in the occlusal plane. In adults, their use is limited to visualizing palatal lesions and searching for impacted or supernumerary teeth. The film can also be helpful in documenting expansion of bone in the mandible and salivary stones in the ducts of the submandibular gland (Figure 1-10).

The **panoramic radiograph** (also referred to as a **pan-tomograph**) displays a wide area of the jaws, and hence, enables evaluation of structures not covered by intraoral projections (Figure 1-11). Relatively easy to expose, the radiographs may help detect developmental anomalies, pathologic lesions of the teeth and jaws, or other bone fractures. In adults, dentists most commonly use this radiograph to evaluate third molar position or the condition of edentulous areas of the jaws before fabricating removable prosthodontics or placing implants. Because of the lower resolution and superimposition of structures on the film, a panoramic radiograph does not have the fine detail necessary to diagnose caries or document periodontal bone loss. This is more effectively accomplished with intraoral radiographs.

There are several situations in which imaging information in the third dimension is beneficial in diagnosis and treatment planning. Some examples include the placement of dental implants, evaluation of the relationship of third molar root tips to the mandibular canal before surgery, assessment of bony expansion for pathologic jaw lesions, and the analysis of jaw relationships in orthodontics. In the past, this information could be gained only from medical **computed tomographic (CT)** examination, but today, **cone-beam CT** scanners

BOX 1-2 Clinical Situations for Which Radiographs May Be Indicated

Positive Historical Findings

- Previous periodontal or endodontic treatment
- History of pain or trauma
- Familial history of dental anomalies
- Postoperative evaluation of healing
- Remineralization monitoring
- Presence of implants or evaluation for implant placement

Positive Clinical Signs/Symptoms

- Clinical evidence of periodontal disease
- Large or deep restorations
- Deep carious lesions
- Malposed or clinically impacted teeth
- Swelling
- Evidence of dentofacial trauma
- Mobility of teeth
- Sinus tract (fistula)
- Clinically suspected pathologic sinus condition
- Growth abnormalities
- Oral involvement in known or suspected systemic disease
- Positive neurologic findings in the head and neck
- Evidence of foreign objects
- Pain and/or dysfunction of temporomandibular joint
- Facial asymmetry
- Abutment teeth for fixed or removable partial prosthesis
- Unexplained bleeding
- Unexplained sensitivity of teeth
- Unusual eruption, spacing, or migration of teeth
- Unusual tooth morphology, calcification, or color
- Unexplained absence of teeth
- Clinical erosion

Table 1-1 Guidelines for Prescribing Dental Radiographs

Type of Encounter	Patient Age and Dental Developmental Stage			
	Child With Primary Dentition (before eruption of first permanent tooth)	Child With Transitional Dentition (after eruption of first permanent tooth)	Adolescent With Permanent Dentition (before eruption of third molars)	Adult, Edentulous or Partially Edentulous
New patient being evaluated for dental diseases and dental development	Individualized radiographic exam consisting of selected periapical/occlusal views and/or posterior bite-wings if proximal surfaces cannot be visualized or probed; patients without evidence of disease and with open proximal contacts may not require a radiographic exam at this time	Individualized radiographic exam consisting of posterior bite-wings with panoramic exam or posterior bite-wings and selected periapical images	Individualized radiographic exam consisting of posterior bite-wings with panoramic exam or posterior bite-wings and selected periapical images; a full mouth intraoral radiographic exam is preferred when the patient has clinical evidence of generalized dental disease or a history of extensive dental treatment	Individualized radiographic exam, based on clinical signs and symptoms.
Recall patient with clinical caries or at increased risk for caries*	Posterior bite-wing exam at 6-12 month intervals if proximal surfaces cannot be examined visually or with a probe	Posterior bite-wing exam at 12-24 month intervals if proximal surfaces cannot be examined visually or with a probe	Posterior bite-wing exam at 18-36 month intervals	Posterior bite-wing exam at 6-18 month intervals
Recall patient with no clinical caries and not at increased risk for caries*	Clinical judgment as to the need for and type of radiographic images for the evaluation of periodontal disease; imaging may consist of, but is not limited to, selected bite-wing and/or periapical images of areas where periodontal disease (other than nonspecific gingivitis) can be identified clinically	Clinical judgment as to the need for and type of radiographic images for evaluation and/or monitoring of dentofacial growth and development	Clinical judgment as to need for and type of radiographic images for evaluation and/or monitoring of dentofacial growth and development	Usually not indicated
Recall patient with periodontal disease	Clinical judgment as to the need for and type of radiographic images for the evaluation of periodontal disease; imaging may consist of, but is not limited to, selected bite-wing and/or periapical images of areas where periodontal disease (other than nonspecific gingivitis) can be identified clinically	Clinical judgment as to the need for and type of radiographic images for evaluation and/or monitoring of dentofacial growth and development	Clinical judgment as to need for and type of radiographic images for evaluation and/or monitoring of dentofacial growth and development	Usually not indicated
Patient for monitoring of growth and development	Clinical judgment as to the need for and type of radiographic images for the evaluation of periodontal disease; imaging may consist of, but is not limited to, selected bite-wing and/or periapical images of areas where periodontal disease (other than nonspecific gingivitis) can be identified clinically	Clinical judgment as to the need for and type of radiographic images for evaluation and/or monitoring of dentofacial growth and development	Clinical judgment as to need for and type of radiographic images for evaluation and/or monitoring of dentofacial growth and development	Usually not indicated

Patient with other Clinical judgment as to need for and type of radiographic images for evaluation and/or monitoring in these circumstances

circumstances including, but not limited to, proposed or existing implants, pathologic conditions, restorative/endodontic needs, treated periodontal disease, and caries remineralization

From the American Dental Association, U.S. Food and Drug Administration: the selection of patients for dental radiograph examinations. Also available at: www.ada.org.

***Factors increasing risk for caries may include, but are not limited to:**

1. High level of caries experience or demineralization
2. History of recurrent caries
3. High titers of cariogenic bacteria
4. Existing restoration(s) of poor quality
5. Poor oral hygiene
6. Inadequate fluoride exposure
7. Prolonged nursing (bottle or breast)
8. Frequent high sucrose content in diet
9. Poor family dental health
10. Developmental or acquired enamel defects
11. Developmental or acquired disability
12. Xerostomia
13. Genetic abnormality of teeth
14. Many multisurface restorations
15. Chemo/radiation therapy
16. Eating disorders
17. Drug/alcohol abuse
18. Irregular dental care

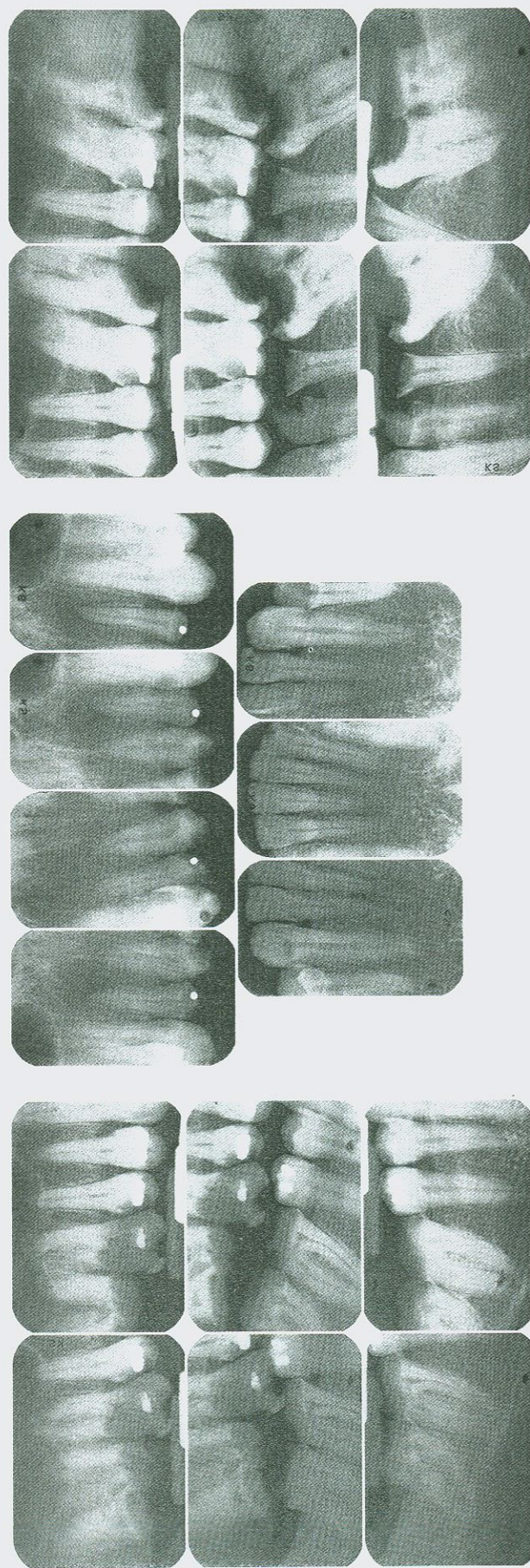


Figure 1-9 A 19-film complete mouth survey (CMS) consisting of 15 periapical and 4 bite-wing radiographs. The patient exhibits radiographic signs of rampant dental caries and a pulpal pathology.

dedicated to maxillofacial imaging are available (Figures 1-12, 1-13). This equipment permits acquisition of 3-D images with a lower radiation dose than with a medical scanner.

Currently, most radiographic exposures in dental practices are recorded on film. As the image quality improves and equipment costs become more reasonable, the move to filmless, digital radiology has gained momentum.

Advantages of digital radiology include decreased radiation exposure for patients, the capability of manipulating images to improve diagnosis, and the elimination of film processing chemicals and equipment. Disadvantages include the cost of devices and equipment, conversion of previous films to digital images, the thickness and rigidity of the sensors, the high cost when a sensor is lost or broken, and difficulty in sharing images among different computer systems.

OTHER DIAGNOSTIC AIDS

Study Casts

Study casts are used to document and analyze the patient's dentition before providing treatment. Individual casts show the position and inclination of teeth and can be used to create matrices for fabricating temporary restorations. Study models should be obtained and mounted on an articulator to evaluate occlusal relationships whenever prosthodontic treatment is being planned. The dentist can also use mounted casts to evaluate the necessity for preprosthetic surgery, especially in the edentulous patient with large maxillary tuberosities. Casts can also serve as visual aids for presenting information to patients.

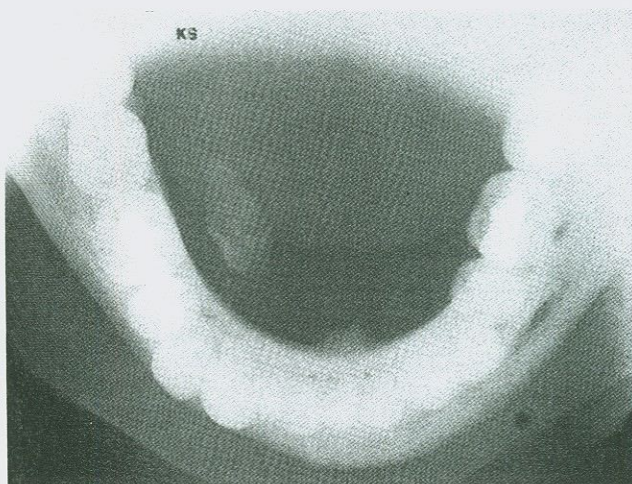


Figure 1-10 A mandibular occlusal radiograph showing a sialolith in the patient's right submandibular gland duct.

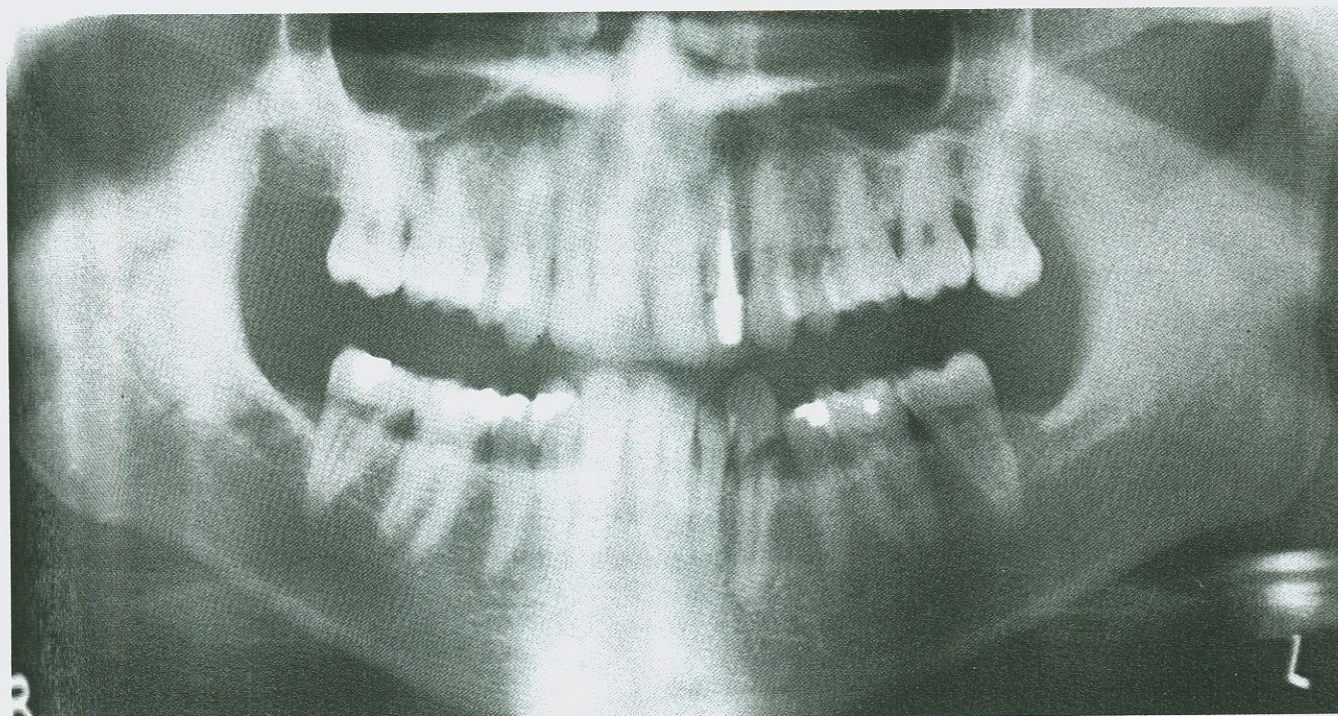


Figure 1-11 A panoramic radiograph of a patient shortly after a fist fight. Note the fractured clinical crown #22 and a fracture at the right angle of the mandible.

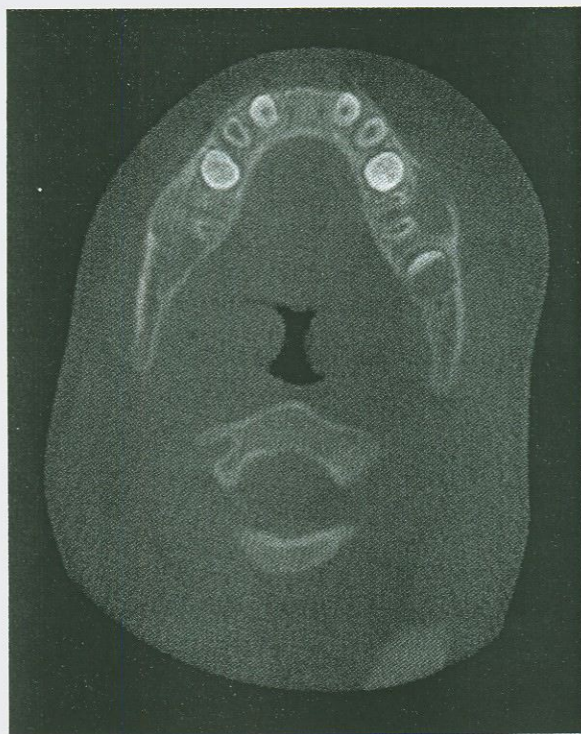


Figure 1-12 Axial view of the mandible of a 7-year-old African-American girl with bilateral expansile tumors of the posterior mandible. The left lesion is larger than the right. (Courtesy Dr. Sharon Brooks.)

Diagnostic Wax-Ups and Altered Casts

Diagnostic wax-ups on study casts help the practitioner and patient better visualize tooth form, contour, and occlusion that will result from the proposed treatment. Wax-ups are especially useful when missing teeth are to be replaced or existing teeth significantly altered. The casts are usually mounted on an articulator to evaluate the waxing in the proposed functional relationship.

Make altered casts on duplicate models of the study cast. Study casts are useful for establishing ideal relationships for jaw segments in the planning of orthognathic surgery or extensive fixed prosthodontic treatment. When the new relationships have been finalized, templates (thermoplastic shims) can be made from the altered casts to serve as guides for tooth preparation or the location of tooth and jaw position during surgery.

Occlusal Splints

When patients have signs of temporomandibular dysfunction (TMD), such as jaw muscle pain or headaches, it may be advisable to construct a passive occlusal splint to relieve symptoms. In such a situation, the occlusal

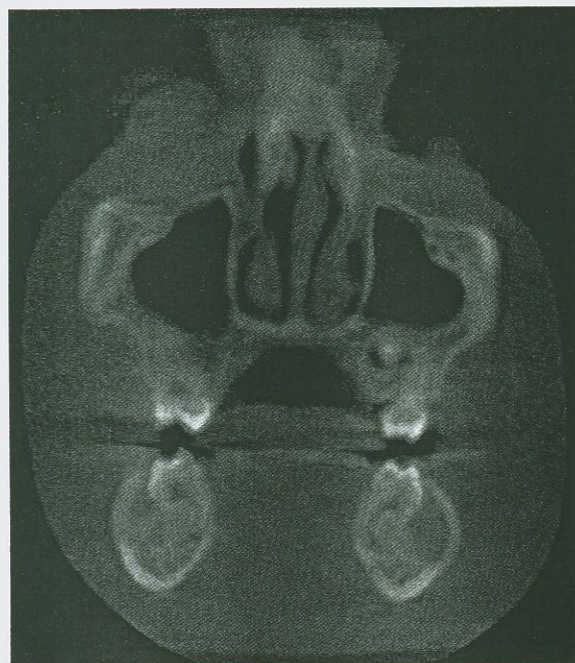

Figure 1-13 Coronal view of the same case showing the tumors buccal to the mandibular first molars. (Courtesy Dr. Sharon Brooks.)

splint becomes both a treatment modality and a diagnostic aid. If the pain persists after splint therapy, the clinician may need to reevaluate the initial working diagnosis of TMD, and search for alternative causes for the pain.

Caries Excavation

Caries excavation, in addition to being an operative procedure, can also serve as a diagnostic technique. For example, it may be necessary to remove caries from a severely decayed tooth, often before endodontic therapy, to determine whether the tooth can be restored. Extensive treatment for a tooth may be useless if it is not restorable, and the tooth should be extracted. The issue of restorability is discussed in greater depth in Chapters 6 and 7.

Consultations

The dentist may question whether it is worth the time and effort to consult with another dentist or a physician about the patient. In general, if the primary care provider has questions concerning the patient's general health, or the diagnosis or treatment of the patient's oral problems, it is in everyone's best interest to seek further guidance. For example, it may be appropriate to

contact the patient's physician to establish the medical diagnoses and to consult about the capacity of the patient to withstand dental treatment. When a consultation is sought, it must be done with the patient's understanding and consent. The consultation, whether obtained by telephone, facsimile, letter, or electronic mail, should include:

- Identifying information about the patient (i.e., complete name, date of birth)
- A summary of significant findings from the general and/or oral health history
- A brief description of the overall treatment plan
- A clear description of the information required from the consultant
- The dentist's name, address, and telephone number

If the information is obtained by telephone, ideally the consultation should be followed up with some form of documentation from the physician that can be retained in the patient's record.

Medical Laboratory Tests

Recent years have seen a steady increase in the number of patients with serious systemic disease who present for oral health care. Many may be taking medications that alter their blood coagulation time or immune system. In other situations, the dentist may suspect that a patient has an untreated systemic problem, such as leukemia or diabetes, that can only be confirmed with laboratory tests. Certain surgical procedures may require laboratory testing before treatment is provided. In this situation, the dentist usually refers the patient to a physician and requests a copy of the test results. Occasionally, some dentists send the patient directly to a laboratory for testing and have the results reported directly to them. Practitioners should be cautious, however, about requesting tests for conditions for which they would be unable to counsel the patient adequately, such as serologic testing for human immunodeficiency virus. The patient should instead be referred to a physician for evaluation.

Biopsy

Biopsy procedures are indicated to diagnose persistent oral lesions or to ensure that a previously diagnosed condition is still benign. The procedure consists of removing all or part of a lesion and submitting the tissue for histologic evaluation. Dentists should not hesitate to biopsy lesions themselves, or to refer the patient for further evaluation and treatment, especially when the lesions are suggestive of oral cancer (see Chapter 11).

Microbiologic and Other Testing Systems

The use of microbiologic tests in dental offices currently is limited, but in the future it will become more widely used, especially as a tool for diagnosing caries and periodontal disease activity.

Caries susceptibility can be evaluated by measuring the quantity of cariogenic bacteria, such as *Streptococcus mutans* and lactobacilli. A sample of the patient's saliva is placed on a special agar medium, which is then incubated. The patient's caries risk is related to the number of bacterial colonies that grow on the plate. A low salivary flow rate (<1 ml/min of stimulated saliva) and low salivary buffering capacity represent risk factors for increased caries activity. The evaluation of substances in a patient's saliva has the potential to serve as a non-invasive test for a number of oral and systemic diseases.

Identifying levels of enzymes and inflammatory mediators in blood serum or gingival crevicular fluid can detect evidence of active periodontal disease. Deoxyribonucleic acid (DNA) probes can also be used to screen for signs of periodontal disease.

A new device that has recently become available uses laser fluorescence to detect signs of demineralization and caries on both pit and fissure and smooth tooth surfaces. The device may be most useful for corroborating other diagnostic findings, directing preventive treatments, and monitoring lesion activity over time.

DEVELOPING DIAGNOSES AND PROBLEM LISTS FOR PATIENTS

Armed with significant findings from the examination process, the dentist now begins to assemble a list of **diagnoses** for the patient. Diagnoses are precise, scientific terms used to describe variations from normal. They can be applied to a systemic disease, such as diabetes, or a specific condition, such as **cracked tooth syndrome**. Other examples of diagnoses include occlusal caries, irreversible pulpitis, squamous cell carcinoma, or Class II malocclusion. Often, more than one finding may be necessary to make a diagnosis. For instance, a tooth that appears darker than the others may not be a significant finding. The same finding concurrent with the appearance on a radiograph of a periapical radiolucency and a tooth that tests negative to electric pulp testing would be strongly suggestive of pulpal necrosis.

The dentist can make several types of diagnoses. When several findings point clearly to a specific disease entity, the clinician may make a **definitive diagnosis**, indicating a high level of certainty. On the other hand, when

the findings suggest several possible conditions, the process of distinguishing among the list of possibilities is referred to as a **differential diagnosis**. For example, a differential diagnosis of a lump on the patient's palate might require differentiation among such possibilities as a maxillary torus, a salivary gland tumor, or an odontogenic infection. Without more information, such as findings from a radiograph or a biopsy result, it may be impossible to reach a definitive diagnosis. Another "golden rule" of treatment planning is that a diagnosis should be made before treatment begins. When the diagnosis is uncertain, but it is prudent to begin some type of treatment, a **working or tentative diagnosis** may be made. The temporary nature of this diagnosis requires reevaluation of the patient at a later time to either confirm the diagnosis or change to a new, now definitive, diagnosis.

On many occasions, a precise diagnosis that matches a significant finding may not be achievable. For example, the patient may reveal that he or she has limited funds available for dental treatment. This is a significant finding that may affect the treatment plan, but it does not fit the classic definition of a diagnosis. Such issues are typically referred to as **problems**. Patient problems can be general or specific issues that suggest the need for attention. Common examples of patient problems include missing teeth, dental pain of undetermined origin, fear of dental treatment, and poor oral hygiene.

Benefits of Creating Diagnosis and Problem Lists

After completing the patient examination, the dentist must gather all the significant findings and create a list of patient diagnoses and problems, which are then documented in the record. The benefits of following this process include:

- **Organization:** Diagnoses and problems can be sorted and organized more readily than findings. The dentist typically lists first the important issues, such as the chief complaint, with other diagnoses following in order of significance. This process of prioritization sets the stage for developing a sequenced treatment plan.
- **Professional competency:** Treatment should not be rendered without first arriving at some type of diagnosis. Documenting diagnoses in the record provides an important safeguard for avoiding the appearance of treating a patient without good reason. In the event of malpractice litigation, dentists who list this information fare better than those who do not. A discussion of standardized codes is featured in the *What's the Evidence?*² box.

What's the Evidence?

SNODENT Diagnostic Codes*

As discussed throughout this chapter, the dentist should always have arrived at a diagnosis, either definitive or tentative, before beginning treatment for a patient. In practice, unfortunately, diagnoses tend to be documented separately from the treatment plan. In fact, most dentists often think primarily in terms of individual procedures when planning treatment for a patient. This process arose naturally when practitioners created line-item treatment plans and estimated costs for each service they would be providing.

In 1969 the American Dental Association introduced dental procedure coding. The codes were designed to convey standardized treatment information to dental insurance companies and to facilitate computerization of billing services.

In contrast to the practice of dentistry, payments to physicians and hospitals for services are often based on the patient's original diagnoses, rather than on the specific procedures provided. To support this concept, *diagnostic codes* were developed to accompany treatment codes when billing third-party payers. This diagnostic coding system is referred to as the Systematic Nomenclature of Medicine, or SNOMED.

The American Dental Association has developed its own set of diagnostic and descriptive terms and codes, referred to as SNODENT. The more than 4000 terms and codes allow dentists to electronically record diagnostic information, including physical findings, risk factors, and functional status. In the future, dentists could add SNODENT codes when submitting insurance claim forms. This information would aid researchers in tracking patient conditions and outcomes and allow dentists to analyze patterns of disease in their own practices by evaluating summary reports of SNODENT diagnostic codes from their computer systems. The coupling of a diagnosis coding with a treatment coding provides a powerful tool for studying what types of care are being provided and for what reasons, which provides data for evidence-based decision making.

*For further discussion of this topic, the reader is referred to McKee L: SNODENT to provide inclusive means of transmitting dental information, ADA News 30(9):May 3, 1999.

- **Patient education:** At the conclusion of the examination, the dentist should inform the patient about his or her oral condition. A list of diagnoses and problems provides a convenient and straightforward way to share this information. Eventually, discussing diagnoses and problems becomes part of the process of obtaining informed consent to provide treatment for the patient.

Common Diagnoses

General Health Diagnoses A wide variety of diagnoses can be made concerning a patient's general health condition. Many of these diagnoses are self-reported by the patient on the health questionnaire. The dentist may have additional concerns after reviewing the medication list, interviewing the patient, and evaluating the vital signs. If any findings contradict the patient's own appraisal of his or her general health, it may be necessary to contact the patient's physician.

All systemic health diagnoses should be clearly written in the patient's record. When possible, qualifiers should be added to indicate the type of problem and level of disease control.

For example:

- Functional or organic heart murmur
- Stable or unstable angina
- Treated or untreated hypertension
- Controlled or uncontrolled diabetes
- Insulin dependent or noninsulin dependent diabetes

The dentist should use alert labels on the patient record to flag important health problems, such as allergies, sensitivities to drugs, or the necessity for antibiotic premedication.

The reader will find further discussion of the significance to treatment planning of many medical diagnoses in Chapters 5, 10, and 16.

Psychosocial Diagnoses Psychosocial diagnoses cover a wide array of problems that can affect the successful outcome of dental treatment. For instance, the patient who smokes two packs of cigarettes a day significantly increases the risk for periodontal disease, regardless of the quality of periodontal treatment provided. Problems such as dental anxiety, poor oral hygiene, a high sucrose diet, financial limitations, episodic dental treatment, and substance abuse commonly are not written into dental records. This is unfortunate because these diagnoses and problems should be considered when creating a treatment plan, and when listed in the record can document conditions beyond the dentist's control that may affect treatment outcomes.

Intraoral/Extraoral Diagnoses A vast variety of lesions may occur in the head and neck area, and the dentist must carefully examine all areas of skin and mucosa for abnormalities. Lesions on the surface of the skin or mucosa may be temporary in nature and heal quickly. Others may be long-standing and require a biopsy and histologic evaluation to arrive at a definitive diagnosis. Lesions below the surface, usually detected by **palpation**, can be problematic in terms of diagnosis. A classic example

is a firm mass in the head and neck region that may be just a fibrotic or inflammatory lymph node, or something more serious, such as a cancerous tumor. Whether a lesion is deep or involves the surface epithelium, the clinician must document all variations from normal at the initial examination and ensure that a system is in place to recall the patient for reevaluation at a specified time interval. In some cases, referral to another health professional who can make a definitive diagnosis may be necessary.

Periodontal Diagnoses Significant findings from the periodontal examination may suggest a diagnosis relating to periodontal disease, most commonly, plaque-associated gingivitis. Approximately 15% of patients will also have attachment loss or a diagnosis of periodontitis. A periodontal disease classification system developed by the American Academy of Periodontology is presented in Box 1-3. Although technically not a periodontal diagnosis, many dentists also note the patient's level of plaque control and calculus accumulation.

Dental Diagnoses Problems affecting the teeth have traditionally occupied much of the dentist's attention during the evaluation process. In the past, dentists have had an almost singular focus on caries detection. More recently, other problems such as patient esthetic concerns have taken on an increased level of significance. The large number of possible dental diagnoses can be sorted into three categories: (1) alteration in tooth structure and morphology, (2) problems with tooth function, and (3) problems affecting tooth appearance. Some of the more common diagnoses follow.

Dental caries represents the most common disease affecting the structure of teeth. Relatively easy to recognize in its overt form, the dentist will be able to provide a precise diagnosis of noncavitated (white or spot decalcification) and the varied opacities or pigmented areas of the teeth that may accompany alternating stages of demineralization and remineralization (Figure 1-14). Is the caries active, suggesting a need for preventive or restorative treatment, or inactive, suggesting a "wait and see" approach? Dental decay can begin and then stop, leaving darkly stained pits and fissures in a process referred to as **arrested caries**.

Recurrent caries occur at the restoration-tooth interface or underneath an existing restoration. The dentist should identify each affected tooth and note a clear description of the type and location of carious lesions. It is also helpful to include the diagnosis of teeth and surfaces thought to be at risk for future caries (i.e., any teeth that will need reevaluation).

Tooth morphology can be affected by several other conditions. The dentist may find that the shape or

BOX 1-3 Periodontal Disease Classification

- I. Gingival Diseases
 - A. Dental plaque-induced gingival diseases
 1. Gingivitis associated with dental plaque only
 2. Gingival diseases modified by systemic factors
 3. Gingival diseases modified by medications
 4. Gingival diseases modified by malnutrition
 - B. Non-plaque-induced gingival lesions
 1. Gingival diseases of specific bacterial origin
 2. Gingival diseases of viral origin
 3. Gingival diseases of fungal origin
 4. Gingival lesions of genetic origin
 5. Gingival manifestations of systemic conditions
 6. Traumatic lesions (factitious, iatrogenic, accidental)
 7. Foreign body reactions
 8. Not otherwise specified (NOS)
- II. Chronic Periodontitis
 - A. Localized
 - B. Generalized
- III. Aggressive Periodontitis
 - A. Localized
 - B. Generalized
- IV. Periodontitis as a Manifestation of a Systemic Disease
 - A. Associated with hematologic disorders
 - B. Associated with genetic disorders
 - C. Not otherwise specified (NOS)
- V. Necrotizing Periodontal Diseases
 - A. Necrotizing ulcerative gingivitis (NUG)
 - B. Necrotizing ulcerative periodontitis (NUP)
- VI. Abscesses of the Periodontium
 - A. Gingival abscess
 - B. Periodontal abscess
 - C. Pericoronal abscess
- VII. Periodontitis Associated With Endodontic Lesions
 - A. Combined periodontic-endodontic lesions
- VIII. Developmental or Acquired Deformities and Conditions
 - A. Localized tooth-related factors that modify or predispose to plaque-induced gingival diseases and/or periodontitis
 - B. Mucogingival deformities and conditions around teeth
 - C. Mucogingival deformities and conditions on edentulous ridges
 - D. Occlusal trauma

Adapted from Armitage GC: Development of a classification system for periodontal diseases and conditions, *Ann Periodontol* 4(1):1-6, 1999.

integrity of a restoration is a problem. Common reasons for a diagnosis of faulty or failing restorations include cracks and fractures; open margins with known, suspected, or anticipated recurrent caries; voids in material; loose restorations; or restorations with poor contours

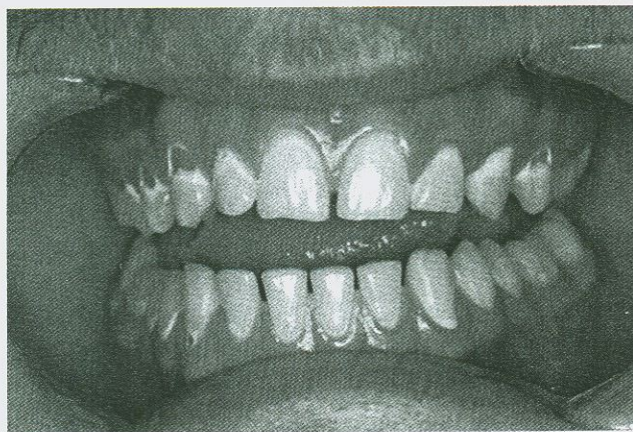


Figure 1-14 White areas of demineralization in the anterior teeth have progressed to carious lesions in the maxillary posterior areas. The patient had a diet high in refined carbohydrates, primarily from carbonated beverages.

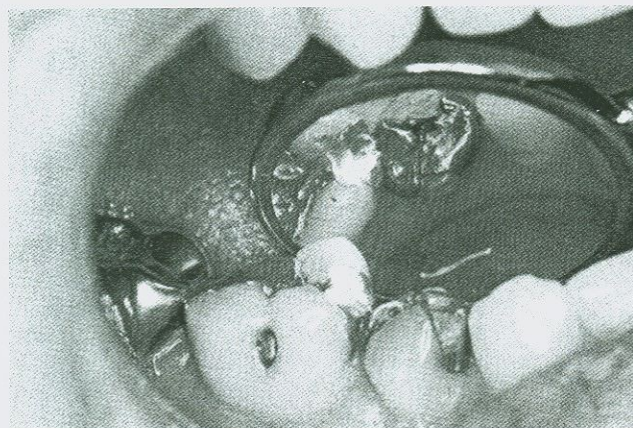


Figure 1-15 A premolar (see mirror view) with a fractured restoration and recurrent caries.

(Figure 1-15). Two common contour problems are restoration **overhangs** (Figure 1-16) and undercontoured restorations, which may result in an open proximal contact with adjacent teeth. Either condition, when left untreated, can be detrimental to the periodontium.

The practitioner may discover a number of diagnoses related to the loss of tooth structure. Teeth can fracture, creating problems relating to both function and appearance. Another common condition is the frictional wearing of teeth over time, referred to as **attrition**. This wear pattern may be most evident in the anterior region or throughout the entire dentition, becoming evident as a loss of cuspal inclines and the presence of many wear facets. Some patients may exhibit signs of severe attrition because of grinding the teeth, often at night—a condition referred to as **bruxism** (Figure 1-17). Wearing away or notching of the teeth by a mechanical means, such as with a toothbrush, is referred to as tooth **abrasion**. Chemical loss of tooth structure is called **erosion** or **corrosion**, and may be seen in patients with a high acid diet, gastric acid reflux disease, or bulimia (Figure 1-18).

Abfractions are wedge-shaped lesions occurring in the cervical enamel. The lesion may be a result of occlusal loading and flexure in this area.

Another category of functional problems relates to tooth position. When a tooth protrudes out of the

occlusal plane, usually because no antagonist exists or the tooth has significant attachment loss, it is **hypererupted**. Teeth also tip into edentulous spaces or become crowded together. When the maxillary facial cusps occlude into the mandibular central grooves, the group of teeth are in **cross-bite**. During the dental examination, the clinician should also record other, more global diagnoses, such as Angle's classification of occlusion and measurements of anterior overbite and overjet (Figure 1-19).

Patients have appearance or **esthetic** complaints relating to several dental diagnoses. A common problem is discolored teeth. Patients who use tobacco products or consume large quantities of coffee or tea may exhibit **extrinsic staining**. This stain is on the tooth surface and can be removed with polishing agents or reduced with certain types of toothpaste. In contrast, **intrinsic staining** is inside the tooth, within the dentin. This staining can be physiologic, commonly seen as a yellowing of teeth over time. Discolored anterior resin restorations are another common example of intrinsic staining. Physical trauma to

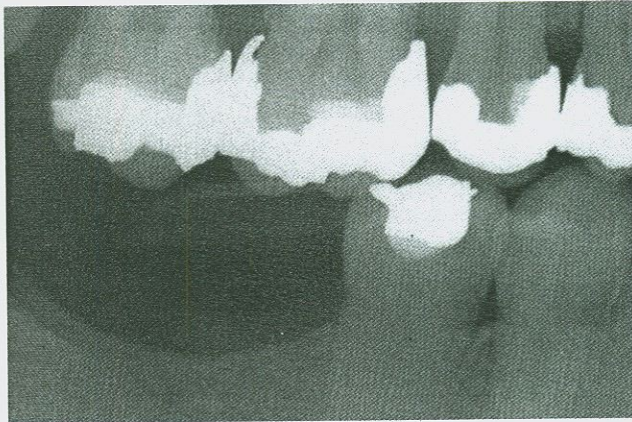


Figure 1-16 A molar and premolar with amalgam overhangs.

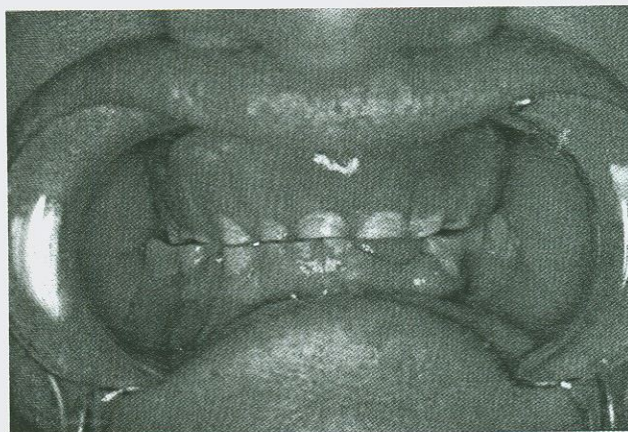


Figure 1-17 Both the maxillary denture and mandibular teeth show signs of excessive attrition from bruxism in this patient who ground his teeth at night.

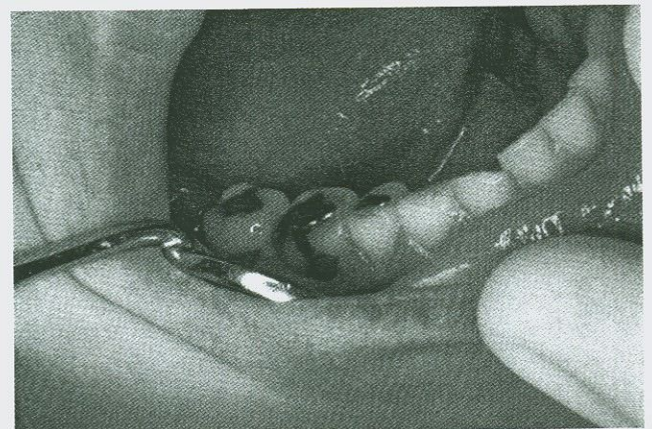

Figure 1-18 Erosion of the posterior teeth in a patient with bulimia. The restorations appear to protrude from the occlusal surface because of the loss of tooth structure.

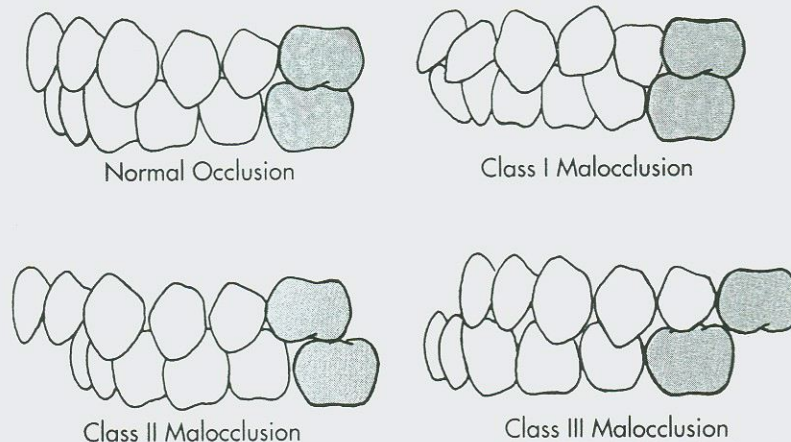


Figure 1-19 Normal occlusion and malocclusion classes as specified by Angle. This classification was quickly and widely adopted early in the twentieth century. It is incorporated within all contemporary descriptive and classification schemes. (From Proffit WR, Fields HW Jr: Contemporary orthodontics, ed 3, St Louis, 2000, Mosby.)

a tooth or teeth may eventually lead to the death of the dental nerve, resulting in isolated dark or gray teeth (Figure 1-20). Many congenital and developmental conditions can cause problems with tooth color. Esthetic complaints can also arise for several other reasons, including abnormal tooth shape or position, and the quality of prior restorations. A common esthetic complaint is a noticeable space between two teeth, referred to as a **diastema**.

Pulpal and Periapical Diagnoses The dentist bases the diagnosis and classification of pulpal disease on patient symptoms and clinical findings. Pain of dental origin may reflect conditions that are reversible or irreversible in nature. A **reversible pulpitis** is a temporary condition characterized by pain that is usually not severe; is associated with a specific stimulus, such as hot or cold; and ceases within a short period after removal of the stimulus. A constant, severe pain that seems to have arisen spontaneously without provocation characterizes irreversible pulpitis, the classic diagnosis for a toothache. A diagnosis of **pulpal necrosis** can be made when pulp testing is negative and signs of periapical pathologic conditions or changes in tooth color are present.

When the pulpal inflammation extends to the periradicular tissue, typically seen with pain on occlusal contact or mastication, it is referred to as an **acute apical periodontitis**. An **acute apical abscess** is an extension of the inflammatory reaction beyond the root apex. The patient may have signs of swelling, elevated temperature, lymphadenopathy, and/or malaise.

Radiographic findings associated with the dental pulp and surrounding tissue may suggest several diagnoses. The dentist may interpret a missing pulp space as evidence of **calcified canals**. An irregularly enlarged root canal space suggests **internal resorption**. Resorption of the root from the outside, around the periodontal liga-

ment space, is **external resorption**. Common periapical diagnoses seen on radiographs include **chronic apical periodontitis** (Figure 1-21) and **focal sclerosing osteitis**. Root fractures, secondary to trauma, can often be seen on radiographs.

DOCUMENTATION

All examination results and diagnoses must be clearly documented in the patient record. The **progress notes**, or **chronologic record of treatment (CRT)**, document each appointment. These notes can include appointment-specific diagnoses, evidence of health history review, details of treatment provided, patient behavior, and plans for the next visit (Box 1-4). Treatment detail should include the teeth or soft tissue area treated, medications administered, and the details surrounding the treatment procedures.

Records, including radiographs, must be maintained in good condition and be retrievable even after the patient has left the dental practice. Good record keeping, complete examination documentation, and the ability to retrieve the record represent essential elements in dental practice. In the event of litigation, good documentation can protect the dentist by demonstrating a high level of professional competence. Good records help prevent litigation, win a mal-

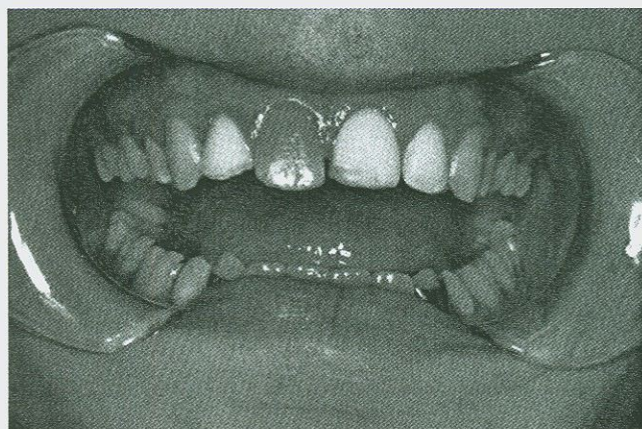


Figure 1-20 An example of intrinsic staining of a tooth resulting from pulpal necrosis. The patient had been in a car accident approximately 2 years earlier and had struck her tooth on the steering wheel.

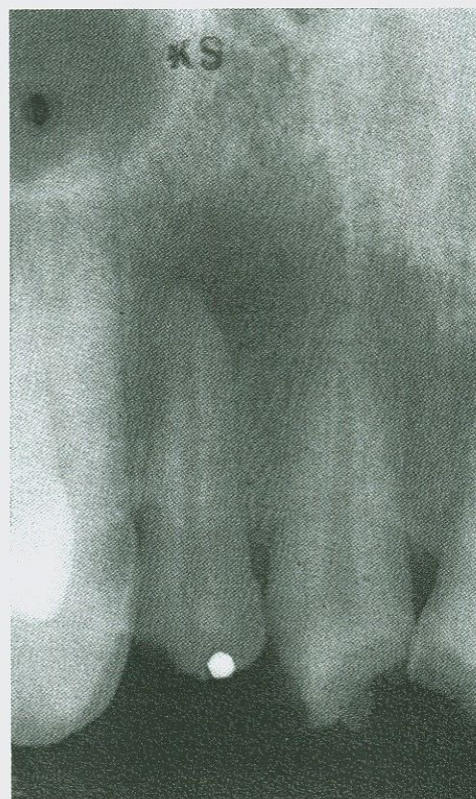

Figure 1-21 This periapical radiolucency on tooth #7 suggests a chronic apical periodontitis.

practice suit, or decrease damages. Patients who change practitioners have a legal right to obtain copies of recent radiographs. An additional important reason for maintaining complete diagnostic and treatment-related information for each patient is that the dentist may have the unpleasant duty of providing dental records, postmortem, for the purpose of patient identification.

Several worksheets and dental charts are available for recording findings, diagnoses, and treatment recommen-

dations. The choice of forms is a personal decision. Ideally, entries should be in pen for permanence and in black ink to facilitate photocopying. Some computerized information systems have the capability to chart existing restorations, caries, and periodontal findings.

The retention of study models for all patients presents storage problems. No specific guidelines exist, but many dentists retain casts for patients who have had orthodontic treatment or extensive prosthodontic work.

Color photographs and digital images of patients are excellent methods for recording patient findings, both before and after treatment. Some practitioners, especially orthodontists, routinely take photographs of all their patients. Intraoral video cameras are used to educate patients about problems in their mouths. Many systems can instantaneously print still images that can be given to the patient or placed in the record.

The union of digital photographs and digital radiography with electronic charting and procedural notes has led to the creation of an electronic patient record (Figure 1-22). It remains to be seen whether this influx of technology will address the insufficiencies

BOX 1-4 Example of a Chronologic Record of Treatment (Progress Note) Entry

Problem: caries distal #3.

Health status: treated hypertension, BP 125/85.

Treatment: 1.8 cc 2% lidocaine 1:100,000 epinephrine infiltration, rubber dam isolation. DO amalgam placed over glass ionomer liner and cavity varnish.

Patient evaluation: patient was apprehensive but cooperative.

Next visit: composite restorations #7, 8, and 9. Check bite splint.

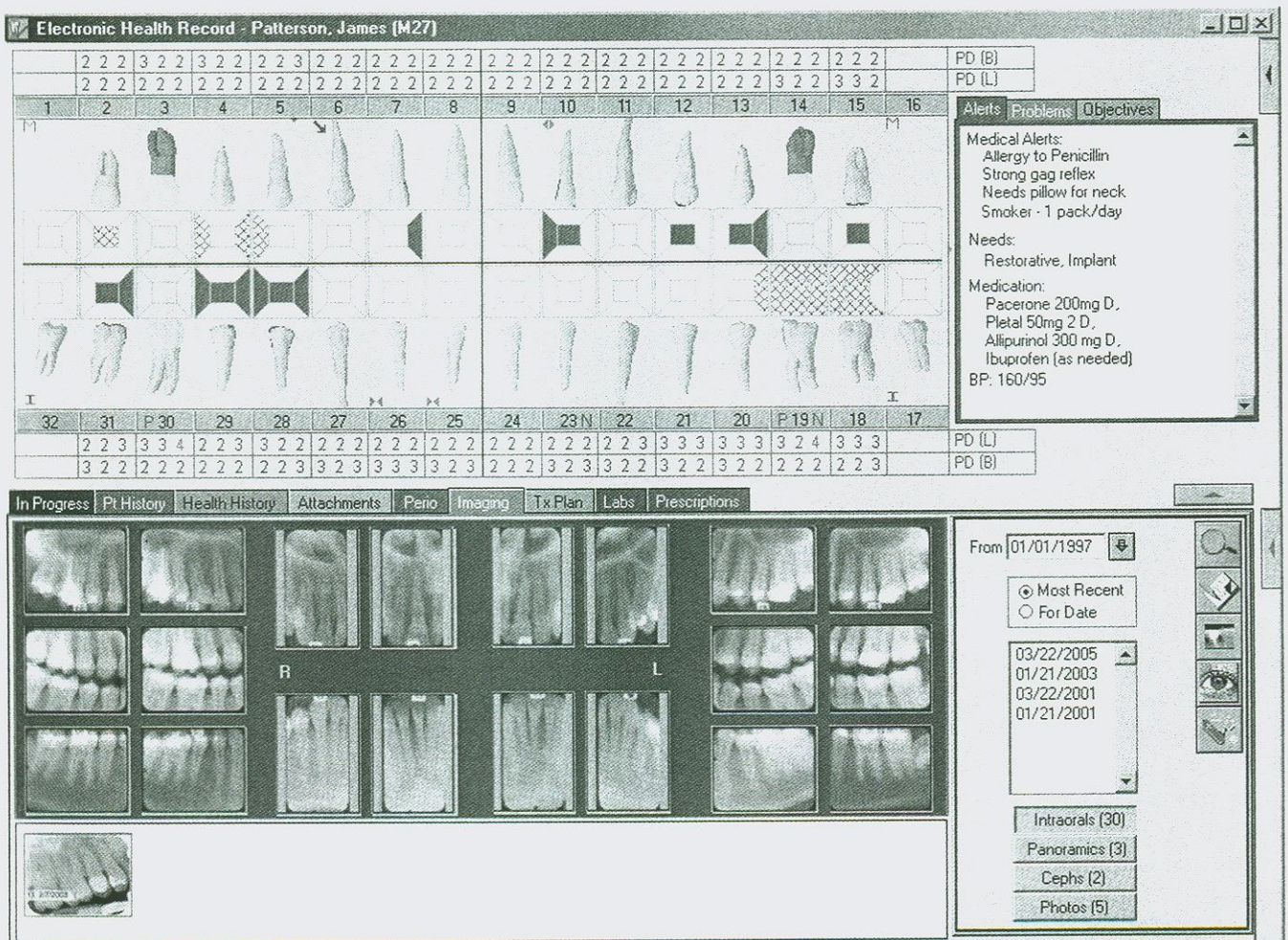


Figure 1-22 Sample screen from an electronic patient record. (Courtesy Exan Corp.)

in documentation historically found in many dental practices.

REVIEW QUESTIONS

- What are the major categories of information required to begin to create a treatment plan?
- Describe techniques that can be used and techniques to be avoided when interviewing a dental patient.
- What are the components of a patient history? What information is included in each of those components?
- List indications for obtaining study casts as part of the initial examination of the patient.
- When the dentist requests a consultation with a physician or other health care provider, what information is the dentist seeking and how will it be recorded in the patient record?
- What is the difference between a working or tentative diagnosis, a differential diagnosis, and a definitive diagnosis? How is each used?
- What are the benefits of creating a diagnosis or problem list for each patient?

SUGGESTED READINGS

- American Academy of Periodontology: Parameters of care, *J Periodontol* 71(suppl 5):847-883, 2000.
- American Association of Endodontists: Appropriateness of care and quality assurance guidelines, Chicago, 1998, American Association of Endodontists.
- Association Dental Association and US Food and Drug Administration: The selection of patients for dental radiographic examinations, Chicago, 2005 American Dental Association.
- Christensen GJ: Why switch to digital radiography? *J Am Dent Assoc* 135(10):1437-1439, 2004.

- DerMarderosian A: The review of natural products, St Louis, 2002, Facts and Comparisons.
- Drug facts and comparisons, St Louis, 2004, Facts and Comparisons.
- Gage T, Pickett F: Mosby's dental drug reference, ed 7, St Louis, 2004, Mosby.
- Grippio JO, Simring M, Schreiner S: Attrition, abrasion, corrosion and abfraction revisited: a new perspective on tooth surface lesions, *J Am Dent Assoc* 135(8):1109-1118, 2004.
- Ingle J, Bakland L: Endodontics, ed 5, Hamilton, ON, 2002, Decker.
- McLellan TS: Understanding HIPAA: the Health Insurance Portability and Accountability Act, *J Mich Dent Assoc* 84(3):38-42, 2002.
- Newland JR: Oral hard tissue diseases, Hudson, Ohio, 2003, Lexi-Comp.
- Newland JR: Oral soft tissue diseases, Hudson, Ohio, 2005, Lexi-Comp.
- Physician's desk reference, ed 58, Montvale, NJ, 2004, Medical Economics Company, Inc.
- Pitts N: "ICDAS"—an international system for caries detection and assessment being, *Community Dent Health* 21(3):193-198, 2004.
- Shillingburg H and others: Fundamentals of fixed prosthodontics, ed 3, Chicago, 1997, Quintessence.
- Shulman JD, Beach MM, Rivera-Hidalgo F: The prevalence of oral mucosal lesions in U.S. adults: data from the Third National Health and Nutrition Examination survey, 1988-1994, *J Am Dent Assoc* 135(9):1279-1286, 2004.
- Sturdevant C: The art and science of operative dentistry, ed 4, St Louis, 2002, Mosby.
- Tierney L, McPhee S, Papadakis M: Current medical diagnosis and treatment, ed 44, Stamford, Conn, 2005, Appleton & Lange.
- Walton R, Torabinejad M: Principles and practice of endodontics, ed 3, Philadelphia, 2002, WB Saunders.
- White S, Pharoah M: Oral radiology: principles and interpretation, ed 5, St Louis, 2004, Mosby.
- Wynn R, Meiller T, Crossley H: Drug information handbook for dentistry, ed 10, Cleveland, 2005, Lexi-Comp.